



## Effect of *Aju Mbaise* on Sperm Morphology, Semen Quality, Sex Hormonal Levels, Gonadosomatic Index, and Testicular Histology of Avodart-Induced Rats

Robert Ikechukwu Uroko<sup>1</sup>, Chinomso Friday Aaron<sup>2</sup>, Mercylyn Ezinne Uche<sup>2</sup>, Chinedu Aguwamba<sup>3</sup>, Elisha Uko Ogwo<sup>4</sup>, Paul Chukwuemaka Nweje-Anyalowu<sup>3</sup>, Solomon Nnah Ijioma<sup>5</sup>

<sup>1</sup>Department of Biochemistry, College of Natural Sciences, Michael Okpara University of Agriculture, Umudike, Abia State, Nigeria. E-mail: ir.uroko@mouau.edu.ng

<sup>2</sup>Department of Biochemistry, Faculty of Biological and Physical Sciences, Abia State University, Uturu, Nigeria. E-mail: chinomsoaaron@gmail.com; mercyllynuche@gmail.com

<sup>3</sup>Biochemistry Unit, Department of Chemical Sciences, Faculty of Sciences, Clifford University, Owerinta, Abia State, Nigeria. E-mail: aguwambac@clifforduni.edu.ng; lukaspod@yahoo.com

<sup>4</sup>Department of Human Physiology, College of Medicine and Health Sciences, Abia State University, Uturu, Nigeria. E-mail: dr.elishaogwo@yahoo.com

<sup>5</sup>Department of Zoology and Environmental Biology, College of Natural and Applied Sciences, Michael Okpara University of Agriculture, Umudike, Nigeria. E-mail: ijioma.solomon@mouau.edu.ng

Corresponding Author, Department of Biochemistry, College of Natural Sciences, Michael Okpara University of Agriculture, Umudike, Abia State, Nigeria. E-mail: ir.uroko@mouau.edu.ng

### Article Info

#### Article type:

Research Article

#### Article History:

Received: 14 July 2022

Received in revised form: 16 June 2022

Accepted: 23 June 2022

Published online: 04 July 2022

#### Keywords:

*Aju Mbaise*, Male fertility, Sperm quality, Testicular histology, Gonadosomatic index, Sex hormones,

### Abstract

**Objective:** This study evaluated the effect of ethanol extract of *Aju Mbaise* (EEAM) on sperm morphology, semen quality, sex hormonal levels, gonadosomatic index, and testicular histology of Avodart-induced rats.

**Material and Methods:** The study had normal control, Avodart control, EEAM control, Avodart+500mg/kg EEAM, and Avodart +1000mg/kg EEAM groups. The rats were orally administered 0.5 mg/kg Avodart and 1 hour later treated with EEAM for 28 consecutive days. The Avodart control had milky white semen with low Ph, volume and semen consistency compared to the normal control and EEAM treated rats with creamy white semen with higher pH and semen consistency, respectively.

**Results:** The results indicated a substantial decline in spermatozoa mass motility; spermatozoa live proportion, spermatozoa concentrations, normal spermatozoa proportions, animal live weight, paired testes weight, and relative testicular weight in the Avodart control compared to the normal control. The Avodart induction caused a significant reduction in the serum testosterone, follicle-stimulating hormone and luteinising hormone levels compared to the normal control. Also, there was a substantial decline in spermatogenic activity and the absence of mature spermatocytes in the lumen of the seminiferous tubules in the Avodart control relative to the normal control and EEAM control. The alterations in the sperm morphology, semen quality, sex hormonal levels and gonadosomatic index were significantly reverted to normal in the EEAM treated Avodart induced rats in a dose-dependent manner compared to the Avodart control.



**Conclusion:** These findings showed that EEAM ameliorates Avodart toxicity and improves fertility by restoring sperm quality and sex hormonal levels to normal in rats.

## Introduction

Male infertility among the population within the reproductive age is a global challenge, with males having infertility or low fertility incidence accounting for about 40-50% of the yearly reported cases of infertility. Most of them cannot afford assisted fertilisation due to its high cost and sometimes lack of the required facilities [1]. Male infertility is partly attributed to a decline in the circulating serum testosterone levels and reduction in the luteinising hormone (LH) that primarily stimulates Leydig cells to produce sufficient testosterone, which mediates spermatogenesis in the testes to enhance male fertility [2, 3]. Although microscopic and macroscopic semen characteristics are commonly evaluated to ascertain male fertility status, sperm concentration, sperm motility, sperm morphology, and sperm viability are the most reliable spermatozoa indices for predicting male fertility status [4]. A literature survey showed that several researchers have shown that many drugs, including antibiotics, antimalaria, anti-benign prostatic hyperplasia, and antiandrogenic drugs, could adversely affect male fertility via disruption of exocrine functions of the testes and impairing spermatogenesis [5].

Avodart is a 5 $\alpha$ -reductase enzyme inhibitor that many reports from different studies have implicated in causing sexual dysfunction, including structural degeneration in the penis, which could be irreversible [6, 7]. It has been shown to impair male fertility by causing a substantial decline in the semen volume, semen colour, total sperm count, sperm motility, decrease in epididymis weight, epididymal sperm counts, prostate and seminal secretory activities [7]. The effects of dutasteride on female fertility indicated that it causes a decrease in litter size, feminisation of male foetuses, elevated embryo resorption, and reduced foetal body weights. Treatment with dutasteride causes the penis to develop fibrosis and alters the rate of expression of androgen receptors, and decreases hormonal levels, including follicle-stimulating hormone (FSH), testosterone and luteinising hormone (LH) that play critical roles in male fertility and reproductive health [8]. Male reproductive health and fertility are essential to sustain human existence on earth. The need

for a healthy reproductive life has necessitated a concerted effort to reduce the rate of increasing male and female infertility globally. Although assisted fertilisation, like in vitro fertilisation, could help to circumvent infertility or child bareness, not everybody could afford it due to limited facilities, religious beliefs and reported cases of false parenting attributed to the malpractices by the facilitators. Thus, searching for safe, readily available, and cost-effective potent anti-infertility agents remains a viable option for improving male sexual health and parenting.

communities in southeast Nigeria and widely used by nursing mothers across various regions in Nigeria for easing efflux of dirt blood, placental residues, and boosting immunity and lactation after birth. Many anaemic patients consume Aju Mbaise extract to replenish their blood count and other haematological parameters, especially those whose religious beliefs are against blood transfusion, with most recovering from anaemic conditions. It has been reported to be therapeutically effective against obesity, diabetes mellitus, ovarian cyst, altered menstrual cycle, and eczema due to its medicinal plant composition [9, 10, 11]. Aju Mbaise contains substantial amounts of minerals, proteins, minerals and vitamins that contribute immensely to its therapeutic activities, including broad-spectrum antimicrobial activities and antihyperglycaemic [12, 13]. The pharmacological activities exhibited by Aju Mbaise are due to the synergistic actions of the phytochemicals contained in the medicinal plants, including *Ceiba petandra*, *Spondias mombine*, *vogelli*, *Euphorbia*, *Uvaria chamae*, *Napoleona convolvuloids* and *Barteria fistulosa* that make up the Aju Mbaise [14, 15]. It also has antimalarial, antitumor, antimicrobial, anti-inflammatory and antipyretic activities. At the same time, many women preparing for conception consume it to induce ovulation and sanitise their wombs for the avoidance of preventable complications in pregnancy [15]. Having surveyed the medicinal and therapeutic potentials of Aju Mbaise, this study was designed to evaluate the effects of ethanol extract of Aju Mbaise (EEAM) on sperm morphology, semen quality, sex hormonal levels,

gonadosomatic index and testicular histology of Avodart-induced rats.

### Materials and Methods

#### Chemicals and reagents

The chemicals and reagents employed in this study were of analytical standard from reputable chemical manufacturers. The Avodart (drug) was sourced from GSK (GlaxoSmithKline) companies in the United Kingdom, while the absolute ethanol and chloroform were purchased from Sigma-Aldrich, United States. The chemiluminescence immunoassay kits for testosterone, follicle-stimulating hormone (FSH), and luteinising hormone (LH) were purchased from Autobio Diagnostics Co., Ltd. Zhengzhou, China.

#### Animals

Male Wistar albino rats numbering thirty were obtained from the Abia State University, Umuahia Campus animal house and acclimatised for three weeks at the animal house at our college. The rats were treated with dignity according to the ethical guidelines for using animals for experiments.

#### Preparation of *Aju Mbaise* extract

Freshly prepared *Aju Mbaise* coils used in this study were obtained from Mbaise market, Imo State, Nigeria, sliced into smaller pieces and dried until a constant dry weight was attained. The dried *Aju Mbaise* sample was ground into a coarse powder, and 1000 g of it was extracted with 3.2 litres of absolute ethanol for 72 hours with intermittent shaking. It was filtered with a Whatman No. 1 filter paper, and the filtrate obtained was concentrated with a rotary evaporator; the weight of the concentrated extract was weighed, and the percentage yield was calculated. The percentage yield was obtained as 12.83 %, equivalent to 128 g.

#### Experimental design

The thirty Wistar albino rats were randomly distributed into five groups containing an equal number of rats ( $n = 6$ ). The five groups were defined as follows:

Group 1 Normal control (received only 2 ml/kg distilled water and Tween 80 (3:1 v/v)

Group 2 Avodart control (received 0.5 mg/kg Avodart without any treatment)

Group 3 EEAM control (received 1000 mg/kg EEAM only)

Group 4 Avodart+500mg/kg EEAM (received 0.5 mg/kg Avodart and treated with 500 mg/kg EEAM)

Group 5 Avodart+1000mg/kg EEAM (received 0.5 mg/kg Avodart and treated with 1000 mg/kg EEAM)

The rats received 0.5 mg/kg Avodart/day via oral route for 28 consecutive days. Treatment with EEAM via oral route also took place 1 hour after the daily administration of Avodart for the 28 straight days of the study. Rats were subjected to fasting overnight before being sacrificed on the 29th day. The rats were anaesthetised with chloroform inhalation, blood samples for hormonal analyses were collected via cardiac puncture, epididymis was harvested for semen collection for investigations, and the testes were harvested for histopathological examination. The live animal weight and weights of the paired testes were taken, and relative testicular weight was calculated.

#### Collection of semen samples

The semen, including the sperm cells, was obtained from the epididymal pool. The rats were anaesthetised by chloroform inhalation, and we extracted their epididymis. A slide for examination of the semen and sperm quality was prepared by incising the caudal region of each epididymis and making a smear of the semen on the preheated sterile glass slides.

#### Determination semen pH

The semen pH was determined with a specialised calibrated blot paper which gives colour change corresponding to the pH of the medium it is subjected to, using the method of Dhuma et al. [16].

#### Examination of semen colour and consistency (viscosity)

The semen colour and consistency were examined macroscopically. A scale of 1-2 was used for the colour, with milky white semen assigned one (1) and creamy white semen given two (2). The semen consistency was a score of 1-4, with 1, 2, 3, and 4 representing watery semen, slightly water, thick and very thick semen, respectively.

### Abnormal sperm proportion (sperm morphology)

The abnormal sperm proportions, including total head, twisted tail, bent mid-piece, total cytoplasmic droplets, total abnormal sperm cells, and mid-piece abnormalities, were determined according to El- Sherbiny [17].

### Spermatozoa mass motility (progressive motile sperm cells)

The spermatozoa mass motility (progressive motile sperm cells) was examined according to the procedure outlined by El- Sherbiny [17]. A drop of freshly collected semen samples was smeared on preheated sterile glass slides and observed under a light microscope at a magnification of x10 and x40 and subjectively scored in percentage.

### Spermatozoa live proportion (sperm cell viability)

This study determined the levels of phytochemicals and heavy metals in the extracts of *F. exasperata* leaves obtained

### Determination of serum sex hormonal levels

The serum sex hormonal levels, including testosterone, follicle-stimulating hormone (FSH), and luteinising hormone (LH), were determined using Chemiluminescence Immunoassay methods as outlined in the AutoBio Diagnostics kits for each of the parameters respectively.

### Histological examination

The testes samples collected for histopathological examination were fixed in 10% phosphate-buffered formalin for at least 48 hours, followed by trimming and dehydration in graded alcohol of increasing concentrations. Each fixed testis was rinsed in graded xylene and embedded in molten wax. Upon solidification, they were sliced into 5µm using a microtome and placed in a water bath at 60°C for 30 minutes. The sliced tissues were xylene and rehydrated in alcohol of increasing strength. They were stained with Haematoxylin dye for 15 minutes, and blueing was subsequently carried out with ammonium chloride. Counterstaining of the sliced tissues was done after differentiation with a low

in Birnin Kebbi, Nigeria, and also determined their toxicity using a modified brine shrimp lethality assay. *F. exasperata* is commonly used in traditional medicine in Nigeria, but there is a dearth of documented information about its toxicity. This study, therefore, aimed to determine the safe doses of the plant in order to prevent unintended fatalities among its users.

### Sperm concentration

A haemocytometer was used to determine the sperm cell concentrations in the semen according to the method described by Herbert [18]. Briefly, a dilution of 1: 200 was made using a red blood cell pipette and the semen was diluted with 10% buffered formalin solution to immobilise the sperm cells. A drop of the sperm cell solution was used to charge the haemocytometer and allowed 2 minutes on a wet paper to enable sperm cells to settle. It was then mounted on a light microscopic and observed under × 40 magnification. The spermatozoa concentration (ml) was calculated from the number of sperm cells counted x dilution factor x 0.04 X10<sup>6</sup>

concentration of alcohol, and permanent mounts were done on degreased glass slides with a mountant. The slides were viewed via a Motic™ compound light microscope. The photomicrographs of the tissue sections from the testes were obtained at random with a microscope camera at a magnification of x160.

### Statistical analysis

Our data were subjected to a one-way analysis of variance (ANOVA) and Duncan multiple range comparison test with Statistical Products and Service Solutions (SPSS) version 22. The statistical significance of our analysed data was obtained at  $P < 0.05$ . The results were presented as mean ± standard deviation ( $n = 6$ ), with results with unlike superscripts being significantly different from the corresponding paired mean.

### Results

The results in Table 1 indicated a significant rise in the total head abnormality in the sperm cells in Avodart control



and Avodart induced rats treated with 500 mg/kg EEAM compared with the normal control. However, the EEAM control and Avodart-induced rats treated with 1000 mg/kg EEAM showed no significant rise in the total head abnormality of the sperm cells relative to the normal control. Conversely, the EEAM control and Avodart-induced rats treated with 500 and 1000 mg/kg EEAM had significantly reduced total head abnormality in the sperm cells compared with Avodart control.

The Avodart control and Avodart-induced rats treated with 500 mg/kg EEAM had significantly elevated levels of sperm cells with bent mid-piece abnormality compared with the normal control (Table 1). There was no significant increase in the amounts of sperm cells with bent mid-piece abnormality in the EEAM control and Avodart-induced rats treated with 1000 mg/kg EEAM relative to the normal control. Conversely, the EEAM control and Avodart-induced rats treated with 500 and 1000 mg/kg EEAM, respectively, show a significant decline in the levels of sperm cells with bent mid-piece abnormality compared with the Avodart control.

The percentage of sperm cells with twisted tails in Table 1 showed significant elevation of the Avodart control and Avodart-induced rats treated with 500 mg/kg EEAM relative to the normal control. Besides, there was no significant variation in the percentage of sperm cells with twisted tails of

the EEAM control and Avodart-induced rats treated with 1000 mg/kg EEAM, respectively, compared with the normal control. Contrarily, the EEAM control and Avodart-induced rats treated with 1000 mg/kg EEAM respectively showed a significant reduction in the percentage of sperm cells with twisted tails compared with the Avodart control.

The results in Table 1 indicate a significant increase in the total cytoplasmic droplets of the Avodart control in comparison with the normal control. However, the EEAM control and Avodart-induced rats treated with 500 and 1000 mg/kg EEAM showed a significant decline in the total cytoplasmic droplets compared to the normal control and Avodart control, respectively.

It was evidenced in Table 1 that there was a significant rise in the total abnormal sperm cells in the Avodart control, and Avodart-induced rats treated with 500 mg/kg EEAM had no significant decline in the total abnormal sperm cells compared with the normal control. The Avodart-induced rats treated with 1000 mg/kg EEAM had no significant decrease in the total abnormal sperm cells relative to the normal control. In contrast, the EEAM control and Avodart-induced rats treated with 500 and 1000 mg/kg EEAM significantly reduced the total abnormal sperm cells compared with the Avodart control.

**Table 1:** Sperm morphology of Avodart induced rats treated with EEAM

Treatments	Total Head Abnormality (%)	Bent mid-piece abnormality (%)	Sperm cell with twisted tail (%)	Total cytoplasmic droplets (%)	Total abnormal sperm cells (%)
Normal control	0.58±0.17a	0.07±0.01a	0.09±0.03a	1.72±0.05b	2.45±0.47a
Avodart control	1.34±0.29c	0.44±0.02b	0.20±0.01b	3.73±0.20c	5.71±0.43c
EEAM control (1000 mg/kg)	0.75±0.18a	0.11±0.01a	0.07±0.01a	1.14±0.07a	2.07±0.26a
Avodart + 500 mg/kg EEAM	1.01±0.03b	0.56±0.02b	0.15±0.02b	1.65±0.54b	3.38±0.76b
Avodart + 1000 mg/kg EEAM	0.71±0.12a	0.09±0.01a	0.10±0.02a	1.15±0.14a	2.05±0.025a

Values are presented as mean ± standard deviation (n = 6). The mean on the same column with different letter superscripts is significantly different (P < 0.05) from any paired value.

### Effects of EEAM on semen quality of Avodart-induced rats

The EEAM control and Avodart-induced rats treated with 500 and 1000 mg/kg EEAM showed no significant increase in the semen pH relative to the normal control (Table 2). Conversely, there was a considerable reduction in the semen

pH of the Avodart control compared with the normal control. In contrast, there was a significant increase in the semen pH of the EEAM control and Avodart-induced rats treated with 500 and 1000 mg/kg EEAM, respectively, compared with the Avodart control.

The semen colour in Table 2 in that only the Avodart control had milky white (1.00) semen colour compared to the normal control with creamy colour (2.00). In contrast, the EEAM control and Avodart-induced rats treated with 500 and 1000 mg/kg EEAM had creamy white semen colour, respectively, relative to the normal control.

The semen consistency in Table 2 showed that the Avodart control had significantly reduced semen consistency compared with the normal control. However, there was no significant variation in the semen consistency of EEAM control and Avodart-induced rats treated with 500 and 1000 mg/kg EEAM compared to the normal control. Conversely, the EEAM control and Avodart-induced rats treated with 500 and 1000 mg/kg EEAM had significantly increased semen consistency relative to the Avodart control.

The percentage of spermatozoa mass motility was significantly reduced in the Avodart control compared to the normal control (Table 2). Conversely, the percentage spermatozoa mass motility of the EEAM control and Avodart-induced rats administered 500 and 1000 EEAM mg/kg were significantly elevated compared to the normal and Avodart controls, respectively.

The percentage of spermatozoa live proportion in Table 2 showed a significant reduction in the Avodart control relative to the normal control. The percentage of spermatozoa live

proportion of the EEAM control and Avodart-induced rats treated with 1000 mg/kg EEAM were significantly higher than the normal control. However, there was no significant increase in the percentage of spermatozoa live proportion of the Avodart-induced rats administered 500 mg/kg EEAM compared with the normal control. In contrast, there was a significant elevation in the percentage spermatozoa live proportion of the EEAM control and Avodart induced rats treated with 500 and 1000 mg/kg, respectively, relative to the Avodart control.

The results in Table 2 indicated a significant decrease in the spermatozoa concentrations of the Avodart control compared to the normal control. Unlike the Avodart control, the EEAM control and Avodart-induced rats treated with 500 and 1000 mg/kg EEAM demonstrated a significant rise in the spermatozoa concentrations, respectively, compared with the normal control. The Avodart control, the EEAM control, and Avodart-induced rats treated with 500 and 1000 mg/kg EEAM had significantly elevated spermatozoa concentrations relative to the Avodart control.

There was a significant decline in the normal spermatozoa proportions of the Avodart control and Avodart-induced rats treated with 500 mg/kg EEAM compared to the normal control (Table 2). The EEAM control and Avodart-induced rats treated with 1000 mg/kg had a slight rise in the normal spermatozoa proportion compared to the normal control. Conversely, the EEAM control and Avodart-induced rats treated with 500 and 1000 mg/kg EEAM displayed a significant increase in the normal spermatozoa proportion relative to the Avodart control.

**Table 2:** Semen quality of Avodart induced rats treated with ethanol extract Aju Mbaise (EEAM)

Treatments	Semen pH	Semen colour	Semen consistency (1-4)	Spermatozoa mass motility (%)	Spermatozoa a live proportion (%)	Spermatozoa concentration (X10 <sup>6</sup> /ER)	Normal spermatozoa proportion (%)
Normal control	6.70±0.11 <sup>b</sup>	2.00±0.00 <sup>b</sup>	3.60±0.55 <sup>b,c</sup>	70.62±0.40 <sup>b</sup>	84.10±1.58 <sup>b</sup>	108.92±2.17 <sup>b</sup>	97.55±0.47 <sup>c</sup>
Avodart control	6.25±0.09 <sup>a</sup>	1.00±0.00 <sup>a</sup>	2.00±0.00 <sup>a</sup>	58.86±1.63 <sup>a</sup>	68.35±2.65 <sup>a</sup>	84.00±2.57 <sup>a</sup>	94.29±0.43 <sup>a</sup>
EEAM control (1000 mg/kg)	6.94±0.09 <sup>b</sup>	2.00±0.00 <sup>b</sup>	4.00±0.00 <sup>c</sup>	88.04±1.09 <sup>e</sup>	94.90±1.42 <sup>d</sup>	152.28±3.58 <sup>e</sup>	97.93±0.26 <sup>c</sup>
Avodart + 500 mg/kg EEAM	6.78±0.18 <sup>a</sup>	2.00±0.00 <sup>b</sup>	3.40±0.55 <sup>b</sup>	75.97±0.94 <sup>c</sup>	84.75±1.17 <sup>b</sup>	119.29±1.18 <sup>c</sup>	96.62±0.76 <sup>b</sup>

<b>Avodart + 1000 mg/kg EEAM</b>	6.95±0.16 <sup>b</sup>	2.00±0.00 <sup>b</sup>	4.00±0.00 <sup>c</sup>	80.18±0.86 <sup>d</sup>	88.82±2.37 <sup>c</sup>	130.84±4.20 <sup>d</sup>	97.95±0.25 <sup>c</sup>
--	------------------------	------------------------	------------------------	-------------------------	-------------------------	--------------------------	-------------------------

Values are presented as mean ± standard deviation (n = 6). The mean on the same column with different letter superscripts is significantly different (P < 0.05) from any paired value.

### Effects of EEAM on the sex hormonal levels of Avodart-induced rats

The results in Table 3 show a substantial decline in the serum testosterone level of the Avodart control compared with the normal control. Conversely, there was a significant elevation in the serum testosterone concentrations of the EEAM control and Avodart-induced rats treated with 1000 mg/kg EEAM relative to the normal control. Besides, the serum testosterone level in the Avodart-induced rats treated with 500 mg/kg EEAM showed a slight increase compared with the normal control. In contrast, the EEAM control and Avodart-induced rats treated with 500 and 1000 mg/kg EEAM showed significantly elevated serum testosterone levels compared with the Avodart control.

There was no significant reduction in the FSH concentrations of the Avodart control in comparison with the

normal control (Table 3). Contrarily, the EEAM control and Avodart induced rats treated with 500 and 1000 mg/kg EEAM demonstrated a significant elevation in FSH concentration compared with the Avodart control and normal control, respectively.

It was evidenced in Table 3 that there was a significant depletion of LH in the Avodart control relative to the normal control. The EEAM control and Avodart-induced rats treated with 500 mg/kg showed no increase in the LH concentration compared to the normal control. However, the Avodart-induced rats treated with 1000 mg/kg EEAM showed significantly elevated serum LH concentration compared with the normal control. Similarly, the EEAM control and Avodart-induced rats treated with 500 and 1000 mg/kg EEAM exhibited a significant rise in the serum LH concentrations relative to the Avodart control.

**Table 3:** Sex Hormonal levels of Avodart-induced rats treated with EEAM

Treatments	Testosterone (ng/L)	FSH (miu/ml)	LH (miu/ml)
Normal control	10.64±0.99 <sup>b</sup>	6.14±0.22 <sup>a</sup>	4.05±0.37 <sup>b</sup>
Avodart control	6.42±0.51 <sup>a</sup>	5.88±0.79 <sup>a</sup>	2.60±0.38 <sup>a</sup>
EEAM control (1000 mg/kg)	13.00±0.97 <sup>c</sup>	11.96±1.05 <sup>c</sup>	4.39±0.48 <sup>b,c</sup>
Avodart + 500 mg/kg EEAM	11.87±1.17 <sup>b,c</sup>	8.80±1.54 <sup>b</sup>	4.32±0.32 <sup>b,c</sup>
Avodart + 1000 mg/kg EEAM	14.31±0.98 <sup>d</sup>	10.90±1.08 <sup>c</sup>	4.70±0.25 <sup>c</sup>

Values are presented as mean ± standard deviation (n = 6). The mean on the same column with different letter superscripts is significantly different (P < 0.05) from any paired value.

**Keys:** FSH = follicle-stimulating hormone; LH = luteinizing hormone

### Effects of EEAM on the gonadosomatic index of Avodart-induced rats

The live animal weight in Table 4 indicated a significant decline in the Avodart control, EEAM control and Avodart-induced rats treated with 1000 mg/kg EEAM compared with the normal control. The Avodart-induced rats administered 500 mg/kg EEAM indicated a slight rise in live weight compared with the normal control. In contrast, there was a significant rise in the live weight of the EEAM control and

Avodart-induced rats treated with 500 and 1000 mg/kg EEAM, respectively, compared with the Avodart control.

There was a significant reduction in the weight of paired testes in the Avodart control compared with the normal control (Table 4). The EEAM control and Avodart-induced rats treated with 1000 mg/kg EEAM indicated a significant increase in their paired testes weight relative to the normal control. The Avodart-induced rats treated with 500 mg/kg EEAM showed a slight increase in the paired testes weight

compared with the normal control. Conversely, the EEAM control and Avodart-induced rats treated with 500 and 1000 mg/kg EEAM had significantly elevated paired testes weight compared with the Avodart control.

There was a significant reduction in the relative testicular weight of the Avodart control and a considerable increase in the relative testicular weight of EEAM control and Avodart-induced rats treated with 1000 mg/kg EEAM compared to the

normal control (Table 4). Conversely, the Avodart-induced rats treated with 500 mg/kg EEAM had no significant ( $P > 0.05$ ) increase in the relative testicular weight relative to the normal control. In contrast, the EEAM control and Avodart-induced rats treated with 500 and 1000 mg/kg EEAM showed a significant increase in their relative testicular weight compared with the Avodart control.

**Table 4:** Gonadosomatic index of Avodart-induced rats treated with EEAM

Treatments	Animal live weight (g)	Paired testes weight (g)	Relative testicular weight
Normal control	223.86±2.41 <sup>c</sup>	2.42±0.05 <sup>b</sup>	1.08±0.02 <sup>b</sup>
Avodart control	198.84±8.12 <sup>a</sup>	1.46±0.33 <sup>a</sup>	0.73±0.13 <sup>a</sup>
EEAM control (1000 mg/kg)	216.58±4.11 <sup>b</sup>	3.39±0.10 <sup>d</sup>	1.57±0.02 <sup>d</sup>
Avodart + 500 mg/kg EEAM	227.45±2.62 <sup>c</sup>	2.61±0.07 <sup>b,c</sup>	1.15±0.03 <sup>b</sup>
Avodart + 1000 mg/kg EEAM	213.50±5.71 <sup>b</sup>	2.73±0.09 <sup>c</sup>	1.28±0.02 <sup>c</sup>

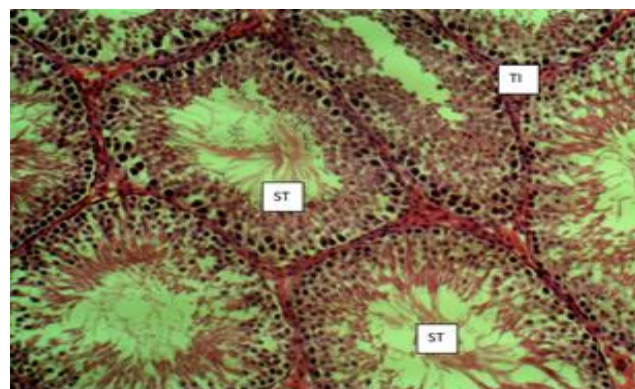
Values are presented as mean ± standard deviation (n = 5). Mean on the same column with different letter superscripts are significantly different ( $P < 0.05$ )

### Effects of EEAM on the testes histomorphology of Avodart-induced rats

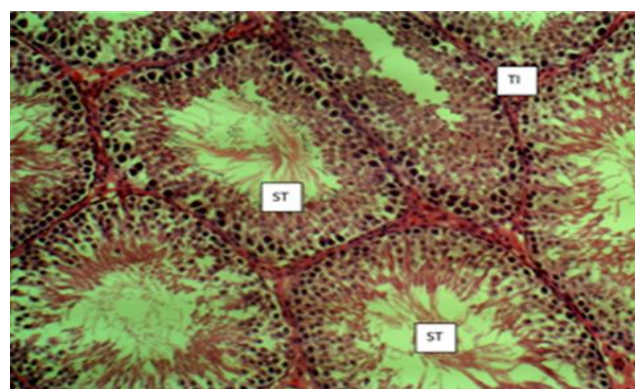
The sections of the testes of the normal control and EEAM control in Figures 1 A and 1 C, respectively, showed the normal testicular histo-architecture. Normal seminiferous tubules (ST) were observed with spermatocytes in the lumen and normal testicular interstitium (TI).

The sections of the testes of the Avodart control in Figure 1 B showed the normal testicular histo-architecture. However, there was decreased spermatogenic activity, evidenced by the relative absence of mature spermatocytes in the lumen of some seminiferous tubules (DST), compared to the relatively normal seminiferous tubules (ST) with spermatocytes in the lumen. Testicular interstitium (TI) showed normal histomorphology.

The sections of the testes of Avodart-induced rats treated with 500 and 1000 mg/kg EEAM in Figures 1 D and E indicated the normal testicular histo-architecture. However, there was mild decreased spermatogenic activity, evidenced by the relative absence of mature spermatocytes in the lumen of the seminiferous tubules (DST) compared to the relatively normal seminiferous tubules (ST) with spermatocytes in the lumen. Testicular interstitium (TI) showed normal histomorphology.



**Fig. 1 A:** Photomicrograph of testis from a normal control



**Fig. 1 B:** Photomicrograph of a testis from Avodart control



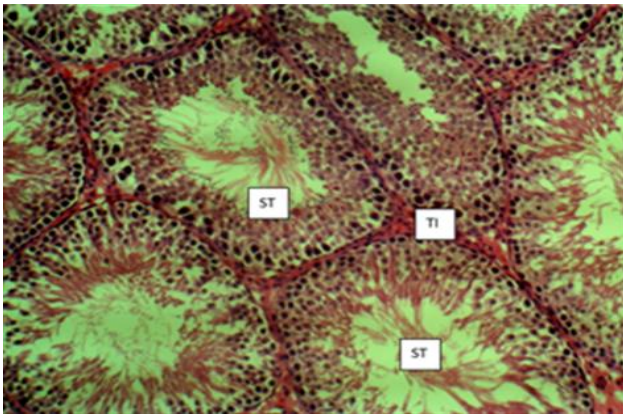


Fig. 1 C: Photomicrograph of a testis from EEAM control

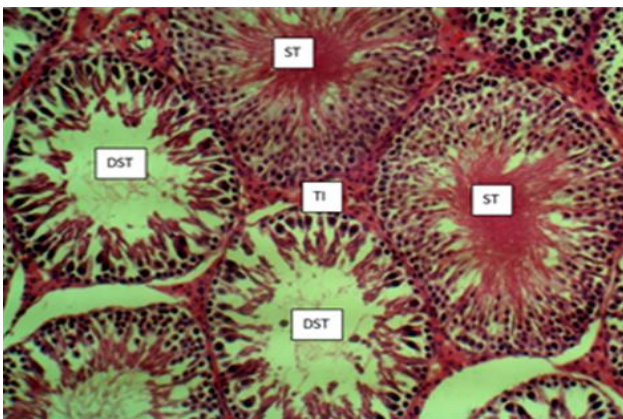


Fig. 1 D: Photomicrograph of a testis from Avodart induced rats treated with 500 mg/kg EEAM

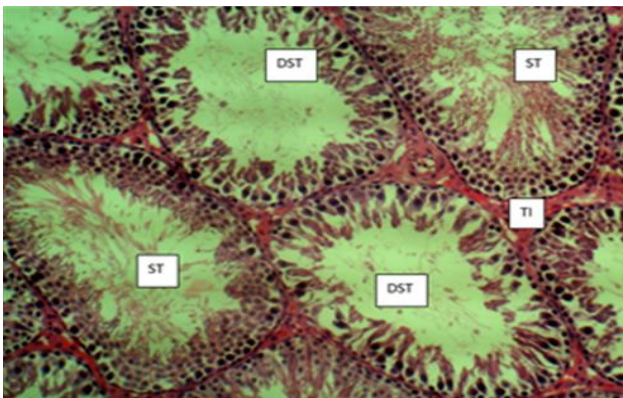


Fig. 1 E: Photomicrograph of a testis from Avodart induced rats treated with 1000 mg/kg EEAM

## Discussion

This study evaluated the effects of ethanol extract of *Aju Mbaise* (EEAM) on sperm morphology, semen quality, sex hormonal levels, gonadosomatic index and testicular histology of Avodart-induced rats. Optimal semen volume, pH, spermatozoa mass motility, spermatozoa concentration, and spermatozoa live proportion are promoted by normal serum levels of testosterone, LH, and FSH coupled with the functional testes are needed to ensure unhindered male

fertility potentials and reproductive life. Avodart is an example of dutasteride used for the treatment of enlarged prostate because of its ability to inhibit a 5 $\alpha$ -reductase activity which prevents the conversion of testosterone to dihydrotestosterone responsible for the proliferation of the prostate stromal and epithelial tissues [7]. The shrinking of prostate size by the Avodart activity also adversely affects prostate secretions, testicular size and functions, thereby causing alterations in sexual desire, loss of erection, a decline in the secretions of the accessory glands and impaired male fertility potentials.

Sperm morphology indicates the size and shape of sperm in semen viewed under a microscope. A substantial percentage of sperm with normal morphology is required to increase egg fertilisation. The reduction in the number of sperm cells with normal morphology may indicate that difficult to achieve egg fertilisation via sexual intercourse but through assisted fertilisation rather than infertility. These findings agree with previous results that abnormal sperm morphology, even at a low level, could impair the fertilisation rate [19]. The significantly increased total head abnormality, bent mid-piece abnormality, sperm cell with twisted tail, total cytoplasmic droplets and total abnormal sperm in the Avodart control relative to the normal control indicated the adverse effects of Avodart toxicity on the sperm morphology, which may reduce the ability of sperm ejaculated via sexual intercourse to access and penetrate an egg to achieve fertilisation. This finding is in line with earlier reports that morphological alterations of spermatozoa and motility give a more reliable fertility prognostic measure [20, 21]. The elevated total head abnormality, bent mid-piece abnormality, sperm cell with twisted tail, total cytoplasmic droplets and total abnormal sperm in the Avodart control suggest an increased risk of the rats being infertile if there is prolonged administration of Avodart. These showed that Avodart is not a suitable therapeutic agent for animals or individuals of reproductive age. The significant variation in the total head abnormality, bent mid-piece abnormality, sperm cell with twisted tail, and total abnormal sperm, along with significantly reduced total cytoplasmic droplets of sperm in the EEAM control relative to the normal control, showed that EEAM has no toxic effects on the sperm morphology. These findings suggest that ingestion of EEAM could reduce sperm abnormalities, improve fertility in animals, and avoid

infertility or assisted fertilisation. The significantly reduced levels of total head abnormality, bent mid-piece abnormality, sperm cell with twisted tail, total cytoplasmic droplets and total abnormal sperm in the Avodart-induced rats treated with 500 mg/kg EEAM compared with Avodart control showed the protective effects of EEAM on the sperm cells. However, these findings showed that EEAM could not effectively reverse the sperm abnormalities associated with Avodart toxicity as the levels of sperm abnormalities in the rats were far above the level of sperm abnormalities in the normal control.

Conversely, the significantly reduced total head abnormality, bent mid-piece abnormality, sperm cell with twisted tail, total cytoplasmic droplets and total abnormal sperm in the Avodart-induced rats treated with 1000 mg/kg EEAM comparable to the normal control showed the protective effects of the EEAM on the sperm cells and suggest that concomitant administration of EEAM and Avodart could preserve fertility index in animals or individuals undergoing Avodart treatment. The low percentage of total head abnormality, bent mid-piece abnormality, sperm cell with twisted tail, total cytoplasmic droplets and total abnormal sperm in the Avodart-induced rats treated with 1000 mg/kg EEAM indicated that the sperm possess increased ability to swim fast and penetrate viable egg for fertilisation. These are in line with the findings of Nallella et al., that decline in sperm count, reduced sperm motility, and increased sperm morphological alterations are major indicators of male infertility [22].

The significant reduction in the semen pH of the Avodart control relative to the normal control could be attributed to the toxic effects of Avodart on the testes and prostate gland and the blockage of the seminal vesicles. The pH levels of prostatic secretions regulate semen pH, seminal vesicular secretion and accessory gland secretions and impaired secretions or over secretions by any of them could alter the semen acidity. Thus, the high semen acidity level of Avodart control could be detrimental to the sperm and impede the ability of sperm to reach and penetrate a viable egg, which aligns with the report by Banjoko and Adeseolu [23]. However, no significant variations in semen pH of the EEAM control and Avodart-induced rats treated with EEAM compared to the normal control, though significantly higher than the Avodart control, showed the protective effects of

EEAM on the rats. The increase in the semen pH in the EEAM-treated rats could be responsible for the high sperm motility and other sperm quality parameters in the Avodart control, in line with the findings of Zhou et al. [24]. The normal pH values of semen from the EEAM control and Avodart-induced rats treated with EEAM could be attributed to the ability of EEAM to normal pH of the seminal vesicular, prostate gland and accessory gland secretions, thereby maintaining optimal acid balance to enhance sperm stability, motility and penetration of egg.

The milky white and slightly watery semen observed in the Avodart control relative to the creamy-white, and very thick semen of the normal colour showed slightly poor semen quality in the Avodart control. The low semen consistency in the Avodart control indicated that it would take a short time for the semen to exit the reproductive tract and that fewer spermatozoa are likely to remain in the reproductive tract for a long time. The findings suggest that the Avodart control rats had low spermatozoa concentration in the semen and agree with Björndahl and Kvist [25]. (2003). Thus, low semen consistency in the Avodart control rats suggests that it would be difficult for sperm to travel down the reproductive tract to fertilise an egg which would cause a decline in the reproductive potentials of the rats. Conversely, the creamy-white and high semen consistency of the EEAM control and Avodart induced rats treated with 500 and 1000 mg/kg EEAM compared to the Avodart control showed that EEAM treated rats had improved semen quality relative to the Avodart control. The significantly high semen consistency in the EEAM control and Avodart-induced rats treated with EEAM comparable to the normal control indicated high fertility potentials as the semen would have to spend much time in the reproductive tract before exiting, thereby increasing the chance of sperm in the semen having the possibility of fertilising an egg. These findings indicated improved sperm concentration in semen of the EEAM-treated rats in line with the previous reports by Björndahl and Kvist [25]. (2003).

Spermatozoa mass motility is the percentage of sperm cells in the semen that could penetrate the female reproductive tract and thereby transfer haploid cells of the male gametes to the ovary to form zygotes. The percentage of spermatozoa mass motility, spermatozoa concentration and semen morphology represent the major fertility parameters commonly evaluated to establish fertility status. The



significantly reduced spermatozoa mass motility in the Avodart control rats relative to the normal control indicated reduced fertility potentials due to the Avodart toxicity. The very low spermatozoa mass motility in the Avodart control suggests that the semen of the rats contains an increased percentage of sperm cells with reduced progressive motility to reach and penetrate the egg for fertilisation. The observed effects of Avodart on spermatozoa mass motility align with the findings of David et al., that motile sperm cells must travel fast via a female reproductive tract for fertilisation at the oviductal region before they can penetrate the egg [26]. The Avodart controls might have produced many abnormal and immature spermatozoa with low motility due to the adverse effects of Avodart on the testes and prostate gland.

Conversely, the dose-dependent significant increase in the percentage of spermatozoa mass motility of EEAM control and Avodart-induced rats treated with 500 and 1000 mg/kg EEAM, respectively, showed that EEAM possesses the therapeutic potential to boost spermatozoa mass motility and reverse adverse effects of Avodart on sperm cell motility. The EEAM could have promoted optimal spermatogenesis and maturation of sperm cells along with making the sperm cells more viable and motile to achieve fertilisation without any assistance. The increased spermatozoa mass motility in the EEAM-treated rats will translate into high fertility potentials if the spermatozoa have progressive motility and agree with Kumar and Singh that mass sperm motility is a good indicator of fertility status [27].

The significant decline in the percentage of spermatozoa live proportion in the Avodart control rats should mean that Avodart administration caused massive death of spermatozoa and thereby decreased their fertility potentials. The low spermatozoa live proportion in the Avodart control could be responsible for the low percentage of spermatozoa mass motility in the Avodart control, which suggests that the rats have a low fertility index. It also showed that Avodart might have a spermicidal activity that could have caused the death of most sperm cells in the Avodart control. The low spermatozoa live proportion in the Avodart control indicated impaired fertility in line with Amann and DeJarnette that reduced sperm viability showed decreased fertility because of the reduced chance of the fewer viable sperm cells from a single ejaculation attaining optimal fertility [28]. On the other hand, the elevated spermatozoa live proportion in the EEAM

control and Avodart-induced rats treated with EEAM showed that EEAM does not possess spermicidal property. These elevated spermatozoa live proportion in the EEAM control and Avodart-induced rats treated with EEAM showed that EEAM could protect the spermatozoa from the spermicidal activity associated with Avodart toxicity. The finding also suggests that ingestion of EEAM could improve sperm quality by increasing the percentage of spermatozoa live proportion, thereby increasing fertility potentials and the likelihood of achieving fertilisation without special assistance. These findings disagree with the previous report that the actual number of sperm cells attaining optimal fertility should be evaluated to ascertain fertility status instead of spermatozoa live proportion [28].

The significantly reduced spermatozoa concentration in the Avodart control compared to the normal control and Avodart-induced rats treated with EEAM can be attributed to the Avodart toxicity and impaired gonadotropin stimulation in line with previous findings [29]. The impairment of spermatogenesis by the toxic effects could produce fewer sperm cells, negatively affecting fertility. The destruction of spermatozoa by the Avodart toxicity could decrease spermatozoa concentration and life span of the sperm cells leading to reduced fertility if not complete infertility. This finding showed that a decline in the spermatozoa concentration is a major contributor to the decrease in fertility potentials after prolonged treatment with Avodart and other dutasteride. However, relative to the normal control, significantly elevated spermatozoa concentration in the EEAM control showed that Avodart administration stimulated spermatozoa production in the rats and could serve as a potent therapeutic agent against low spermatozoa concentration and promotes a high fertility index. The dose-dependent significant increase in the spermatozoa concentrations of the Avodart-induced rats treated with 500 and 1000 mg/kg EEAM, respectively, to the Avodart control showed the ameliorative effects of EEAM against the harmful impact of Avodart on the spermatozoa production. The dose-dependent increase in the spermatozoa concentrations in the Avodart-induced rats treated with EEAM indicated that EEAM could serve as an antifertility agent at increased doses. The significant increase in the spermatozoa concentration of Avodart-induced rats treated with EEAM aligns with Chua et al., that an increase in testosterone, FSH and LH levels could

cause increased sperm concentration and motility after increased gonadotropin stimulation [29].

The significant reduction of the normal spermatozoa proportion in the Avodart control relative to the normal control indicated that administration caused a significant decline in the fertility and reproductive potentials of the rats, in line with the earlier reports [29]. This decline in the normal spermatozoa proportion and the high total abnormal sperm cells in the Avodart control showed that Avodart administration adversely affected the quality of spermatozoa in the rats, which would affect the ejaculated sperm to fertilise a viable egg. In contrast, the high percentage of normal spermatozoa proportion in the EEAM control and Avodart-induced rats treated with EEAM further showed the anti-infertility potentials of EEAM and its ability to boost sperm quality in animals, similar to the findings of Amann and DeJarnette [28]. It also showed that Avodart-induced rats administered 1000 mg/kg EEAM mg/kg recovered better from the adverse effects of Avodart than the rats administered a lower dose, suggesting that a higher amount of EEAM should be administered as the treatment for decreased normal spermatozoa proportion or infertility.

Avodart is a member of dutasteride derivatives employed for managing prostate enlargement due to its ability to inhibit 5 $\alpha$ -reductase enzyme activity, preventing dihydrotestosterone conversion (DHT). It has been observed that the use of dutasteride has toxic effects on the male fertility parameters, including decline in sperm count and motility, erectile and ejaculatory dysfunction, and therefore, Avodart and other dutasteride are not recommended for use on animals or patients within child bearing age [5, 30]. Testosterone is a key androgenic hormone that modulates spermatogenesis and testicular activities in males, and its serum levels could indicate poor sperm quality and male infertility. The follicle-stimulating hormone (FSH) promotes testicular growth by stimulating the Sertoli cells to synthesise an androgen-binding protein required by the testicular tubule that enhances the maturation of sperm cells. The serum luteinising hormone influences male fertility via modulation of the activities of Leydig cells that synthesise testosterone and thus, indirectly regulate spermatogenesis because its abnormal level could lead to infertility which is essential for spermatogenesis. Therefore, these three hormones work in synergy to enhance sperm quality and male fertility;

alterations in any or all of them could lead to reduced fertility or infertility in males, according to Baccetti et al [31]. The significantly reduced testosterone, LH and no significant decrease in the serum FSH level in the Avodart control rats compared to the normal control could be attributed to the effects of Avodart toxicity on the testicular functions and pituitary gland. The low serum testosterone, LH, and FSH levels in the Avodart control might be responsible for the low sperm count, spermatozoa mass motility and increased abnormal spermatozoa morphology observed in the Avodart control relative to the normal control, EEAM control and Avodart induced rats treated with EEAM respectively. These findings suggest that testosterone, LH and FSH supplementation might restore the abnormal spermatozoa quality observed in the Avodart control to a normal level and improve its fertility potential. The reduction in the serum sex hormonal levels in the Avodart control rats aligns with the previous findings that males with a substantial decrease in the circulating serum sex hormonal levels had poor sperm quality [33]. In addition, the significantly elevated testosterone, LH, and FSH in the EEAM control and Avodart induced rats treated with 500 and 1000 mg/kg EEAM, respectively, relative to the Avodart control, showed that EEAM promotes male fertility via stimulation of testosterone, LH and FSH production. The substantial serum levels of testosterone, LH, and FSH in the EEAM control and Avodart-induced rats treated with EEAM are in tandem with the improved sperm morphology and sperm quality observed in the rats relative to the Avodart control. These findings agree with Baccetti et al., that increased serum FSH and LH levels improve sperm quality and fertility rate by promoting spermatogenesis via stimulation of increased testosterone production [31].

The significantly reduced animal live weight of the Avodart control relative normal control and Avodart control induced rats treated with EEAM respectively showed that the Avodart control rats suffered a loss of body weight which could have affected spermatogenesis and maturation of spermatozoa. The substantially low sperm motility, spermatozoa mass motility, spermatozoa live proportion, spermatozoa concentration, and normal spermatozoa proportion, along with highly altered sperm morphology, suggest that massive loss in bodyweight adversely affected the sperm quality. The reduced spermatozoa count in the Avodart control with significantly reduced body weight is in



line with previous findings that males with underweight had low sperm counts, semen volume, sperm concentration and low sperm motility compared to the normal control [33, 34]. However, the elevated EEAM control and Avodart-induced rats treated with EEAM showed that treatment with EEAM alleviated the adverse effects of Avodart on the body weight of the rats. Also, the improved sperm quality and sperm morphology in the Avodart-induced rats treated with EEAM, contrary to the Avodart control, suggest that the administration of EEAM increased the sperm quality and fertility potentials of the rats. The high sperm quality and fertility potentials of the Avodart-induced rats treated with EEAM agree with Luque et al., that normal body weight is essential for normal fertility [33].

The substantially reduced paired testes weight and relative testicular weight compared to the normal control showed that the testes of the rats were shrunk considerably by the toxic effects of Avodart drug on the Avodart-induced untreated rats, in line with the findings of Ikpeme et al. [35]. The substantial decrease in the paired testes weight and relative testicular weight relative to the normal control suggest that having normal testes sizes and relative testicular weight are critical to producing enough semen volume, highly motile sperm cells with unaltered morphology along with the required semen pH that would promote or increase male fertility. The marked reduction in the testicular and relative testicular weight is similar to the decrease in testicular weight reported by Mutalip et al., on effect of testosterone, nandrolone and stanozolol-treated rats, respectively. Conversely, the substantial rise in the paired testicular weight and relative testicular in the EEAM control and Avodart-induced rats treated with varying doses of EEAM compared to the Avodart control are attributed to the therapeutic effects of EEAM against Avodart toxicity on the testes. These rise in the paired testicular weight and relative testicular in the EEAM-treated rats showed that EEAM administration prevented the shrinking of testes associated with impaired testicular functions. The effect of EEAM on the testes aligns with Ikpeme et al., that increase in the spermatozoa concentration and sperm motility are associated with increased testes weight [35]. The Avodart-induced rats with relatively normal paired testes weight and relative testicular had improved sperm quality parameters and better sperm morphology together with substantial testosterone, LH and

FSH, which indicated improved fertility potentials in the EEAM rats compared to the Avodart control in line with Colpi et al. [36].

The normal testicular histomorphology of the EEAM control with unaltered spermatogenic activity similar to the normal control showed that EEAM does not adversely affect the testes and testicular functions. However, the normal testicular histo-architecture of the Avodart control with a substantial decline in spermatogenic activity and lack of mature spermatocytes in the lumen of some seminiferous tubules indicated that the Avodart control rats had impaired testicular functions. The massive decline in the spermatogenic activity and absence of mature spermatocytes in most of the lumen in seminiferous tubules of the Avodart control is in line with the finding of Mutalip et al. [37]. The low spermatogenic activity and lack of mature spermatocytes in the lumen of some seminiferous tubules could be responsible for the low spermatozoa mass motility, decreased spermatozoa concentration, low spermatozoa live proportion and increased spermatozoa abnormality in the Avodart control and might increase the risk of infertility. Furthermore, the normal testicular histo-architecture observed in the Avodart-induced rats treated with 500 and 1000 mg/kg EEAM, respectively, with a mild reduction in the spermatogenic activity compared to the Avodart control showed restoration of the testicular functions. The effect of EEAM on the testicular functions suggests that EEAM administration could not completely restore the testicular functions and might have contributed to a slight reduction in the sperm quality and sperm morphological changes observed in the EEAM-treated rats relative to the normal control and agree with the findings of Mutalip et al. [37].

### Conclusion

The findings of this study indicated that treatment of Avodart-induced rats with EEAM significantly restored the altered sperm quality, sperm morphology, paired testicular weight, relative testicular weight, serum testosterone, luteinising hormone, and follicle-stimulating hormonal levels to normal. The EEAM administration also improved testicular functions and testicular histo-architecture, and these findings further suggest that EEAM administration could improve fertility potential.

## Conflict of interest

The authors do not have any conflict of interest.

## Recommendations

Adequate intake of Aju Mbase improve semen and sperm quality.

Aju Mbase prevents alterations of the androgen levels and testicular functions males.

Use of Avodart for treatment purposes should be discouraged in males of reproductive age except where the gains outweigh the adverse effect.

## List of abbreviations

EEAM = ethanol extract of Aju Mbase; LH = luteinising hormone; FSH = follicle stimulating hormone; ST = seminiferous tubules; TI = Testicular interstitium; DST = decreased spermatogenic activity in the seminiferous tubules.

## References

- Di Guardo F, Vloeberghs V, Bardhi E, Blockeel C, Verheyen G., Tournaye H, Drakopoulos P. Low Testosterone and Semen Parameters in Male Partners of Infertile Couples Undergoing IVF with a Total Sperm Count Greater than 5 Million. *J Clin Med.* 2020; 9(12), 3824.<https://doi.org/10.3390/jcm9123824>.
- Smith LB, Walker WH. The Regulation of Spermatogenesis by Androgens. In *Seminars in Cell and Developmental Biology*; Academic press: London, UK 2014; pp. 2-13.
- Ventimiglia E, Capogrosso P, Boeri L, Ippolito S, Scano R, Moschini M, Gandaglia G.; Papaleo E, Montorsi F, Salonia A. Validation of the American Society for Reproductive Medicine Guidelines/Recommendations in White European Men Presenting for Couple's Infertility. *Fertil Steril.* 2016; 106:1076-1082.e1.<https://doi.org/10.1016/j.fertnstert.2016.06.044>
- Perreault SD, Cancel AM. Significance of incorporating measures of sperm production and function into rat toxicology studies. *Reprod.* 2001; 121: 207-216.<https://doi.org/10.1530/rep.0.1210207>
- Semet M, Paci M, Saéias-Magnan J, Metzler-Guillemain C, Boissier R, Lejeune H, Perrin J. The impact of drugs on male fertility: A review. *Androl.* 2017; 5: 640-663.<https://doi.org/10.1111/andr.12366>
- Gur S, Kadowitz PJ, Hellstrom WJ. Effects of 5-alpha reductaseinhibitors on erectile function, sexual desire and ejaculation. *Expert Opin Drug Saf.* 2013; 12: 81-90.<https://doi.org/10.1517/14740338.2013.742885>
- Traish AM, Melcangi RC, Bortolato M, Garcia-Segura LM, Zitzmann M. Adverse effects of 5a-reductase inhibitors: What do we know, don't know, and need to know? *Rev Endocr Metab Disord.* 2015; 16: 177-198.<https://doi.org/10.1007/s11154-015-9319-y>
- Enatsu N, Chiba K, Sumii K, Fukuda T, Okada K, Matsushita K, Fujisawa M. Dutasteride-mediated morphological changes in the genitourinary tract associated with altered expression patterns of the androgen and estrogen receptors in male rats. *Androl.* 2017; 5: 347-353.<https://doi.org/10.1111/andr.12297>
- Idu M, Uwaya D, Ovuakporie-Uvo O. *In Vivo* Antioxidant ctivities of *Combretum platypterum* (Welw.) Hutch. and *Combretum racemosum* P. Beauv. (Combretaceae). *Appl Med Res.* 2016; 2(3): 50-55.<https://doi.org/10.5455/amr.20160818035633>
- Salim MN, Masyitha D, Harris A, Balqis U, Iskandar CD, Hambal M, Darmawi. Anti-inflammatory activity of *Jatropha curcas* Linn. latex in cream formulation on CD68 expression in mice skin wound. *Vet World.* 2018; 11(2): 99-103.<https://doi.org/10.14202/vetworld.2018.99-103>
- Evbakhavbokun O, Ekkrakene T, Ebakota OD, Olisaka FN. Phytochemical screening, liver toxicity and antibacterial properties of aqueous and ethanol extracts of a local herbal mixture "Aju Mbase. *Trop J Nat Prod Res.* 2020; 4(6): 237-242. Available online at<https://www.tjnpr.org>
- Ezejindu CN, Iro OK. Antibacterial activity, phytochemical properties and mineral content of "Aju Mbase" decoction administered to nursing mothers. *Direct Res J Health Pharm.* 2017; 5(3): 33-38. <https://doi.org/10.26765/DRJHP>
- Nnadiukwu TA, Ighorodje CCM, Chuku LC. Nutritional Composition of 'Aju Mbase' Herbal Cocktail. *Asian J Res Biochem.* 2020; 31: 30-7.<https://doi.org/10.9734/ajrb/2020/v7i230136>

14. Nnadiukwu AT, Monago-Ighorodje CC, Chuku LC. Phytochemical Composition of Ethanol Extract of a Cocktail Herbal Mixture (*Aju Mbaise*). *J Adv Biol Biotechnol*. 2019; 22(1): 1-11. <https://doi.org/10.9734/jabb/2019/v22i130103>
15. Ijioma SN, Osim EE, Nwankwo AA, Nwosu CO, Ekeleme CM. Antioxidant potentials and effects on the hematology and osmotic fragility scores of a polyherbal formulation used in Southeast Nigeria. *J Basic Clin Physiol Pharmacol*. 2019; 30(4). <https://doi.org/10.1515/jbcpp-2017-0099>
16. Dhumal SS, Naik P, Dakshinamurthy S, Sullia K. Semen pH and its correlation with motility and count: A study in subfertile men. *JBRA Assist Reprod*. 2021; 25(2):172-175. <https://doi.org/10.5935/15180557.2020008>
17. El-Sherbiny AM. *Seasonal variation in seminal characteristics of rabbits*. M.Sc. Dissertation. Fac. of Agric Ain-Shams University 1987.
18. Herbert. Growth and reproductive characteristics of rabbits fed on *Leucaena* (*Leucaena leucocephala*) and (*Gliricidia sepium*) foliage 1992. PhD Thesis.
19. Menkveld R, Stander FS, Kotze TJ, Kruger TF, van Zyl JA. The evaluation of morphological characteristics of human spermatozoa according to stricter criteria. *Hum Reprod*. 1990; 5: 586-592. <https://doi.org/10.1093/oxfordjournals.humrep.a137150>
20. Van Waart J, Kruger TF, Lombard CJ, Ombelet W. Predictive value of normal sperm morphology in intrauterine insemination (IUI): A structured literature review. *Hum Reprod Update*. 2001; 7: 495-500. <https://doi.org/10.1093/humupd/7.5.495>
21. Keegan BR, Barton S, Sanchez X, Berkeley AS, Krey LC, Grifo J. Isolated teratozoospermia does not affect *in vitro* fertilisation outcome and is not an indication for intracytoplasmic sperm injection. *Fertil Steril*. 2007; 88: 1583-1588. <https://doi.org/10.1016/j.fertnstert.2007.01.057>
22. Nallella KP, Sharma RK, Aziz N, Agarwal A. Significance of sperm characteristics in the evaluation of male infertility. *Fertil Steril*. 2006; 85: 629-634. <https://doi.org/10.1016/j.fertnstert.2005.08.024>
23. Banjoko SO, Adeseolu FO. Seminal plasma pH, inorganic phosphate, total and ionised calcium concentrations in the assessment of human spermatozoa function. *J Clin Diagn Res*. 2013; 7: 2483-2486. <https://doi.org/10.7860/JCDR/2013/6194.3585>
24. Zhou J, Chen L, Li J, Li H, Hong Z, Xie M, Chen S, Yao B. The semen pH affects sperm motility and capacitation. *PLoS One*. 2015; 10(7): e0132974. <https://doi.org/10.1371/journal.pone.0132974>
25. Björndahl L, Kvist U. Sequence of ejaculation affects the spermatozoon as a carrier and its message. *Reprod Biomed Online*. 2003; 7(4): 440-448. [https://doi.org/10.1016/S1472-6483\(10\)61888-3](https://doi.org/10.1016/S1472-6483(10)61888-3)
26. David I, Kohnke P, Lagriffoul G, Praudf O, Plouarboué F, Degond P, Druart X. Mass sperm motility is associated with fertility in sheep. *Anim Reprod Sci*. 2015; 161: 75-81. <https://doi.org/10.1016/j.anireprosci.2015.08.006>
27. Kumar N, Singh AK. Trends of male factor infertility, an important cause of infertility: A review of literature. *J Hum Reprod Sci*. 2015; 8(4):191-196. <https://doi.org/10.4103/0974-1208.170370>
28. Amann RP, DeJarnette JM. Impact of genomic selection of AI dairy sires on their likely utilisation and methods to estimate fertility: A paradigm shift. *Theriogenology*. 2012; 77:795–817. <https://doi.org/10.1016/j.theriogenology.2011.09.002>
29. Chua ME, Escusa KG, Luna S, Tapia LC, Dofitas B, Morales M. Revisiting oestrogen antagonists (clomiphene or tamoxifen) as medical empiric therapy for idiopathic male infertility: A meta-analysis. *Androl*. 2013, 1: 749-757. <https://doi.org/10.1111/j.2047-2927.2013.00107.x>
30. Millsop JW, Heller MM, Eliason MJ, Murase JE. Dermatological medication effects on male fertility. *Dermatol Ther*. 2013; 26: 337-346. <https://doi.org/10.1111/dth.12069>
31. Baccetti B, Piomboni P, Bruni E, Capitani S, Gambera L, Moretti E, Sterzik K., Strehler E. Effect of follicle-stimulating hormone on sperm quality and pregnancy rate. *Asian J Androl*. 2004; 6(2): 133-137. <https://doi.org/10.1530/EC-15-0050>
32. Aggerholm AS, Thulstrup AM, Toft G, Ramlau Hansen CH, Bonde JP. Is overweight a risk factor

- for reduced semen quality and altered serum sex hormone profile? *Fertil Steril*. 2008; 90: 619-626.<https://doi.org/10.1016/j.fertnstert.2007.07.1292>
33. Luque EM, Tissera A, Gaggino MP, Molina RI, Mangeaud A, Vincenti LM, Beltramone F, Larcher JS, Estofán D, Fiol de Cuneo M, Martini AC. Body mass index and human sperm quality: Neither one extreme nor the other. *Reprod Fertil Dev*. 2017; 29(4):731-739.<https://doi.org/10.1071/RD15351>.
34. Jafari H, Mirzaiinajmabadi K, Roudsari RL, Rakhshkhorshid M. The factors affecting male infertility: A systematic review. *Int J Reprod Biomed*. 2021; 19(8): 681-688.<https://doi.org/10.18502/ijrm.v19i8.9615>.
35. Ikpeme EV, Ekaluo UB, Udensi O, Ekerette EE, Ekpo PB, Asuquo BO. Sperm quality and hormone profile of male albino rats fed with seeds of African walnut (*Tetracarpidium conophorum*, Mull). *Annu Res Rev Biol*. 2014; 4(9): 1379-1386. <https://doi.org/10.9734/ARRB/2014/5426>
36. Colpi GM, Francavilla S, Haidl G, Link K, Behre HM, Goulis DG, Krausz C, Giwercman A. European Academy of Andrology guideline Management of oligo-astheno-teratozoospermia. *Androl*. 2018; 6: 513-524.<https://doi.org/10.1111/andr.12502>.
37. Mutalip SSN, Singh GKS, Shah AM, Mohamad M, Mani V, Hussin SN. Histological changes in testes of rats treated with testosterone, nandrolone, and stanozolol. *Iran J Reprod Med*. 2013; 11(8): 653-658. PMID: 24639803; PMCID: [PMCID: PMC3941368](https://pubmed.ncbi.nlm.nih.gov/24639803/).