










Effect of Zinc Nanoparticles of Aqueous Extract of *Matricaria chamomilla* on the Prevention of Gastric Ulcer Caused by Alcohol

Navid Etemadi¹, Neda Ahmadiafshar², Somayeh Ahmadiafshar³, Akram Zangeneh⁴,
Mohammad Mehdi Zangeneh⁴✉, Samira Zand³, Siavosh Kaki Sahne⁵, Seyyed Jamaledin
Tabatabaei Aghda³, Abbas Gheysouri⁶

¹DVM Graduate, Faculty of Veterinary Medicine, Urmia University, Urmia, Iran

²Candidate for DVSc in Clinicalpathology, Department of Clinical Pathology, Faculty of Veterinary Medicine, University of Tehran, Tehran, Iran

³Department of Microbiology, Faculty of veterinary Medicine, Urmia University, Urmia, Iran

⁴Biotechnology and Medicinal Plants Research Center, Ilam University of Medical Sciences, Ilam, Iran

⁵DVM Student, Faculty of Veterinary Medicine, Urmia University, Urmia, Iran

⁶Assistant Professor of Pulmonary Diseases, Department of Internal Medicine, School of Medicine, Emam Khomeini Hospital, Ilam University of Medical Sciences, Ilam, Iran

Corresponding Author, Biotechnology and Medicinal Plants Research Center, Ilam University of Medical Sciences, Ilam, Iran. Email: m.mehdizangeneh@yahoo.com

Article Info

Article type:

Research Article

Article History:

Received: 01 June 2022

Received in revised form:
15 June 2022

Accepted: 9 June 2022

Published online: 23 Nov
2022

Keywords:

Zinc nanoparticle,
Matricaria chamomilla, Rat,
Gastroduodenal ulcer,
Ethanol

Abstract

Background: Many people in the world suffer from gastroduodenal ulcers, therefore, studying the therapeutic strategies of these ulcers are considered as the research priorities in any country. The aim of this study was to survey the preventive property of zinc nanoparticles of *Matricaria chamomilla* on ethanol-induced gastroduodenal ulcers in rats.

Methods: In this study, 30 adult females rats were divided into 5 groups, randomly: negative healthy control receiving distilled water, untreated negative control receiving distilled water, positive control receiving omeprazole 60 mg/kg, one group receiving the aqueous extract of *M. chamomilla* at 200 mg/kg concentrations, and another group receiving the zinc nanoparticles of aqueous extract *M. chamomilla* at 0.5mg/kg concentrations. After 14 days, gastroduodenal ulcers were caused by ethanol. Four hours after oral administration of ethanol, the stomach, and duodenum samples of the rats were dissected. Malondialdehyde, Superoxide dismutase activity, and prevention index were measured and histopathological studies were performed.

Results: The zinc nanoparticles of aqueous extract *M. chamomilla* could significantly decrease the raised levels of MDA and INU and enhance SOD and IU as compared to other groups. Also, the zinc nanoparticles of aqueous extract prevented significantly small, medium, and large gastroduodenal ulcers as compared to other groups.

Conclusion: It seems that the zinc nanoparticles of aqueous extract *M. chamomilla* can prevent gastroduodenal ulcers in rats without any side effect.



Introduction

Gastric disorders are one of the most common problems affecting humans worldwide, and among these disorders, a number such as gastritis, ulcers, gastric lymphoma and infections of pathogenic microorganisms have high mortality and morbidity [1]. The term peptic ulcer disease (PUD) are wounds in the gastrointestinal tract (GIT) that can sometimes involve all layers up to the muscular layer and pierce the wall of the gastrointestinal tract at the wound site [2]. Ulcer is a gastrointestinal disorder that can be caused by several factors and generally occurs when the balance between aggressive and defensive factors of the gastric and duodenal mucosa is lost [3]. Gastric ulcer is the sores of the stomach lining or duodenum which is a common disease all over the world, Increasing the costs with public health [4]. There are a number of risk factors for gastric ulcer disease in people, including nonsteroidal anti-inflammatory drugs (NSAIDs), *Helicobacter pylori*, stress and steroids [5]. Drugs with proton pump inhibitors such as Omeprazole and H₂ receptor antagonists are used to treat the disease, but the problem is the common side effects and the widespread risk of recurrence after treatment [6]. Ethanol is one of the most common pathogenic factors of gastric injury [7]. When ethanol is given orally to rats, it causes severe hemorrhagic lesions of the stomach. Reduction of gastric mucosal content, mucosal blood flow damage and mucosal cell damage are involved in the pathogenesis of gastric lesions caused by ethanol. Furthermore, ethanol-induced gastric mucosal damage is associated with excessive production of ROS, leading to increased lipid peroxidation. Increased lipid peroxidation and ROS lead to significant changes in cellular levels and cause membrane damage, cell death, epithelial desquamation and erosion [8]. Therefore, in the study of compounds with anti-ulcer properties, ethanol is widely used to induce gastric ulcer in animal models. [9][10]. The results of previous studies indicate that plant extracts rich in phenolic

and antioxidant compounds mainly have promising results in the treatment of gastric ulcers [11].

The plant genus *Matricaria chamomilla* includes more than 1500 species and its characteristics include its strong aroma and bitter taste [12]. *M. chamomilla* has many medicinal properties and applications, so that in some countries such as China, Japan and Korea, it is traditionally used to treat diseases such as inflammation, abdominal pain, bleeding, hepatitis and liver cirrhosis [13]. Liver protection [14], pain relief [15] and antipyretic effects [16] are examples of various physiological activities of *M. chamomilla*. *M. chamomilla* is known for its beneficial effects in the treatment of gastrointestinal disorders, including gastric ulcers [17]. Many past studies have shown different properties of *M. chamomilla*, for example, antioxidant properties [18], anti-diabetic [19], anti-hyperlipidemic [20], anti-inflammatory [21] and anti-tumor effects [22]. *M. chamomilla* also has the property of reducing the symptoms of allergic asthma and dermatitis in the body and has an immunosuppressive activity [23]. The medicinal effects of *M. chamomilla* are due to the presence of flavonoids eupatilin, jaceocidine, hispidolin and caffeine quinic acid [24].

Over the past two decades, nanotechnology has improved medical science both in the diagnosis and monitoring of disease and in the treatment (with deliver both small-molecule and large macromolecular) [25][26]. Nanoparticles have received a lot of attention in biomedicine due to their biological, chemical and physical properties [27]. Liposomes, polymer nanoparticles, nanostructures, metal nanoparticles, stimulus-responsive nanoparticles are among the new nanoparticle formulations with different architecture [28]. In this study, an extract of *M. chamomilla* was prepared and zinc nanoparticles were used to deliver *M. chamomilla* extract to rats, and finally, the preventive effect of *M. chamomilla* extract on gastric ulcers was measured by measuring the levels of superoxide dismutase (SOD) and

malondialdehyde (MDA) and the effect of this extract was investigated in the healing of gastric ulcer.

Methods

This experimental study was performed in the Department of Microbiology, Faculty of Veterinary Medicine, Urmia University in the summer of 1400. *M. chamomilla* plant was collected from Golestan province and sent to the herbarium of Jihad Agricultural Research Center of Kermanshah province to identify and confirm the species, species and subspecies.

Method of preparation of aqueous extract of *Matricaria chamomilla*:

Aqueous extracts of *M. chamomilla* were prepared by the following procedure: 500 grams of the seeds of this plant were weighed and thoroughly dried in the shade and thoroughly mixed and powdered with the help of an electric grinder. To extract the aqueous extract of *M. chamomilla*, Then 5 liters of distilled water was added to it and placed on a shaker at room temperature for 24 hours to mix thoroughly. The mixture was filtered using the Whatman 1 filter paper. Extraction in vacuum was performed using a freeze dryer. The extract was weighed. Store at -70°C until use. The extract was stored at -70°C for further use to synthesize nanoparticles[29].

Preparation of a combination of zinc metal nanoparticles and aqueous extract of *Matricaria chamomilla*:

To prepare a combination of zinc metal nanoparticles and *M. chamomilla* aqueous extract, initially 10 ml of aqueous extract of *M. chamomilla* was added to 100 ml of nanopolymer of zinc ($\text{HZnCl}_4 \times \text{H}_2\text{O}$) (1 mM) and kept at room temperature for one hour. After this time a color

change was observed, indicating the beginning of the synthesis of a combination of silver nanopolymer with *M. chamomilla* aqueous extract. The resulting mixture was then centrifuged at 1200 rpm for 15 minutes and the top part removed[30].

Characterization: At the presented work, characterization of nanoparticles was performed using various spectroscopic analyses such as Transmission Electron Microscope (TEM), scanning electron microscopy (SEM), Fourier-transform infrared spectroscopy (FTIR), and UV-visible. TEM was used to determine the shape and size of the produced nanoparticles. To precisely estimate the size of nanoparticles, transmission electron microscopy was used. SEM, FTIR and UV-Vis was used to characterize, identify, study nanomaterials and determine the morphology[31].

In the study, we purchased 30 female rats weighing approximately 180 g from the Laboratory Animal Breeding Center of the Faculty of Pharmacy, Urmia University of Medical Sciences, and two weeks after adaptation randomly divided them into five groups (n=6), including:

Control group: Receive 0/5 cc of physiological serum by gavage for 14 days

Receiving normal saline group: Receive 0/5 cc of absolute alcohol orally by gavage.

Receiving omeprazole group: Receive 60 mg / kg Omeprazole orally and by gavage for 14 days (in addition, on the twentieth day, 0/5 cc of alcohol was prescribed).

M. chamomilla aqueous extract group: Receive 200 mg/kg aqueous extract of *M. chamomilla* orally and by gavage for 14 days (in addition, on the twentieth day, 0/5 cc of alcohol was prescribed).

Zinc metal nanoparticles and aqueous extract of *M. chamomilla*: Received 0.5 mg / kg nanoparticles of zinc metal and aqueous extract of *M. chamomilla* orally and by gavage for 14 days (in addition, on the twentieth day, 0/5 cc of alcohol was prescribed).

Each group of rats was kept in separate cages and clean environment with a constant temperature of 22°C and a 12-hour cycle of light and dark (L: D), and had access to adequate water and food. All experiments followed to the ARRIVE guidelines (<https://arriveguidelines.org>), were approved by the University of Urmia Animal Ethics Committee and were performed in accordance with the relevant guidelines and regulations.

After 20 days, the animals were anesthetized with chloroform and blood samples were taken directly from the animals' hearts. A slice of a large bent stomach was placed in metal foil and placed at -80 °C to measure SOD and MDA.

Malondialdehyde measurement: The TBARS test is a direct quantitative method for measuring the MDA of biological samples. TBA was reconstituted in refrigerated acetic acid. BHT was used in lysis buffer during sample preparation to stop further sample peroxidation while processing. To assay the samples, TBA was added solution to prepared samples. Incubate at 95°C for 60 minutes and was cooled to room temperature in an ice bath for 10 minutes. The output was measured immediately after processing the samples, on a microplate reader at OD 532 nm for a colorimetric assay. The MDA value of the unknown samples was determined by comparing it with the standard MDA curve [32].

Estimation of antioxidant enzymes

Superoxide dismutase activity was determined in gastric homogenates by monitoring the enzymatic ability to inhibit dye reduction of nitroblue tetrazolium through phenazine methosulfate²⁵. In short, the sample (0.05 ml) was added to the reaction mixture (1.3 ml) consisting of phosphate buffer (0.1 M; pH 8.5), nitroblue tetrazolium (0.3 mmol), reduced nicotinamide adenine dinucleotide (0.47 mmol), and phenazine methosulfate (93 μM). An increase in absorbance was recorded at 560 nm for 5 min. Superoxide dismutase activity data were expressed as a unit per mg of protein [33].

Wound evaluation method

After killing the mice (in both wounding methods), the abdominal area was immediately resected and the entire stomach was exposed. An incision was made along the greater flexure of the stomach and placed in 10% formaldehyde. Macroscopic examinations were performed using a loupe or a hand lens to observe the presence of wounds and the wounds were scored. Using the standard method [34] for all groups of gastric ulcers with a diameter of one millimeter or more were counted and five ulcers with a diameter less than one millimeter petechiae (Ulcer index) : UI) mm was considered. The wound index based on the cross-sectional area of the wounds (in square millimeters) was determined in each group, and then the percentage of the wound prevention index was determined for each group based on the following formula.

$$\text{Prevention index (percentage)} = 100 \times [(A-B)/A]$$

A: Ulcer index in the group receiving ethanol

B: Ulcer index in the therapy groups

Histopathological examination

Stomach residue is placed in 10% formalin for histopathological examination. After 48 hours, tissue preparation steps were performed and paraffin blocks were prepared using. Rotational microtomes of 5 micron thick paraffin sections were taken. It was then stained with hematoxylin and eosin staining method. The sections were stained and studied under a light microscope.

Statistical analysis: For quantitative information, two-way ANOVA statistical method and then Tukey method were used. All results were expressed as $M \pm SD$ and the significance level of the results was considered at least $P < 0.05$.

Results

SOD level assessment

The results showed that the level of SOD in rats that received omeprazole increased significantly

compared to rats in the control group and rats that received normal saline. This increase was also observed in the rats that received *M. chamomilla* extract, but the increase was less than the group receiving omeprazole. Finally, it was observed that

the level of SOD in the rats that received the *M. chamomilla* extract with zinc nanoparticle was greatly increased, so that this increase was higher than the group receiving omeprazole ($p < 0.05$) (Figure 1).

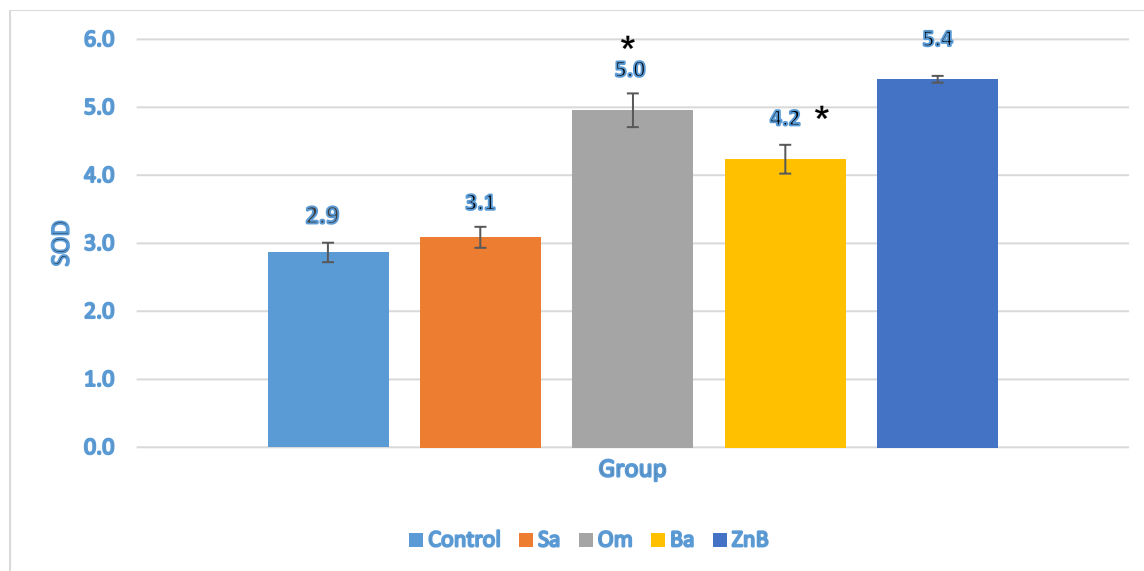


Figure 1: Changes in SOD level of gastric in rats. Control group (Control), Receiving normal saline (Sa), Receiving omeprazole group (Om), and, Receiving *M. chamomilla* group (Ba), Receiving *M. chamomilla* extract with zinc nanoparticles group (ZnB) the values are shown as mean \pm S.E.M.* ($p < 0.05$).

MDA level assessment

The results showed that the level of MDA in the rats that received omeprazole was significantly reduced compared to the rats in the control group. This reduction was also observed in the rats that received the *M. chamomilla* extract, but the reduction rate was lower compared to the omeprazole group. Finally, it was observed that the

level of MDA in the rats that received the *M. chamomilla* extract with nanoparticle was greatly reduced, so that this reduction was more than the group receiving omeprazole. But the difference in the reduction level of these two groups was not significant. ($p < 0.05$) (Figure 2).

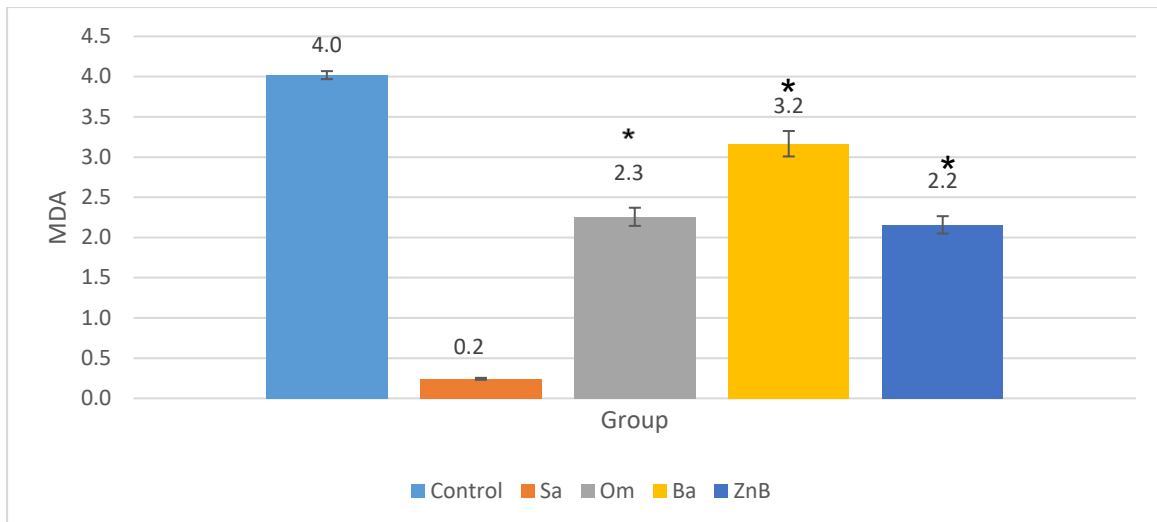


Figure 2: Changes in MDA level of gastric in rats. Control group (Control), Receiving normal saline (Sa), Receiving omeprazole group (Om), and , Receiving *M. chamomilla* group (Ba), Receiving *M. chamomilla* extract with zinc nanoparticles group (ZnB) the values are shown as mean ± S.E.M.* (p<0.05).

Table 1. Changes in MDA level of gastric in rats

	Control	Sa	Om	Ba	ZnB
SOD	2.8 ± 0.1	3.1 ± 0.05	4.9 ± 0.13	4.2 ± 0.06	5.4 ± 0.08
MDA	4 ± 0.13	0.2 ± 0.04	2.3 ± 0.08	3.2 ± 0.05	2.2 ± 0.19

INU level assessment

The results showed that the level of INU decreased in three groups receiving omeprazole, the group receiving *M. chamomilla* alone, and the group receiving *M. chamomilla* extract with zinc nanoparticles. The decrease in the group receiving *M. chamomilla* alone was significantly lower than the other two

groups (p<0.05). While the reduction in the group receiving *M. chamomilla* extract with zinc nanoparticle and the group receiving omeprazole drug was the same. All three groups showed a severe decrease compared to the control group (p<0.05) (Figure 3).

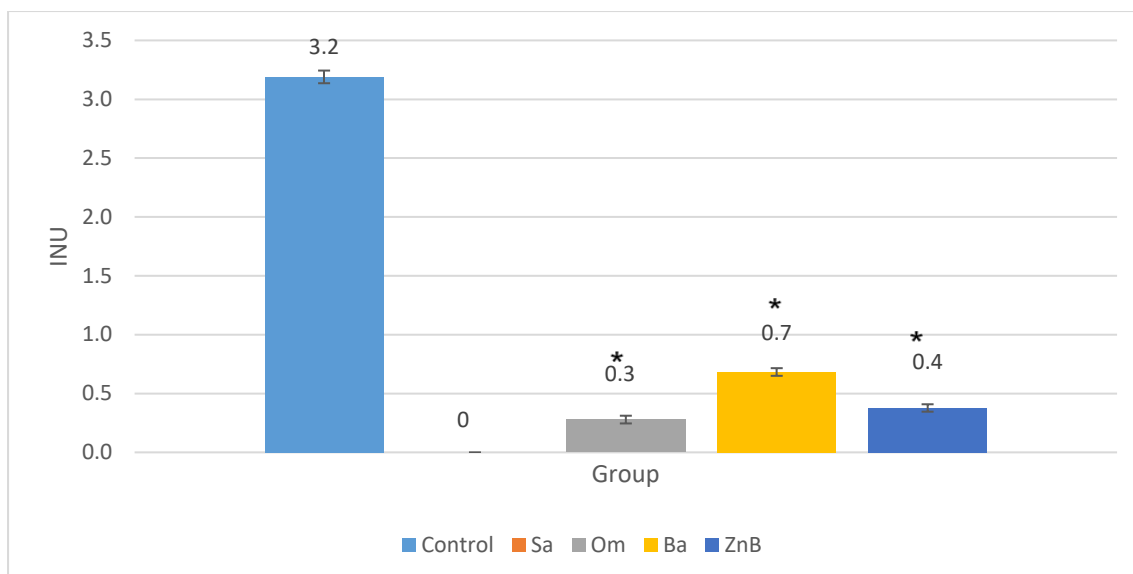


Figure 3: Changes in INU level of gastric in rats. Control group (Control), Receiving normal saline (Sa), Receiving omeprazole group (Om), and , Receiving *M. chamomilla* group (Ba), Receiving *M. chamomilla* extract with zinc nanoparticles group(ZnB) the values are shown as mean \pm S.E.M.* ($p < 0.05$).

IU level assessment

The results showed that the level of IU increased in three groups receiving omeprazole, the group receiving *M. chamomilla* alone, and the group receiving *M. chamomilla* extract with zinc nanoparticles. The increase in the group receiving *M. chamomilla* alone was significantly lower than

the group receiving omeprazole ($p < 0.05$). While the increase in the group receiving *M. chamomilla* extract with zinc nanoparticles was lower than the group receiving omeprazole, but this difference was not significant in the two groups (Figure 4).

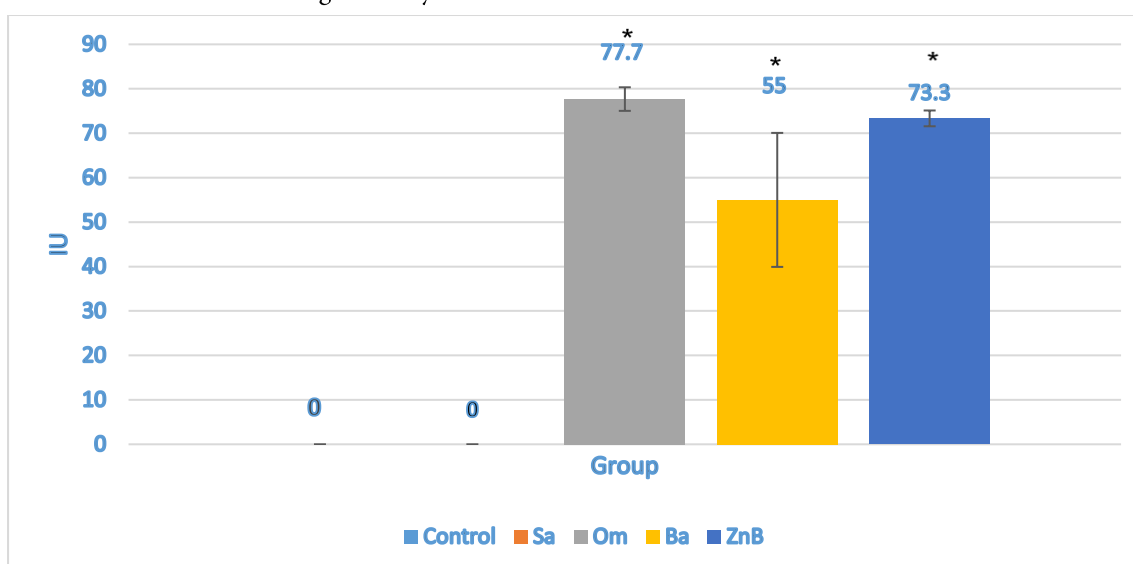


Figure 4: Changes in IU level of gastric in rats. Control group (Control), Receiving normal saline group (Sa), Receiving omeprazole group (Om), and , Receiving *M. chamomilla* group (Ba), Receiving *M. chamomilla* extract with zinc nanoparticles group(ZnB) the values are shown as mean \pm S.E.M.* ($p < 0.05$).

Table (2). Changes in IU level of gastric in rats

	Control	Sa	Om	Ba	ZnB
Iu	0	0	77.6 ± 2.6	55 ± 15.1	73.3 ± 1.7
Inu	3.2 ± 0.05	0	0.3 ± 0.03	0.7 ± 0.03	0.4 ± 0.03

Discussion

The present study was conducted with the aim of determining the protective effect of *M. chamomilla* extract with zinc nanoparticles on ethanol-induced gastric injury in rats. Therefore, we investigated the effects of *M. chamomilla* extract with zinc nanoparticles on gastric mucosal lesions as well as some oxidant and antioxidant parameters in order to at least partly explain the protective effect mechanism of *M. chamomilla* extract with zinc nanoparticles.

The mechanism of gastric ulceration by ethanol can be related to the reduction of gastric mucosal content, damage to mucosal blood flow, and damage to mucosal cells in the pathogenesis of gastric lesions. Furthermore, ethanol-induced gastric mucosal damage is associated with excessive production of ROS, leading to increased lipid peroxidation. Increased lipid peroxidation and ROS lead to significant changes in cellular levels and cause membrane damage, cell death, epithelial desquamation and erosion. [35] Considering that *M. chamomilla* extract contains phenolic derivatives and flavonoids, this plant can have an effective effect on gastric ulcer because it has been shown that the intraperitoneal administration of flavonoid decreased the volume of gastric acid and increased gastric pH. Therefore, the presence of flavonoid content in the *M. chamomilla* extract may partially play a role in wound healing due to its anti-secretory and cell protective activities. [36] In the study of Cemek et al. (2007), it was shown that *M. chamomilla* extract prevents the formation of ethanol-induced gastric injury, and also reduces lipid peroxidation and strengthens antioxidant

defense systems. [37] Another study conducted by Karbalay-Doust and Noorafshan in 2009 showed that oral administration of *M. chamomilla* extract at a dose of 400 mg/kg can be effective in preventing gastric ulcers in rats and it does not cause toxic effects in doses up to 5000 mg/kg. [38] Therefore, *M. chamomilla* can prevent experimental gastric ulcer in rats.

The use of nano-sized drug delivery systems (nanoparticles) for the delivery of herbal medicines has a potential future to increase the activity and overcome the problems associated with herbal medicines. Therefore, the integration of nanocarriers as a novel drug delivery systems in the traditional medicine system is necessary to deal with chronic diseases. In other words, the use of "herbal drugs" in nanocarriers increases its potential for the treatment of various chronic diseases and health benefits [39]. Zinc nanoparticles, which are non-toxic and biocompatible, have been used as drug carriers. Compared to silver nanoparticles, zinc nanoparticles have advantages such as low production cost, white appearance. Studies by Hassani et al. in 2009 showed that the use of nanoparticles as drug carriers holds promise for the targeted delivery of drugs to ulcerated mucosal areas in the stomach. [40] Green synthesis of nanoparticles has many potential applications in environmental and biomedical fields. The goal of green synthesis is especially to reduce the use of toxic chemicals. Several types of natural extracts (eg, biological components such as plants, bacteria, fungi, yeast, and plant extracts) have been used as efficient sources for the synthesis and/or manufacture of

materials. Among them, plant extracts have been proven to have high efficiency as stabilizing and reducing agents for the synthesis of controlled substances.[41]

Therefore, in this study, we used zinc nanoparticles to transfer *M. chamomilla* extract, and the results of this study showed that the therapeutic effects of this extract will be much greater when nanoparticles are used to transfer it .

To show the great effect of *M. chamomilla* extract with zinc nanoparticles in this study, except two treatment groups that received chamomile extract alone and also the group that received *M. chamomilla* extract with nanoparticles, another treatment group in It was considered and for the treatment of gastric ulcer in this group, Omeprazole drug, which is one of the common drugs used in the treatment of gastric ulcer, was used. An important part of the antiulcer effect of drugs such as omeprazole and lansoprazole is related to their ability to reduce the level of myeloperoxidase and malondialdehyde and inhibit the oxidative damage of the gastric mucosa[42].

Lipid peroxidation has been reported as an important factor in the loss of cell function under oxidative stress conditions. MDA is an indicator of lipid peroxidation and its level increases in tissues when exposed to oxidative stress. MDA production has been reported to increase after ethanol-induced gastric tissue damage.[43] Antioxidant enzymes such as superoxide dismutase (SOD) are proteins that play a role in the catalytic modification of reactive oxygen species and their by-products to stable non-toxic molecules. Hence, they are the most important defense mechanism against cellular damage caused by oxidative stress.[44] In this study, it was observed that zinc nanoparticles containing *M. chamomilla* extract reduced the level of gastric mucosa MDA even slightly more than omeprazole. Although this reduction was not significant compared to the omeprazole group, but considering that herbal compounds do not have the disadvantages of chemical compounds, it can be

concluded that zinc nanoparticles containing *M. chamomilla* extract can be considered a suitable alternative to chemical drugs used to treat stomach ulcers. This is if zinc nanoparticles containing *M. chamomilla* extract significantly increased the level of SOD more than the group receiving omeprazole.

In the present study, oral administration of ethanol produced the expected mucosal lesions in the stomach of rats. On the other hand, treatment with *M. chamomilla* extract with zinc nanoparticles or Omeprazole significantly reduced the percentage of lesions. Therefore, the ability of *M. chamomilla* extract with zinc nanoparticles to increase the antioxidant power of gastric mucosa can play an important role in preventing gastric ulcer caused by ethanol. It seems that the effect of this extract in inhibiting lipid peroxidation and reducing the production of malondialdehyde in the gastric mucosa plays the most important role in preventing gastric ulcer caused by ethanol. Other studies also show the antioxidant effect of *M. chamomilla* extract.[37,45]

Conclusion

According to all the discussed materials, it can be concluded that the effect of zinc nanoparticles containing *M. chamomilla* extract in the treatment of ethanol-induced gastric injury occurs by weakening aggressive and damaging factors such as reducing the production of free radicals and increasing antioxidant compounds.

Conflict of Interest

The authors declared no conflicts of interest.

Funding

None.

Reference

1. M. Rajilic-Stojanovic, C. Figueiredo, A. Smet, R. Hansen, J. Kupcinkas, T. Rokkas, L. Andersen, J.C. Machado, G. Ianiro, A. Gasbarrini, M. Leja, J.P. Gisbert, G.L. Hold, Systematic review: gastric microbiota in health and disease,

- Aliment. Pharmacol. Ther. 51 (2020) 582–602. <https://doi.org/10.1111/apt.15650>.
- Nadeem H, Nawaz A, Nawaz A, Shams K, Mubarak B. Frequency of Helicobacter Pylori Infections and Its Associated Risk Factors in Patients Attending Tertiary Care Hospital of Bhakkar, Pakistan. *Advancements in Life Sciences*. 2022; 4; 9(3):323-7.
 - Qasim Alkafajy, S. A. Effect of Ibuprofen, Ponstan and Panadol oral suspensions on the gastrointestinal mucosal layer in mice. *Caspian Journal of Environmental Sciences*, 2022; 20(3): 539-544. doi: [10.22124/cjes.2022.5687](https://doi.org/10.22124/cjes.2022.5687)
 - M.E. Balogun, J.O. Oji, E.E. Besong, A.A. Ajah, E.M. Michael, Anti-ulcer activity of aqueous leaf extract of *Nauclea latifolia* (rubiacae) on indomethacin-induced gastric ulcer in rats, *African J. Biotechnol.* 12 (2013) 5080–5086. <https://doi.org/10.5897/ajb2013.12788>.
 - L. L., T. K., T. A., Gastric Mucosal Defense and Cytoprotection: Bench to Bedside, *Gastroenterology*. 135 (2008) 41–60. <http://ovidsp.ovid.com/ovidweb.cgi?T=JS&PAGE=reference&D=emed8&NEWS=N&AN=2008311506>.
 - K.R. DeVault, N.J. Talley, Insights into the future of gastric acid suppression, *Nat. Rev. Gastroenterol. Hepatol.* 6 (2009) 524–532. <https://doi.org/10.1038/nrgastro.2009.125>.
 - A. Franke, S. Teyssen, M. V. Singer, Alcohol-related diseases of the esophagus and stomach, *Dig. Dis.* 23 (2006) 204–213. <https://doi.org/10.1159/000090167>.
 - I. Szelenyi, K. Brune, Possible role of oxygen free radicals in ethanol-induced gastric mucosal damage in rats, *Dig. Dis. Sci.* 33 (1988) 865–871. <https://doi.org/10.1007/BF01550977>.
 - F. Zhang, L. Wang, J.J. Wang, P.F. Luo, X.T. Wang, Z.F. Xia, The caspase-1 inhibitor AC-YVAD-CMK attenuates acute gastric injury in mice: Involvement of silencing NLRP3 inflammasome activities, *Sci. Rep.* 6 (2016). <https://doi.org/10.1038/srep24166>.
 - M.S. Shin, J. Lee, J.W. Lee, S.H. Park, I.K. Lee, J.A. Choi, J.S. Lee, K.S. Kang, Anti-inflammatory effect of artemisia argyi on ethanol-induced gastric ulcer: Analytical, in vitro and in vivo studies for the identification of action mechanism and active compounds, *Plants*. 10 (2021) 1–13. <https://doi.org/10.3390/plants10020332>.
 - C.A. Hiruma-Lima, J.S. Gracioso, W. Toma, A.B. Almeida, A.C. Paula, D.S.B. Brasil, A.H. Muller, A.R.M. Souza Brito, A.R.M. Souza Brito, Gastroprotective effect of aparisthman, a diterpene isolated from *Aparisthmium cordatum*, on experimental gastric ulcer models in rats and mice, *Phytomedicine*. 8 (2001) 94–100. <https://doi.org/10.1078/0944-7113-00017>.
 - S.H. Lee, Y. Ding, X.T. Yan, Y.H. Kim, H.D. Jang, Scopoletin and scopolin isolated from *Artemisia iwayomogi* suppress differentiation of osteoclastic macrophage RAW 264.7 cells by scavenging reactive oxygen species, *J. Nat. Prod.* 76 (2013) 615–620. <https://doi.org/10.1021/np300824h>.
 - C. Yun, Y. Jung, W. Chun, B. Yang, J. Ryu, C. Lim, J.H. Kim, H. Kim, S.I. Cho, Anti-Inflammatory Effects of Artemisia Leaf Extract in Mice with Contact Dermatitis in Vitro and in Vivo, *Mediators Inflamm.* 2016 (2016). <https://doi.org/10.1155/2016/8027537>.
 - N. Amat, H. Upur, B. Blažeković, In vivo hepatoprotective activity of the aqueous extract of *Artemisia absinthium* L. against

- chemically and immunologically induced liver injuries in mice, *J. Ethnopharmacol.* 131 (2010) 478–484. <https://doi.org/10.1016/j.jep.2010.07.023>.
14. M. Habib, I. Waheed, Evaluation of anti-nociceptive, anti-inflammatory and antipyretic activities of *Artemisia scoparia* hydromethanolic extract, *J. Ethnopharmacol.* 145 (2013) 18–24. <https://doi.org/10.1016/j.jep.2012.10.022>.
 15. J.H. Wang, M.K. Choi, J.W. Shin, S.Y. Hwang, C.G. Son, Antifibrotic effects of *Artemisia capillaris* and *Artemisia iwayomogi* in a carbon tetrachloride-induced chronic hepatic fibrosis animal model, *J. Ethnopharmacol.* 140 (2012) 179–185. <https://doi.org/10.1016/j.jep.2012.01.007>.
 16. A. A., G. L.A., E.J. H., M. P.C., Antioxidant and antitumor activities of *Artemisia campestris* and *Thymelaea hirsuta* from southern Tunisia, *Food Chem. Toxicol.* 49 (2011) 342–347. <http://ovidsp.ovid.com/ovidweb.cgi?T=JS&PAGE=reference&D=emed10&NEWS=N&AN=2011052067>.
 17. S. M., T. A., H. F.B., S. N., B. T., Z. N., Protective effects of *Artemisia campestris* upon fenthion-induced nephrotoxicity in adult rats and their progeny, *Gen. Physiol. Biophys.* 32 (2013) 577–588. http://www.embase.com/search/results?subaction=viewrecord&from=export&id=L372329473%0Ahttp://dx.doi.org/10.4149/gpb_2013047.
 18. H.A.A. Twaij, A.A. Al-Badr, Hypoglycemic activity of *Artemisia herba alba*, *J. Ethnopharmacol.* 24 (1988) 123–126. [https://doi.org/10.1016/0378-8741\(88\)90143-2](https://doi.org/10.1016/0378-8741(88)90143-2).
 19. W.H. El-Tantawy, Biochemical effects, hypolipidemic and anti-inflammatory activities of *Artemisia vulgaris* extract in hypercholesterolemic rats, *J. Clin. Biochem. Nutr.* 57 (2015) 33–38. <https://doi.org/10.3164/jcbn.14-141>.
 20. D. Jeong, Y.S. Yi, G.H. Sung, W.S. Yang, J.G. Park, K. Yoon, D.H. Yoon, C. Song, Y. Lee, M.H. Rhee, T.W. Kim, J.H. Kim, J.Y. Cho, Anti-inflammatory activities and mechanisms of *Artemisia asiatica* ethanol extract, *J. Ethnopharmacol.* 152 (2014) 487–496. <https://doi.org/10.1016/j.jep.2014.01.030>.
 21. J.-S. Park, O.-S. Bang, J. Kim, Screening of Stat3 inhibitory effects of Korean herbal medicines in the A549 human lung cancer cell line, *Integr. Med. Res.* 3 (2014) 67–73. <https://doi.org/10.1016/j.imr.2013.10.004>.
 22. A.M. Zimmermann-Klemd, J.K. Reinhardt, A. Morath, W.W. Schamel, P. Steinberger, J. Leitner, R. Huber, M. Hamburger, C. Gründemann, Immunosuppressive Activity of *Artemisia argyi* Extract and Isolated Compounds, *Front. Pharmacol.* 11 (2020). <https://doi.org/10.3389/fphar.2020.00402>.
 23. D.E. Kim, K. jin Min, M.J. Kim, S.H. Kim, T.K. Kwon, Hispidulin inhibits mast cell-mediated allergic inflammation through down-regulation of histamine release and inflammatory cytokines, *Molecules.* 24 (2019). <https://doi.org/10.3390/molecules24112131>.
 24. T. Dvir, B.P. Timko, D.S. Kohane, R. Langer, Nanotechnological Strategies for Engineering Complex Tissues, *Nano-Enabled Med. Appl.* (2020) 351–382. <https://doi.org/10.1201/9780429399039-12>.
 25. S.E. McNeil, Unique benefits of nanotechnology to drug delivery and diagnostics., *Methods Mol. Biol.* 697

- (2011) 3–8. https://doi.org/10.1007/978-1-60327-198-1_1.
26. D.A. La Van, D.M. Lynn, R. Langer, Moving smaller in drug discovery and delivery, *Nat. Rev. Drug Discov.* 1 (2002) 77–84. <https://doi.org/10.1038/nrd707>.
27. F. Léonard, A.A. Talin, Electrical contacts to one- and two-dimensional nanomaterials, *Nat. Nanotechnol.* 6 (2011) 773–783. <https://doi.org/10.1038/nnano.2011.196>.
28. J. Das, M. Paul Das, P. Velusamy, *Sesbania grandiflora* leaf extract mediated green synthesis of antibacterial silver nanoparticles against selected human pathogens, *Spectrochim. Acta - Part A Mol. Biomol. Spectrosc.* 104 (2013) 265–270. <https://doi.org/10.1016/j.saa.2012.11.075>.
29. A.K. Mittal, Y. Chisti, U.C. Banerjee, Synthesis of metallic nanoparticles using plant extracts, *Biotechnol. Adv.* 31 (2013) 346–356. <https://doi.org/10.1016/j.biotechadv.2013.01.003>.
30. S. Hemmati, A. Rashtiani, M.M. Zangeneh, P. Mohammadi, A. Zangeneh, H. Veisi, Green synthesis and characterization of silver nanoparticles using *Fritillaria* flower extract and their antibacterial activity against some human pathogens, *Polyhedron.* 158 (2019) 8–14. <https://doi.org/10.1016/j.poly.2018.10.049>.
31. H. Ohkawa, N. Ohishi, K. Yagi, Assay for lipid peroxides in animal tissues by thiobarbituric acid reaction, *Anal. Biochem.* 95 (1979) 351–358. [https://doi.org/10.1016/0003-2697\(79\)90738-3](https://doi.org/10.1016/0003-2697(79)90738-3).
32. M. Nishikimi, N. Appaji Rao, K. Yagi, The occurrence of superoxide anion in the reaction of reduced phenazine methosulfate and molecular oxygen, *Biochem. Biophys. Res. Commun.* 46 (1972) 849–854. [https://doi.org/10.1016/S0006-291X\(72\)80218-3](https://doi.org/10.1016/S0006-291X(72)80218-3).
33. P.A. Nwafor, F.K. Okwuasaba, L.G. Binda, Antidiarrhoeal and antiulcerogenic effects of methanolic extract of *Asparagus pubescens* root in rats, *J. Ethnopharmacol.* 72 (2000) 421–427. [https://doi.org/10.1016/S0378-8741\(00\)00261-0](https://doi.org/10.1016/S0378-8741(00)00261-0).
34. Z. Rahman, D.K. Dwivedi, G.B. Jena, Ethanol-induced gastric ulcer in rats and intervention of tert-butylhydroquinone: Involvement of Nrf2/HO-1 signalling pathway, *Hum. Exp. Toxicol.* 39 (2020) 547–562. <https://doi.org/10.1177/0960327119895559>.
35. B. Al-Dabbagh, I.A. Elhaty, M. Elhaw, C. Murali, A. Al Mansoori, B. Awad, A. Amin, Antioxidant and anticancer activities of chamomile (*Matricaria recutita* L.), *BMC Res. Notes.* 12 (2019). <https://doi.org/10.1186/s13104-018-3960-y>.
36. M. Cemek, E. Yilmaz, M.E. Büyükkuroğlu, Protective effect of *Matricaria chamomilla* on ethanol-induced acute gastric mucosal injury in rats, *Pharm. Biol.* 48 (2010) 757–763. <https://doi.org/10.3109/13880200903296147>.
37. S. Karbalay-Doust, A. Noorafshan, Antiulcerogenic effects of *Matricaria chamomilla* extract in experimental gastric ulcer in mice, *Iran. J. Med. Sci.* 34 (2009) 198–203.
38. V. Mamillapalli, A.M. Atmakuri, P. Khantamneni, Nanoparticles for herbal extracts, *Asian J. Pharm.* 10 (2016) S54–S60.

39. S. Hassani, Y. Pellequer, A. Lamprecht, Selective Adhesion of Nanoparticles to Inflamed Tissue in Gastric Ulcers, *Pharm. Res.* 26 (2009) 1285–1285. <https://doi.org/10.1007/s11095-009-9872-8>.
40. S. Jadoun, R. Arif, N.K. Jangid, R.K. Meena, Green synthesis of nanoparticles using plant extracts: a review, *Environ. Chem. Lett.* 19 (2021) 355–374. <https://doi.org/10.1007/s10311-020-01074-x>.
41. A.S. Patil, A.D. Singh, U.B. Mahajan, C.R. Patil, S. Ojha, S.N. Goyal, Protective effect of omeprazole and lansoprazole on β -receptor stimulated myocardial infarction in Wistar rats, *Mol. Cell. Biochem.* 456 (2019) 105–113. <https://doi.org/10.1007/s11010-019-03494-y>.
42. E. Cadirci, H. Suleyman, H. Aksoy, Z. Halici, U. Ozgen, A. Koc, N. Ozturk, Effects of *Onosma armeniacum* root extract on ethanol-induced oxidative stress in stomach tissue of rats, *Chem. Biol. Interact.* 170 (2007) 40–48. <https://doi.org/10.1016/j.cbi.2007.06.040>.
43. Yin., B. Robyn., N. Alycia., H. Siegfired., Superoxide dismutases: Dual roles in controlling ROS damage and regulating ROS signaling, *J. Cell Biol.* 217 (2018) 1915–1928. <http://www.embase.com/search/results?subaction=viewrecord&from=export&id=L622496320%0Ahttp://dx.doi.org/10.1083/jcb.201708007>.
44. yavar Mahmoodzadeh, M. Mazani, L. Rezagholizadeh, A. Abbaspour, E. Zabihi, P. Pourmohammad, Effect of *Tanacetum parthenium* Extract on Total Antioxidant Capacity of Tissues Damaged by Carbon Tetrachloride in Rats, *J. Ardabil Univ. Med. Sci.* 16 (2017).

<http://jarums.arums.ac.ir/article-1-1246-en.html>.