Ilam University of Medical Sciences

Plant Biotechnology Persa

Online ISSN: 2676-7414

Homepage: https://pbp.medilam.ac.ir

Combined Extract of *Spermacoce radiata* (DC.) Hiern and *Hypselodelphys poggeana* (K.Schum.) Milne-Redh leaves (CEESH) confer Hepatoprotection in Rat Induced Benign Prostatic Hyperplasia

Robert Ikechukwu Uroko[1], Paul Chukwuemaka Nweje-Anyalowu[2], Chinomso Friday Aaron[3], Charles Nnanna Chukwu[4]

[1]Department of Biochemistry, College of Natural Sciences, Michael Okpara University of Agriculture, Umudike, Abia State, Nigeria. E-mail: ir.uroko@mouau.edu.ng

[2]Department of Biochemistry, Faculty of Science, Clifford University, Owerrinta, Abia State, Nigeria. E-mail: lukaspod@yahoo.com

[3]Department of Biochemistry, Faculty of Biological and Physical Sciences, Abia State University, Uturu, Nigeria. E-mail: aaron.friday@absu.edu.ng

[4]Department of Biochemistry, College of Natural Sciences, Michael Okpara University of Agriculture, Umudike, Abia State, Nigeria. E-mail: charles_chukwu@uniport.edu.ng

Corresponding Author, Department of Biochemistry, College of Natural Sciences, Michael Okpara University of Agriculture, Umudike, Abia State, Nigeria. E-mail: ir.uroko@mouau.edu.ng

Article Info

Article type:
Research Article

Article History:
Received: 17 March 2022
Received in revised form: 29 April 2022
Accepted: 07 May 2022
Published online: 10 May 2022

Keywords:
Benign prostatic hyperplasia, Hepatic enzymes, Hepatoprotection, *Hypselodelphys poggeana*, Liver histology, *Spermacoce radiata*

Abstract

Objective: The combined extract of Spermacoce radiata and Hypselodelphys poggeana leaves has been shown to be a potent therapeutic agent against benign prostatic hyperplasia and it is used extensively for BPH and other diseases by local traditional medicine practitioners without any evaluation of its toxicity effects on liver and other vital organs in the body. The study evaluated the hepatoprotective effects of a combined extract of S. radiata and H. poggeana (CEESH) on rats with prostate enlargement (BPH).

Material and Methods: The study had five groups of rats (n = 6), with groups 1 and 2 being the normal and BPH controls, respectively. Groups 3, 4 and 5 were the BPH rats administered Finasteride, 300 and 600 mg/kg CEESH, respectively. Prostate enlargement was induced in the rat by the subcutaneous administration of testosterone injection (5 mg/kg/day for 28 days), while Finasteride and CEESH were respectively administered to the rats orally as therapeutic agents.

Results: Prostate enlargement in the rats elevated AST, ALT and ALP activities in BPH control coupled with a significant rise in the serum bilirubin levels compared to the normal control. The total protein and its constituents (including albumin and globulin) declined significantly in the BPH control compared to the normal control. Administration of CEESH to the prostate enlarged rats lowered AST, ALT, and ALP activities in groups 4–5 rats significantly ($P<0.05$) compared to BPH control. Besides, the CEESH treated had elevated total protein (including albumin and globulin) levels compared to the BPH control. The high bilirubin levels in the BPH control were significantly diminished in the rats treated with CEESH. No alterations in the liver micrographs of the BPH control and CEESH administered rats were observed.

Conclusion: These findings showed that CEESH confers hepatoprotection in BPH induced rats and could be used to manage BPH and other hepatic disorders.

*P*lant Biotechnology Persa 2022; 4(1): 68-78. DOI: 10.52547/pbp.4.1.10

© The Author(s). Publisher: Ilam University of Medical Sciences

How to cite: Uroko RI, Nweje-Anyalowu PCH, Aaron CHF, Chukwu CHN. Combined Extract of *Spermacoce radiate* (DC.) Hiern and *Hypselodelphys poggeana* (K.Schum.) Milne-Redh leaves (CEESH) confer Hepatoprotection in Rat Induced Benign Prostatic Hyperplasia. Plant Biotechnology Persa 2022; 4(1): 68-78.

[Downloaded from pbp.medilam.ac.ir on 2026-11-25]

Introduction

Benign prostatic hyperplasia (BPH) is a urinary problem commonly occurring in ageing men due to the imbalance in the testicular androgen levels, which has been reported to be closely associated with lifestyles, complications nutritional behaviours and metabolic syndrome [1, 2]. Prostate glands are enlarged in patients with BPH because of the elevated epithelial and stromal cell counts [3]. It is responsible for the obstruction of urinary flow, incomplete emptying of urine, and urinary tract and bladder disorder in ageing men [4, 5]. Advanced stage of BPH could cause male infertility, impaired urinary excretion and even death and it has been reported that BPH development and progression in ageing men is promoted by dyslipidaemia, chronic alcohol consumption, obesity, compromised immune system, inflammation and lack of physical exercise [6]. BPH is mostly treated by lifestyle adjustment, diets, surgery and chemotherapeutic agents, including Finasteride with varying degrees of recovery, prolonged use of chemotherapeutic agents could cause adverse reactions in the body like impaired fertility, organ damage and metabolic syndromes as earlier reported by Gormley *et al.* [7]. Treatment options for BPH aim to either relax the bladder or reduce the prostate size and this is done using drugs such as alpha-blockers (tamulosin), 5-alpha reductase inhibitors (Finasteride), combined drug therapy and Tadalafil (Cialis) which are usually associated with varying degrees of adverse effects l8]. The high cost and undesirable outcome of most chemotherapeutic agents coupled with the adverse health effects associated with many chemotherapeutic agents against BPH have necessitated a search for safer, cheaper, more potent and readily available therapeutic agents against BPH, with medicinal plants as viable alternatives [9].

Spermacoce radiata (DC.) Sieber ex Hiern is a potent medicinal plant from the Rubiaceae family commonly used in various herbal formulations to treat bacterial and venereal diseases. *Spermacoce radiata* is distributed across tropical and subtropical countries [10]. *Spermacoce* species contain appreciable amounts of alkaloids, flavonoids, and terpenoids, responsible for their pharmacological activities such as antimalarial, antimicrobial, antitumour, anti-oxidative stress, anti-ulcer and antidiabetic activities [11, 12]. It is used for general healing, genital stimulation, and antidepressants [13]. *Hypselodelphys poggeana* (K. Schum.) Milne-Redh is a potent herbal plant for treating common tropical diseases and medical conditions like BPH and fertility disorders. It belongs to the *Marantaceae* family distributed across West Africa, including Nigeria. The plant extract plays a significant role in herbal formations for general healing, genital stimulation, and an antidepressant agent [13]. The combined leaf extract of *S. radiata* and *H. poggeana* possesses anti-benign prostatic hyperplasia properties, including renal protective and anti-dyslipidaemia effects [14]. We designed this study to evaluate the hepatoprotective potentials of a combined leaf extract of *S. radiata* and *H. poggeana* (CEESH) in prostate enlarged rats.

Materials and Methods

Plant materials

The plant samples were *S. radiata,* and *H. poggeana* leaves sourced from botanical gardens and forests within Umudike, Abia State. A plant taxonomist at the Department of Forestry Herbarium Unit of our institution (MOUAU) identified the plants as *S. radiata* (DC.) Hiern and *H. poggeana* (K. Schum.) Milne-Redh, respectively with voucher specimen numbers: (*MOUAU/DF/BCH/03712*) and (*MOUAU/DF/BCH/03713*) for a referral. The plants were separated from debris, cleaned under running tap water, and dried under shade until they attained a constant dry weight. The dry plants' leaves were ground with a mechanised grinder and stored in clean, dry containers. After which, 300 g of the pulverised *H. poggeana* leaves and 300 g of *S. radiata* leaves (1:1, g/g) were weighed into a clean, sterile container and extracted with 1.6 L of analytical grade ethanol for three days (72 h) with regular agitation as outlined by Uroko *et al.* (14). The extraction mixture was filtered, the filtrate concentrated, and its percentage yield calculated. The acute toxicity of a combined extract of *H. poggeana* and *S. radiata* (CEESH) has been reported by Uroko *et al.* [14] to be above 5000 mg/kg/day. Thus, there was no need for the acute toxicity study of CEESH in this study.

Experimental animals

The study used 30 albino rats (150 – 160 g body weight), purchased from the College of Veterinary Medicine, MOUAU and allowed to adapt to our animal house for three

[Downloaded from pbp.medilam.ac.ir on 2026-11-25]

weeks. The rats received adequate feed and drinking water throughout the acclimatisation period, after which they were reweighed and selected into five groups (n = 6).

Chemicals and reagents

The testosterone propionate injection and Finasteride were obtained from Health Biotech Ltd, India, and Merck Company, USA. The ethanol was obtained from Sigma Aldrich, United States of America (USA), while the assay kits were from Randox Laboratories, United Kingdom (UK).

Experimental design

The thirty rats were selected into five groups (n = 6) to evaluate the effects of combined *H. poggeana,* and *S. radiata* leaves on the liver function parameters of testosterone propionate injection-induced prostate enlargement in rats. Group 1 rats received 2 ml/kg of olive oil per day for four weeks without administering testosterone propionate injection (normal control); groups 2 – 5 rats were subcutaneously administered testosterone propionate injection (5 mg/kg) per day for four weeks. The group 2 rats were not given any treatment (BPH control). Group 3 rats were administered 5 mg/kg Finasteride/day for four weeks (Finasteride control), whereas groups 4 and 5 rats were administered 300 and 600 mg/kg CEESH/day, respectively, for four weeks. After four weeks, the feed was withdrawn from the rats overnight, anaesthetised, and followed with a collection of blood via cardiac punctures and livers harvested.

Analyses of liver function parameters

The hepatic enzyme (aspartate transaminase (AST), alanine transaminase (ALT) and alkaline phosphatase (ALP) activities and other hepatic indices (serum total protein, serum albumin, serum globulin, total bilirubin and direct bilirubin concentrations) were determined using Randox commercial kits as outlined in their respective commercial kits.

Histological evaluation

The liver samples harvested from the rats were treated and prepared according to standard procedure as outlined by Uroko *et al.* [14].

Statistical analysis

The data from the study were analysed with Statistical Products and Service Solutions (SPSS) version 22 to conduct one-way analysis of variance (ANOVA) and Duncan multiple range comparison test with a statistical significance attained at 95% confidence level ($P < 0.05$).

Results

Effects of CEESH on the AST activities of BPH induced rats

Prostate enlargement in the rats caused a rise in AST activity of the BPH control compared to the normal control (Figure 1). Whereas, treatment of the prostate enlarged rats with Finasteride, 300 and 600 mg/kg CEESH/d caused a significant rise in the AST activities of the groups 3, 4 and 5, respectively, relative to the normal control but significantly ($P<0.05$) reduced compared to the BPH control. Furthermore, treatment of the prostate enlarged rats with 300 and 600 mg/kg CEESH/d, respectively, elicited no significant ($P>0.05$) decline in the AST activities of prostate enlarged rats compared to the prostate enlarged rats treated with Finasteride.

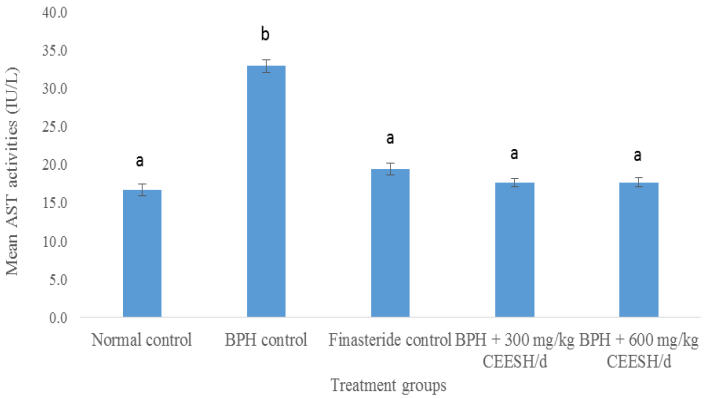

Bars are presented as mean ± standard deviation (n = 6) and bars with different superscripts are significantly different from every paired mean at $P < 0.05$

Fig. 1: *AST activities of prostate enlarged rats treated with CEESH*

Effects of CEESH on the ALT activities of prostate enlarged rats

The ALT activities of the BPH control, Finasteride control, and rats administered 300, and 600 mg/kg CEESH

[Downloaded from pbp.medilam.ac.ir on 2026-11-25]

were significantly raised compared to the normal control. Besides, treatment with Finasteride, 300 and 600 mg/kg CEESH caused a significant decline in ALT activities compared to BPH control. Contrarily, treatment with CEESH had similar effects on ALT activities as the treatment with Finasteride.

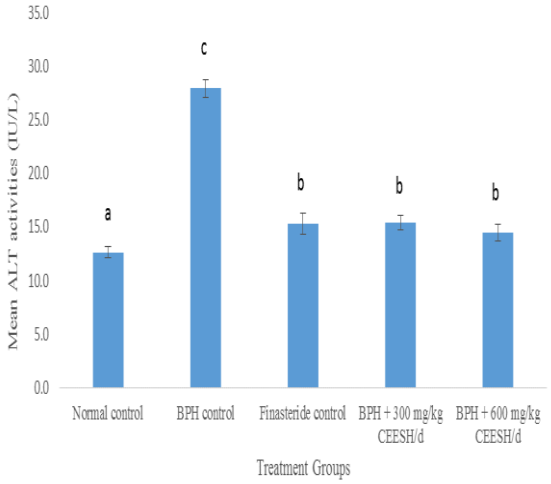

Bars are presented as mean ± standard deviation (n = 6) and bars with different superscripts are significantly different from every paired mean at P < 0.05

Fig. 2: *ALT activities of prostate enlarged rats administered CEESH*

Effects of CEESH on the ALP activities of prostate enlarged rats

The ALP activities of BPH control, Finasteride control, and prostate enlarged rats administered 300 mg/kg CEESH were significantly elevated compared to group 1 healthy rats. On the other hand, administration of 600 mg/kg CEESH of the extract to the rats elicited no significant (P>0.05) rise in the ALP activities comparable to the normal control. Furthermore, rats that received Finasteride, and CEESH, respectively, indicated a significant decline in the ALP activities compared to the BPH control.

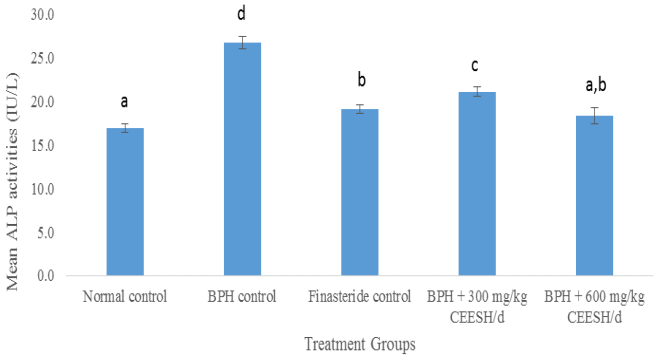

Bars are presented as mean ± standard deviation (n = 6) and bars with different superscripts are significantly different from every paired mean at P < 0.05

Fig. 3: *ALP activities of prostate enlarged rats administered CEESH*

Effects of CEESH on the total protein concentrations of BPH induced rats

There was a marked decline in the total protein concentrations in the BPH control and prostate enlarged rats that received 300 mg/kg CEESH compared to the normal control (Figure 4). The Finasteride control exhibited a decrease in the serum protein concentration, unlike the rats administered 600 mg/kg CEESH/d, which displayed a merely increased serum protein level compared to the normal control. In the Finasteride control, prostate enlarged rats administered 300 and 600 mg/kg CEESH/d had a marked elevated serum protein level than the BPH control. Also, the serum protein level was slightly lowered in the rats administered 300 mg/kg CEESH/d compared to the Finasteride control.

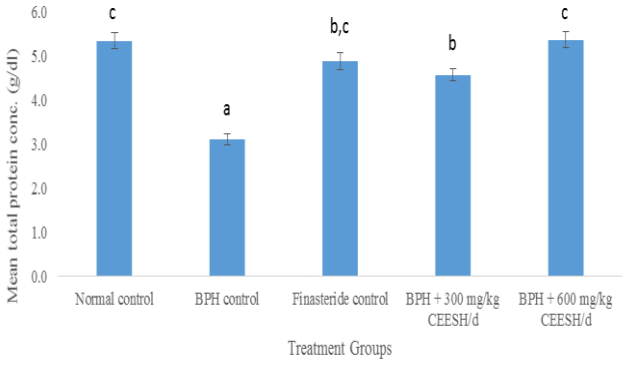

Bars are presented as mean ± standard deviation (n = 6) and bars with different superscripts are significantly different from every paired mean at P < 0.05

Fig. 4: *Concentrations of total protein in prostate enlarged rats administered CEESH*

Effects of CEESH on the serum albumin concentrations of BPH induced rats

[Downloaded from pbp.medilam.ac.ir on 2026-11-25]

The serum albumin concentrations in the BPH control and rats administered 300 mg/kg CEESH displayed a marked decrease compared to normal control (Figure 5). The Finasteride control and rats helped with 600 mg/kg CEES showed a mild decline in the serum albumin levels comparable to the normal control. Asides, the Finasteride control and the rats administered 600 mg/kg CEESH/d displayed a drastic increase in the serum albumin levels relative to the BPH control. There was a mild decrease in the albumin concentration of rats administered 300 mg/kg CEESH compared to the BPH control. Moreover, rats that received 300 mg/kg CEESH had a mild decrease in the albumin concentration, unlike the rats administered 600 mg/kg CEESH exhibited a mild increase in the albumin concentration compared to the Finasteride control.

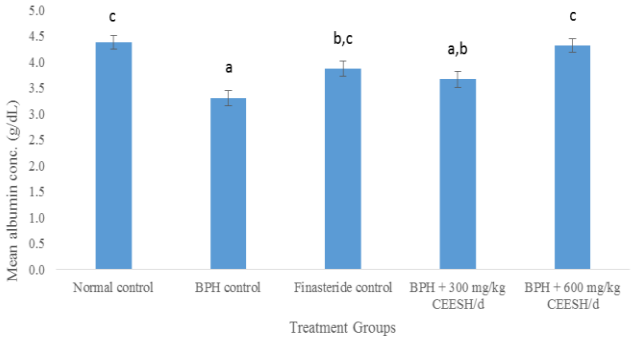

Bars are presented as mean ± standard deviation (n = 6) and bars with different superscripts are significantly different from every paired mean at P < 0.05

Fig. 5: *Albumin levels in prostate enlarged rats administered CEESH*

Impact of CEESH on the serum globulin level of prostate enlarged

The BPH control, Finasteride control, and prostate enlarged rats administered 300 mg/kg CEESH had a marked decline in the serum globulin levels relative to the normal control, respectively (Figure 6). Besides, there was a mild decrease in the serum globulin level in the prostate enlarged rats administered 600 mg/kg CEESH/d compared to the normal control. Also, the serum globulin levels in the Finasteride control and prostate enlarged rats given CEESH were highly increased compared to the normal control. The serum globulin concentration of rats administered 300 mg/kg CEESH was highly decreased, while the serum globulin level of prostate enlarged rats administered 600 mg/kg CEESH was significantly increased compared to the Finasteride control.

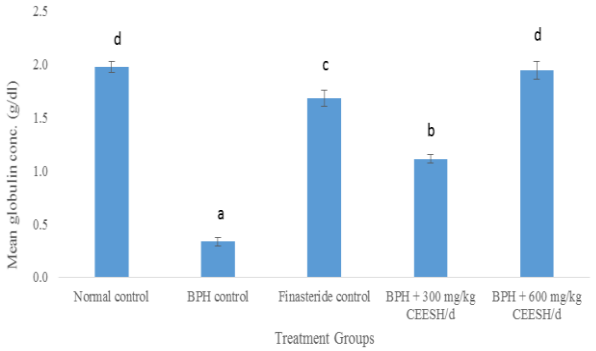

Bars are presented as mean ± standard deviation (n = 6) and bars with different superscripts are significantly different from every paired mean at P < 0.05

Fig. 6: *Serum globulin levels prostate enlarged rats administered CEESH*

Impact of CEESH on the total serum bilirubin concentrations in prostate enlarged rats

The total bilirubin levels in the BPH control, Finasteride control, and prostate enlarged rats administered CEESH were significantly raised compared to the normal control (Figure 7). On the contrary, the serum total bilirubin levels in the Finasteride control and prostate enlarged rats administered CEESH/d decreased significantly compared to the BPH control. Moreover, the prostate enlarged rats administered 600 mg/kg CEESH had reduced considerably total bilirubin levels relative to the Finasteride control and prostate enlarged rats administered 300 mg/kg CEESH, respectively.

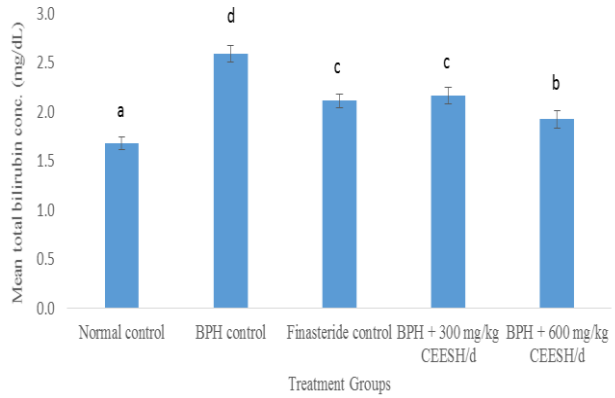

Bars are presented as mean ± standard deviation (n = 6) and bars with different superscripts are significantly different from every paired mean at P < 0.05

Fig. 7: *Total bilirubin levels in prostate enlarged rats administered CEESH*

Effects of CEESH on the direct bilirubin levels prostate enlarged rats

The serum direct bilirubin level in the BPH control was significantly raised compared to the normal control (Figure 8). Contrarily, administration of Finasteride and 300 mg/kg CEESH elicited much relative to the normal control, unlike

[Downloaded from pbp.medilam.ac.ir on 2026-11-25]

the prostate enlarged rats administered 600 mg/kg CEESH that had a mild decrease in the direct bilirubin comparable to the normal control. In contrast, the administration of Finasteride and CEESH caused significant reductions in the direct bilirubin levels relative to the BPH control.

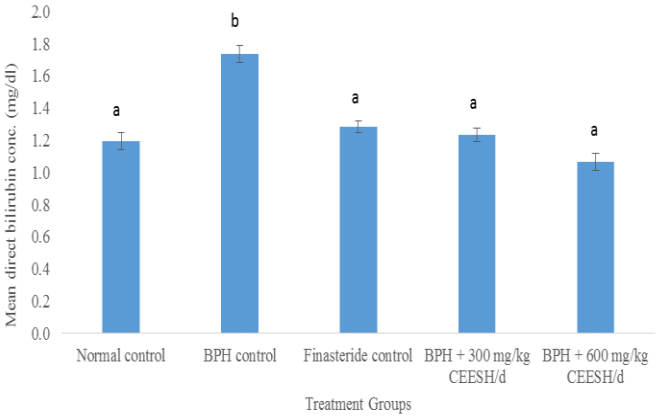

Bars are presented as mean ± standard deviation (n = 6) and bars with different superscripts are significantly different from every paired mean at P < 0.05

Fig. 8: *Direct bilirubin levels in prostate enlarged rats administered CEESH*

Effects of CEESH on the liver histomorphology of BPH induced rats

Fig. 9 depicted the healthy liver of an average laboratory rat (rodent) comprising intact normal hepatic lobules with normal liver cells arranged in interconnecting cords surrounding the central veins. The hepatic sinusoids demarcated hepatic cords and were radially organised around the central veins. Likewise, the liver micrographs from the BPH control (Fig. 10), Finasteride control (Fig. 11), prostate enlarged rats administered 300 mg/kg CEESH (Fig. 12), and 600 mg/kg CEESH (Fig. 13) displayed the normal laboratory rats. In the Figures 9 – 13; the central veins, portal area, hepatic artery and bile ducts were depicted as; V, P, HA, and BD, respectively

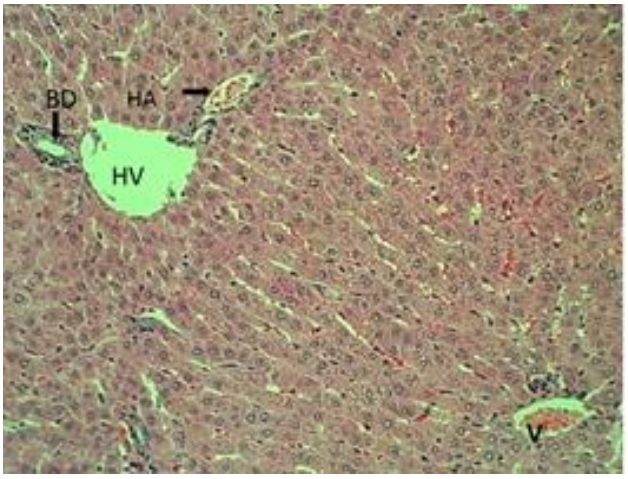

Fig. 9: *Liver photomicrograph of the normal control rat*

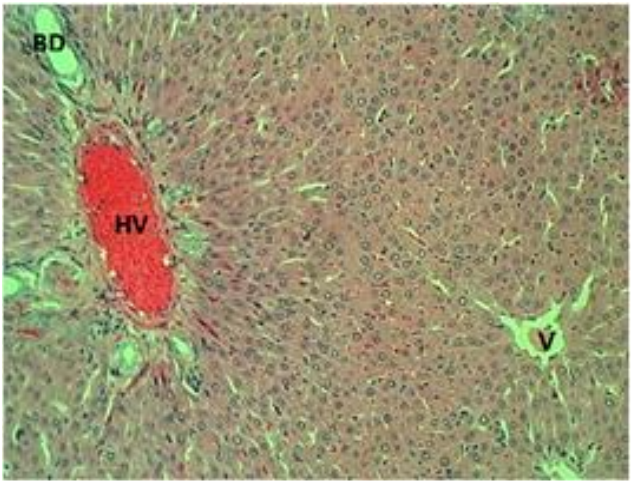

Fig. 10: *Liver photomicrograph of the BPH control rat*

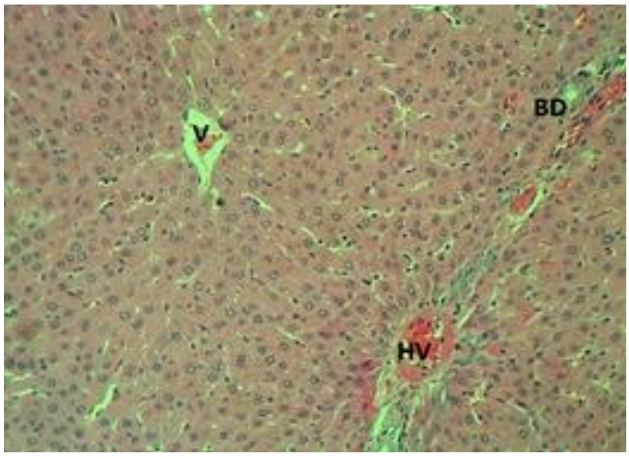

Fig. 11: *Liver Photomicrograph of prostate enlarged rat administered 5 mg/kg of Finasteride*

[Downloaded from pbp.medilam.ac.ir on 2026-11-25]

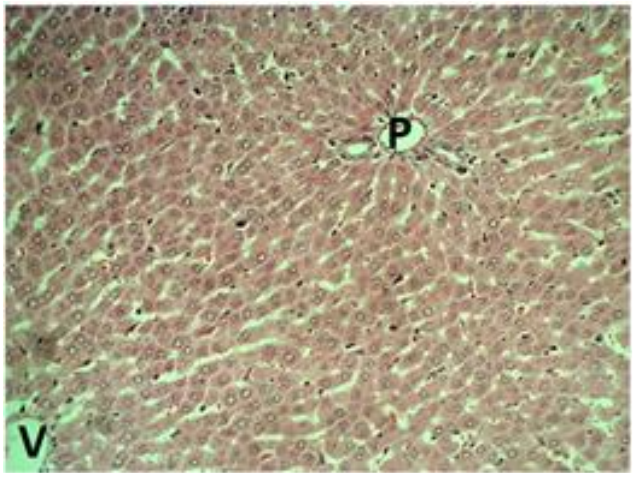

Fig. 12: *Liver Photomicrograph of prostate enlarged rat administered 300 mg/kg CEESH*

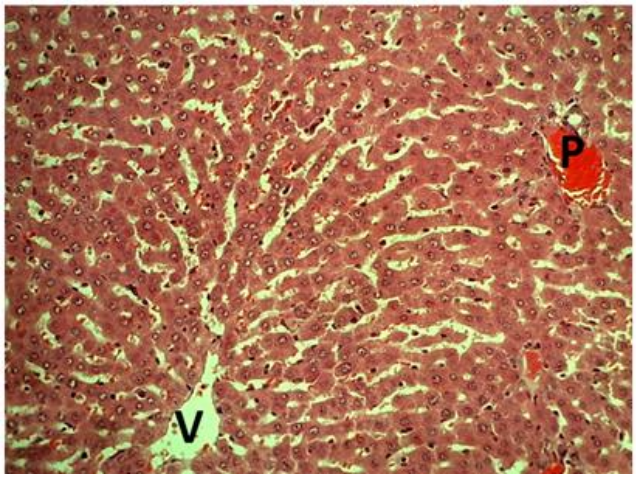

Fig. 13: *Liver Photomicrograph of prostate enlarged rats administered 600 mg/kg CEESH*

DISCUSSION

The AST activity in the group 2 rats, which increased significantly compared to the normal control and administered Finasteride and CEESH, respectively, suggests that the BPH control rats had a hepatic injury which caused leakage of AST to the extrahepatic tissues, which is in line with the previous reports [15, 16]. The elevated AST activity in the BPH control indicates impaired liver functions, which might have affected the proper metabolism of androgenic hormones such as testosterone and dihydrotestosterone involved in the pathogenesis of BPH. Apart from the metabolism of androgenic hormones, it may impair other liver functions such as biosynthesis of macromolecules, biotransformation of xenobiotics and detoxification of waste products. The AST activities in the rats treated with CEESH and Finasteride, respectively, which declined significantly compared to the BPH control, indicated a more intact liver cell membrane, preventing the leakage of AST and other liver contents in the extrahepatic tissues. The low AST activity in the rats treated with CEESH could be attributed to the hepatoprotective effects of CEESH that prevented liver injury in the rats and stabilised other organs like the heart and kidneys, which could have increased the serum AST activity when compromised and agrees with findings of Chukwu *et al.* [17].

The serum ALT activities are a more specific parameter to monitor liver functions than AST activity because of its occurrence in the hepatocytes and how both enzymes leak into the circulating blood when liver cell injury occurs [18]. The elevated ALT activity observed in the prostate enlarged rats without treatment (group 2) relative to the healthy rats (group 1) and rats administered Finasteride and CEESH, respectively, indicated the presence of liver injury, which caused efflux of ALT from hepatocytes. It also suggested impaired liver function in the BPH control and increased health burdens in BPH condition if not given adequate treatment. The elevated ALT activities in rats support the reports of Stocken [19] and Thornburg [15], that there could be high levels of ALT in other abnormal health conditions such as benign and malignant tumours aside from liver injury. Administration of Finasteride and CEESH respectively reversed the elevated ALT activities in the rats drastically compared to the untreated prostate enlarged rats and near the level observed in the healthy rats showing that each of these treatments possesses hepatoprotective properties. The reductions in the ALT activities of the rats administered CEESH showed the hepatoprotective activity of the extract, which aligns with the earlier findings [16], who worked on the effects of ethanol extract of *Cassia sieberiana* leaves on prostate enlarged rats and reported similar results. The significantly increased ALP activities exhibited by the BPH control rats compared to the normal control, Finasteride, and CEESH administered rats, respectively, together with other elevated hepatic enzyme activities in the rats, showed leakage of hepatic enzymes to the extrahepatic environments possibly due to compromised hepatic membrane integrity. On the hand, the significantly reduced ALP activities in the rats treated with Finasteride and 300 mg/kg CEESH/d compared to the BPH control indicated recovery from hepatic injury and restoration of the

[Downloaded from pbp.medilam.ac.ir on 2026-11-25]

hepatocyte membrane integrity near normal, which prevented increased efflux of ALP from the hepatocytes. These showed that the treated rats had more stable liver and improved liver functions comparable to the BPH control. Besides, administration of 600 mg/kg CEESH reduced ALP activities significantly relative to the normal control and suggested that CEESH exhibits effective therapeutic activity at increased doses. The significant reduction in the ALP activities in rats treated with CEESH is evidence of recovery from hepatic injury and further showed that CEESH is a potent hepatoprotectant inconsonant with the report of Amang *et al.* [20].

Total serum protein concentration gives the nutritional status of a liver and its biosynthetic ability to make enough albumin and globulin concentrations required in the body for normal metabolic and physiological functions. Reduced synthesis of either albumin or globulin due to liver injury could result in a low serum protein level. However, it could be caused by intestinal malabsorption in some cases, as earlier suggested by Amang *et al.* [20]. The marked reduction in the total protein level in the BPH control might be due to impaired protein synthesis by the rats' liver cells, which suggests that the rats would not have sufficient concentrations of albumin and globulin needed for the normal biochemical functions. However, the increased serum total protein concentrations observed in the Finasteride and CEESH administered rats suggest more intact hepatocytes with unhindered ability to synthesise proteins and are more likely to survive BPH than the BPH control rats which align with the findings of Tofik *et al.* [21]. Low serum total protein commonly occurs in the body when there is organ injury, including liver and kidney, primarily due to poor intestinal absorption and inflammatory disorders like BPH.

Albumin is a vital component of the total serum protein critical in transporting biomolecules such as chemical messengers, lipids, bilirubin, and other substances like drugs, minerals, and vitamins to their respective action sites and detoxification to maintain optimal biochemical and physiological functions. The reduced albumin level in the BPH control could be attributed to reducing albumin synthesis by the liver cells and increased albumin loss due to impaired liver membrane integrity, resulting in an abnormal lipid profile [21]. The affected rats could not be able to transport excess LDL-cholesterol and bilirubin to liver cells for detoxification. The marked increase in albumin levels observed in the rats administered CEESH, most especially the group that received 600 mg/kg CEESH/d, showed that CEESH promotes albumin synthesis. The CEESH could have caused elevation of the serum albumin level by preventing liver injury, thereby promoting optimum liver functions, protein synthesis and intestinal absorption of albumin in line with the previous report by Tofik *et al.* [21].

Serum globulins are the most crucial part of serum total proteins after albumin is synthesised by liver cells. They mainly serve as immunoglobulins, enzymes, carrier proteins and complements, which usually occur in low concentrations when there is kidney or liver disease. Abnormally elevated serum globulin levels reflect dehydration and inflammatory or immunological abnormalities. The low serum globulin concentration observed in the BPH control indicated hepatic disorder and impaired protein synthesis in the liver [21]. While the significantly elevated serum globulin concentration in the Finasteride and CEESH treated rats are due to healthy liver status and improved liver functions in the rats that enable them to synthesise sufficient globulins. The serum globulins concentrations in the CEESH treated rats showed that a higher dose of CEESH (600 mg/kg) had better therapeutic effects and suggested that higher doses of CEESH are preferable therapeutic doses similar to the earlier observations by Chong *et al.* [22].

Bilirubin is the product of red blood cells (RBC) catabolism, tightly regulated by the liver cell that increases its polarity by conjugation, thereby making it quickly excreted from the body but accumulates in the blood when there are liver diseases or impaired liver functions. The elevated serum total bilirubin in the BPH control indicated increased haemolysis of RBC and impaired liver functions in the rats, similar to Nawaz *et al.* [23] reports. The significant reduction in the serum levels of total bilirubin levels in the CEESH administered rats compared to the BPH control showed that the CEESH treated rats had improved liver functions compared to the BPH control. Besides, total bilirubin concentrations in the CEESH administered rats were far above the normal control, suggesting that treatment with CEESH could not effectively restore their liver functions to the normal state and aligns with the finding of Chong *et al.* [22].

[Downloaded from pbp.medilam.ac.ir on 2026-11-25]

Direct bilirubin is the conjugated bilirubin that is easily excreted out of the body because of the increased polarity. The improved direct bilirubin level in the BPH control suggests that the rats could carry out conjugation of bilirubin but might have been unable to secrete a sufficient amount of bile acid that could have aided its excretion from the body. On the other hand, all the prostate enlarged rats administered Finasteride and CEESH, respectively, had normal direct bilirubin concentrations, which could be attributed to the improved liver functions and ability to secrete enough bile acid for the excretion of the conjugated bilirubin in line with findings of Nawaz *et al.* [23].

The normal liver histomorphology observed in the BPH control, and prostate enlarged rats administered Finasteride and CEESH, respectively, comparable to the normal control, suggests mere hepatic injury since the testosterone propionate used for the induction of BPH is not a hepatotoxicant. However, there could be impaired liver functions. The effects of BPH on the liver may be via different mechanisms that could have caused the impaired liver functions, as demonstrated in this study, and further studies may be needed to understand how BPH affects the liver histo-architecture and functions. The histomorphological changes observed in this study are consonant with the results of Gumaih who reported improved hepatic histology in rats with hepatic injury upon treatment with an appropriate agent [24].

Conclusion

This study revealed that benign prostatic hyperplasia increases the serum hepatic enzymes activities and impairs liver cells' ability to carry out protein synthesis and detoxification of serum bilirubin in rats. However, treatment with a combined ethanol extract of *Spermacoce radiata* and *Hypselodelphys poggeana* effectively lowered the serum hepatic enzymes activities and increased protein synthesis, including albumin and globulins concentration. Treatment with CEESH restored serum total bilirubin and direct bilirubin to near normal, which suggests CEESH contributes to the maintenance of normal liver functions and its effects on BPH.

Acknowledgements

The authors wish to express their profound gratitude to Prof. C.K. Ezeasor of the Department of Veterinary Pathology and Microbiology for his technical support in the histopathological examination of the liver sections.

Ethical approval for the study

The study was conducted with ethical approval (MOUAU/VPP/EC/18/004) from the College of Veterinary Medicine, MOUAU, which are in line with other international rules for using animals for the experiment.

Funding/Support

Not applicable.

Authors' contributions

URI, PCNA, ACF, and CNC designed the experiments; URI performed experiments and collected data; URI, PCNA, ACF, and CNC discussed the results and strategy; URI Supervised, directed and managed the study; URI, PCNA, ACF, and CNC Final approved of the version to be published (URI = Uroko Robert Ikechukwu, PCNA = Paul Chukwuemaka Nweje-Anyalowu, ACF = Aaron Chinomso Friday, CNC = Chukwu Charles Nnanna).

Conflict of interests

The authors do not have any conflict of interest.

References

1. Lee C, Kozlowski JM, Grayhack JT. Etiology of benign prostatic hyperplasia. Urol Clin North Am 1995; 22(2): 237-246. PMID: 7539172
2. Briganti A, Capitanio U, Suardi N, Gallina A, Salonia A, Bianchi M, et al. Benign prostatic hyperplasia and its aetiologies. Eur Urol Suppl 2009; 8(13): 865-871.
3. Akbari F, Azadbakht M, Megha K, Dashti A., Vahedi L, Nejad A B, et al. Evaluation of Juniperus communis L. seed extract on benign prostatic hyperplasia induced in male Wistar rats. Afr J Urol 2021; 2021: 27:48. doi.org/10.1186/s12301-021-00137-x
4. Rohrmann S, Katzke V, Kaaks R. Prevalence and progression of lower urinary tract symptoms in an

[Downloaded from pbp.medilam.ac.ir on 2026-11-25]

aging population. Urol 2016; 95: 158–163. doi: 10.1016/j.urology.2016.06.021

5. Iscaife A, Anjos G, Barbosa NC, Nahas WC, Srougi M, Antunes AA. The role of bladder diverticula in the prevalence of acute urinary retention in patients with BPH who are candidates to surgery. Int Braz J Urol 2018; 44(4):765-770. doi: 10.1590/S1677-5538.IBJU.2017.0605.
6. Keong TF. Pathophysiology of clinical benign prostatic hyperplasia. Am Res J Urol 2017; 4: 152-157. doi: 10.1016/j.ajur.2017.06.003.
7. Gormley J, Stoner E, Bruskewitz RC, Imperato-McGinley J, Walsh PC, McConnell JD. The effect of Finasteride in men with benign prostatic hyperplasia. N Engl J Med 1992; 327(17): 1185-1191. doi: 10.1056/NEJM199210223271701.
8. Yu ZJ, Yan HL, Xu FH, Chao HC, Deng LH, Xu XD, et al. Efficacy and side effects of drugs commonly used for the treatment of lower urinary tract symptoms associated with benign prostatic hyperplasia. Front Pharmacol 2020; 11: 658. doi.org/10.3389/fphar.2020.00658
9. Miles CB, Charu T, Lomas KT, Pradeep K, Yahya EC, Viness, P. Nutraceutical-based therapeutics and formulation strategies augmenting their efficiency to complement modern medicine: An Overview. J Funct Foods 2014; 6: 82-99. doi: 10.1016/j.jff.2013.09.022
10. Pereira ZV, Carvalho-Okano RM, Garcia FC. Rubiaceae Juss. da Reserva Florestal Mata do Paraíso, Viçosa, MG, Brasil. Acta Bot Brasilica 2006; 20:207-224. doi.org/10.1590/S0102-33062006000100020
11. Vadivelan S, Sinha BN, Betanabhatla KS, Christina AJ, Pillai RN. Anti-inflammatory activity of Spermacoce articularis Linn on carrageenan induced paw edema in Wistar male rats. Pharmacologyonline 2007; 3: 478-484.9
12. Subramanya MD, Pai SR, Upadhya V, Ankad GM, Bhagwat SS, Hegde HV. Total polyphenolic contents and in vitro antioxidant properties of eight Sida species from Western Ghats, India. J Ayurveda Integr Med 2015; 6: 24-8. doi: 10.4103/0975-9476.146544.
13. Abbiw D. Useful Plants of Ghana: West African Uses of Wild and Cultivated Plants London: Intermediate Technology Publications, Royal Botanic Gardens, Kew 1990; 337.
14. Uroko RI, Anyiam PN, Uhuo EN, Ajah O. Combined ethanol extract of Spermacoce radiata and Hypselodelphyspoggeana prevents renal damage and dyslipidemia in benign prostatic hyperplasia induced rats. J Herb Med 2021; 12(4): 43-52. doi: 10.30495/medherb.2021.688096
15. Thornburg JM. Targeting aspartate aminotransferase in breast cancer. Breast Cancer Res 2008; 10(5): R84-R84.
16. Ekeyi Y, Uchendu NO, Anaduaka EG, Ezeanyika LUS. Ethanol extract of Cassia sieberiana leaves ameliorates deviances associated with benign prostatic hyperplasia in rats. All Life 2021; 14: 473-483. doi.org/10.1080/26895293.2021.1927857
17. Chukwu CN, Uroko RI, Egba SI, Adamude FA, Asadu CL. Effects of combined ethanol extract of Anthocleista Vogelii and Alstonia Boonei stem barks on liver function indices in benign prostatic hyperplasia induced rats. Nigerian J Pharm Res 2021; 16(2):191-201.
18. Pratt DS, Kaplan MM. Evaluation of abnormal liver-enzyme results in asymptomatic patients. Acta Clin Belg 2004; 59(5): 285-289. doi: 10.1056/NEJM200004273421707.
19. Stocken DD. Modelling prognostic factors in advanced pancreatic cancer. Br J Cancer 2008; 99(6): 883-893.
20. Amang AP, Kodji E, Mezui C, Baane MP, Siwe GT, Kuissu TM, Emakoua J, Tan PV. Hepatoprotective Effects of Aqueous Extract of Opilia celtidifolia (Opiliaceae) Leaves against Ethanol-Induced Liver Damage in Rats. Evid Based Complement Alternat Med 2020; 6297475, https://doi.org/10.1155/2020/6297475
21. Tofik AE, Zawdie B, Nair SKP, Welde M, Mateos HT. Evaluation of the effect of hydromethanolic seed extract of Lepidium sativum L. (Fetto) on deep-fried palm oil diet induced nonalcoholic fatty liver disease on male Swiss albino mice. Hepatic Medicine: Evid Res 2022; 14: 1-12. doi.org/10.2147/HMER.S350703
22. Chong CLG, Hussan F, Othman F. Hepatoprotective effects of Morinda citrifolia leaf extract on ovariectomized rats fed with thermoxidized palm oil

[Downloaded from pbp.medilam.ac.ir on 2026-11-25]

diet: evidence at histological and ultrastructural level. Oxid Med Cell Longev 2019; 20(2): 2-10. doi.org/10.1155/2019/9714302

23. Nawaz H, Rehman T, Aslam M, Kiran S, Feen T, Nawaz M. Optimization of Phyllanthus emblica L. leaf extract-assisted clearance of hyperbilirubinemia in White New Zealand albino rabbits. All Life 2022; 15:54-63. doi.org/10.1080/26895293.2021.2022006
24. Gumaih HS. Effect of reused palm oil on biochemical and haematological parameters of mice. Egypt Acad J Biol Sci 2015; 7(1):13-21. doi:10.21608/eajbsz.2015.13474

[Downloaded from pbp.medilam.ac.ir on 2026-11-25]