

Evaluation of Zinc Oxide Nanoparticles Coated with Acetylsalicylate on the Wound Healing Process in Male Rats

Kazem Rakhshan¹ , Abdolrazagh Marzban² , Zahra Haghighatian³ , Abbas Raisi⁴ , Leila Zarei⁵ ,
Asadollah Roshani⁶ 

¹Surgery Resident, Lorestan University of Medical Sciences, Khorramabad, Iran

²Razi Herbal Medicines Research Center, Lorestan University of Medical Sciences, Khorramabad, Iran

³Department of Pathology, School of Medicine, Lorestan University of Medical Sciences, Khorramabad, Iran

⁴Department of Clinical Sciences, Faculty of Veterinary Medicine, Lorestan University, Khorramabad, Iran

⁵Palliative Care Research Center, Ur.C., Islamic Azad University, Urmia, Iran

⁶Department of Surgery, School of Medicine, Lorestan University of Medical Sciences, Khorramabad, Iran

Article Info	ABSTRACT
<p>Article type: Original Article</p> <p>Article History: Received: Revised: Accepted: Published Online:</p> <p>✉ Correspondence to: Leila Zarei Asadollah Roshani</p> <p>Email: leilazarei652@yahoo.com mohamad@gmail.com</p>	<p>Objective: Wound healing is a critical physiological process that preserves the skin's barrier function and prevents infection. Recent advances in nanotechnology, particularly the use of metallic nanoparticles, has opened new avenues to enhance the quality and accelerate the rate of wound repair. Among these, zinc oxide nanoparticles coated with acetylsalicylate have garnered considerable attention due to their combined antibacterial and regenerative properties, positioning them as a promising therapeutic agent in wound management. This study aimed to investigate the therapeutic effects of acetylsalicylate-coated zinc oxide nanoparticles on wound healing in male rats, with a particular focus on histopathological outcomes.</p> <p>Methods: Forty-eight healthy male Wistar rats of uniform weight were randomly assigned into four groups (n=12 each) following the induction of standardized wounds: Group I (control, no treatment), Group II (treated with standard phenytoin ointment), Group III (treated with base ointment), and Group IV (treated with acetylsalicylate-coated zinc oxide nanoparticles). Treatments were applied once daily for seven consecutive days. Histopathological assessments were performed on days 7, 14, and 21 post-wounding.</p> <p>Results: The results demonstrated that Group IV exhibited significantly enhanced histopathological indices and wound healing compared to the other groups ($P < 0.05$). These findings suggest that zinc oxide nanoparticles coated with acetylsalicylate exert potent anti-inflammatory, antibacterial, and tissue-regenerative effects that substantially promote wound repair in this animal model. The marked improvement in epidermal and dermal regeneration across different phases of healing highlights the efficacy of this nanocomposite.</p> <p>Conclusion: Given these promising results, acetylsalicylate-coated zinc oxide nanoparticles may represent a novel and effective therapeutic modality for wound management, particularly for infected wounds. Nonetheless, further preclinical studies and clinical trials are necessary to validate these effects and support their translation to human clinical applications.</p> <p>Keywords: Wound healing, Wound, Zinc oxide nanoparticles, Acetylsalicylate, Rat</p>
<p>➤ How to cite this paper</p> <p>Rakhshan K, Marzban A, Haghighatian Z, Raisi A, Zarei L, Roshani A. Evaluation of Zinc Oxide Nanoparticles Coated with Acetylsalicylate on the Wound Healing Process in Male Rats. <i>Plant Biotechnology Persa</i>. 2025; 7(5): Proof.</p>	

Introduction

Wound healing is a complex and vital biological mechanism that plays a decisive role in maintaining homeostasis and the protective function of the skin [1]. As the largest organ of the body, the skin serves as the first line of defense against physical, chemical, and biological environmental factors, and disruption of its integrity can lead to localized and systemic infections as well as various functional impairments [2]. A wound, defined as a breach in the continuity and function of the skin and underlying tissues caused by various injuries, can result in serious complications such as chronic infections, scar tissue expansion, and even systemic dysfunction if not properly healed [3,4].

Wound healing involves a well-orchestrated series of phases starting from hemostasis and inflammation, progressing through cellular proliferation and migration, and culminating in extracellular matrix remodeling and tissue maturation [5,6]. Any disturbance in these phases may delay healing and cause chronic wounds, a phenomenon particularly prevalent among certain populations such as diabetic patients, the elderly, and immunocompromised individuals [7,8].

Nanotechnology, as a fundamental advancement in regenerative medicine, has enabled the development of nanoparticles with unique physicochemical properties [9,10]. Zinc oxide nanoparticles (ZnO NPs) have been extensively studied for their antibacterial, anti-inflammatory properties and their ability to stimulate growth factor production [9,10]. These nanoparticles promote a favorable microenvironment for wound healing by inducing beneficial cellular responses and controlling infections [11,12]. Meanwhile, acetylsalicylate—a chemical derivative of salicylic acid—possesses well-documented anti-inflammatory, analgesic, and antithrombotic effects and is widely used in treating inflammatory and painful conditions [13,14]. Coating ZnO nanoparticles with acetylsalicylate not only enhances their stability but also potentiates synergistic anti-inflammatory and regenerative effects, representing an innovative non-invasive strategy for wound treatment [15,16]. However, limited research has addressed the molecular mechanisms and combined effects of these two agents [17,18].

Animal models play a pivotal role in the preclinical evaluation of novel therapies. Male rats, due to their immunological and physiological similarities to humans, constitute a reliable and widely used model for wound healing studies [19]. Detailed histopathological analysis of acetylsalicylate-coated ZnO nanoparticles in this model can provide valuable insights for clinical translation [20].

Given the limitations of conventional wound treatments, such as autologous skin grafting—often associated with pain, scarring, and donor site restrictions [3] the development of non-invasive, cost-effective, and highly efficient alternatives is of paramount importance [21]. Ideal dressings should maintain moisture, protect the wound, reduce inflammation, control edema, and stimulate tissue regeneration [22].

For instance, a study synthesized gold nanoparticles coated with salicylate and assisted by willow tree extract, demonstrating effective antifungal activity as well as notable analgesic and muscle relaxant properties [23]. In 2017, ZnO nanoparticles with a minimum inhibitory concentration (MIC) of 125 µg/mL effectively inhibited *Staphylococcus aureus* growth. Topical treatment of infected wounds in rats significantly reduced both surface and deep bacterial loads and accelerated wound closure ($p < 0.05$), underscoring ZnO nanoparticles' potent antimicrobial efficacy in wound management [24]. Siddiqi et al. (2018) reported that ZnO nanoparticles, due to their absorption of UVA and UVB light and distinctive morphology, effectively combat bacteria and fungi by penetrating cell walls, disrupting membranes, and inducing apoptosis, as confirmed by transmission electron microscopy [25]. Another study revealed that ZnO nanoparticles reduced wound and scar size in female Syrian hamsters with burns, while increasing epidermal thickness, vascularization, and hair follicle density relative to controls, highlighting their beneficial effects on skin repair and follicular growth [26].

Coating ZnO nanoparticles with acetylsalicylate enhances structural stability and reduces particle aggregation, significantly improving their anti-inflammatory and antibacterial properties. This innovative composite leverages the synergistic effects

of two active agents, offering an effective and non-invasive therapeutic approach to accelerate wound healing. To our knowledge, this study is the first to utilize acetylsalicylate-coated ZnO nanoparticles as a combined nanoformulation with both regenerative and antibacterial potentials, capable of markedly enhancing local therapeutic efficacy and accelerating cutaneous wound repair.

Despite extensive evidence supporting the beneficial effects of ZnO nanoparticles in wound healing, comprehensive and systematic investigations into their combined use with anti-inflammatory compounds like acetylsalicylate, along with detailed histopathological analyses in animal models, remain scarce. This scientific gap underscores the need for targeted research. Accordingly, the present study aims to evaluate the therapeutic effects, tissue regeneration, and histological alterations induced by acetylsalicylate-coated ZnO nanoparticles in a male rat skin wound model. The outcomes of this research may open new avenues for the development of advanced wound therapies and facilitate their clinical translation.

Materials and Methods

Study

This experimental study (laboratory trial) was conducted to evaluate the effects of acetylsalicylate-coated zinc oxide nanoparticles on the wound healing process in male rats.

Design

Study Population and Sample Size

A total of 48 adult male Wistar rats weighing approximately 190 ± 10 grams were used in this study. The animals were procured from the Faculty of Medicine at Lorestan University of Medical Sciences and housed under controlled conditions with natural light cycles and constant room temperature. They underwent a two-week acclimatization period to minimize environmental stress effects on study outcomes. Rats were fed pellet chow and had ad libitum access to food and water.

Surgical Materials and Equipment

The following materials and instruments were utilized: Xylazine (Xylazine Alfasan, Netherlands), Ketamine (Bremer Pharma, Germany), scissors, scalpel, bistoury blade, disposable gloves, insulin syringes, electric

shaver with blade number 4, sterile gauze, and biopsy punch.

Synthesis of Zinc Oxide Nanoparticles

Zinc oxide nanoparticles were synthesized via a hydrothermal method in the presence of methyl or acetylsalicylate. Fifty milliliters of zinc nitrate hexahydrate solution (4.5 g/L) was stirred magnetically at 60°C. Subsequently, 50 mL of hydroalcoholic acetylsalicylate solution (60% ethanol) at concentrations between 0.5–1.5% was slowly added. One molar sodium hydroxide solution was then added dropwise, and the mixture was stirred for 6 hours. The formation of a white suspension indicated successful nanoparticle synthesis (30).

Preparation of Ointment Containing Acetylsalicylate-Coated Zinc Oxide Nanoparticles

One gram of synthesized nanoparticles was thoroughly mixed with 100 grams of 400% ucerin using a laboratory mixer. The resulting ointment was stored in appropriate containers under refrigeration and protected from light until use.

Study

Following wound induction, animals were randomly allocated into four groups of 12 rats each. Treatments were administered once daily for seven consecutive days as follows:

Procedure

Group 1 (Control): Wound induction without any treatment

Group 2: Treatment with standard phenytoin ointment

Group 3: Treatment with base ointment

Group 4: Treatment with ointment containing acetylsalicylate-coated zinc oxide nanoparticles

Anesthesia and Wound Creation

All procedures adhered strictly to ethical principles for biomedical research. Experimental design, animal handling, and interventions complied with the Guide for the Care and Use of Laboratory Animals (NIH) and the bioethical laws of the Islamic Republic of Iran. Ethical approval was granted by the Ethics Committee of Lorestan University of Medical Sciences (approval code: IR.lums.RES.1403.263).

On the day of surgery, rats were anesthetized via intraperitoneal injection of ketamine (60 mg/kg) combined with xylazine (5–10 mg/kg) [27]. The surgical site was disinfected with povidone-iodine and 70% ethanol. Animals were positioned laterally, and the dorsal skin between the scapulae was stretched and stabilized between two fingers to prepare for wound creation. A 10-mm biopsy punch was applied with rotational motion to the posterior scapular area, and underlying tissues, including the panniculus carnosus muscle, were excised using scissors and forceps.

Recovery and Postoperative Care

After surgery, animals were individually housed and placed under warming lamps until fully recovered from anesthesia. Daily monitoring of general health and wound condition was conducted. Treatments were applied without anesthesia at consistent times (approximately 10–11 a.m.) for seven days.

Histopathological Sampling

Tissue samples, including the wound margin and 1–2 mm of adjacent healthy skin, were collected on days 7, 14, and 21 post-surgery. Samples were immediately fixed in 10% formalin, sectioned into 5-micron slices using a microtome, and stained with hematoxylin-eosin and Masson's trichrome. Slides were examined under a light microscope (Olympus CX31RBSF) equipped with a digital camera.

Quantitative Collagen Assessment

Collagen deposition at the wound site was quantified using ImageJ software with the Color Deconvolution plugin specific for Masson's trichrome staining. The intensity of blue staining, indicative of collagen content, was assessed on days 7, 14, and 21 for each group. Collagen levels were categorized as negative (–), weak (+), mild to moderate (++), moderate (+++), or high (++++ [28].

Wound Area Measurement (Planimetry)

Digital photographs of wounds alongside a scale ruler

were taken on day 0 and days 3, 6, 9, 12, 15, 18, and 21. Wound areas were measured using Adobe Acrobat 9 Pro Extended software (29). Wound healing percentage was calculated as:

$$\text{Wound Healing (\%)} = (A_0 - A_t) / A_0 \times 100$$

where A_0 is the wound area on day 0 and A_t is the wound area on the day of measurement.

Hydroxyproline Determination

Hydroxyproline, the main amino acid constituent of collagen, was quantified to estimate collagen content in healing tissue. Hydroxyproline levels were measured following the method proposed by Reddy et al. (1996). On day 21 post-wounding, tissue samples were collected from the wound center, ensuring equal weights across groups. One gram of each sample was dried at 60°C in an oven and hydrolyzed in 6N hydrochloric acid at 130°C in sealed test tubes. The hydrolysate was neutralized with a pH 7 buffer and oxidized with Chloramine T for 20 minutes. The reaction was terminated by adding 4M perchloric acid, and the resulting chromogen was developed with Ehrlich's reagent at 60°C. Absorbance was measured at 557 nm using a UV-visible spectrophotometer.

Characterization of Acetylsalicylate-Coated Zinc Oxide Nanoparticles

Morphological analysis of the coated nanoparticles was performed using scanning electron microscopy (SEM). Images revealed predominantly spherical nanoparticles with some aggregated clumps (Figure 1). Particle sizes ranged from 10 to 90 nm. Given that nanoparticles are defined as particles below 100 nm, and that particles within this size range possess a high surface-area-to-volume ratio, these properties enhance tissue penetration and therapeutic efficacy. Additionally, acetylsalicylate coating improves biocompatibility. The synthesized nanoparticles met the expected criteria for effective wound healing applications.

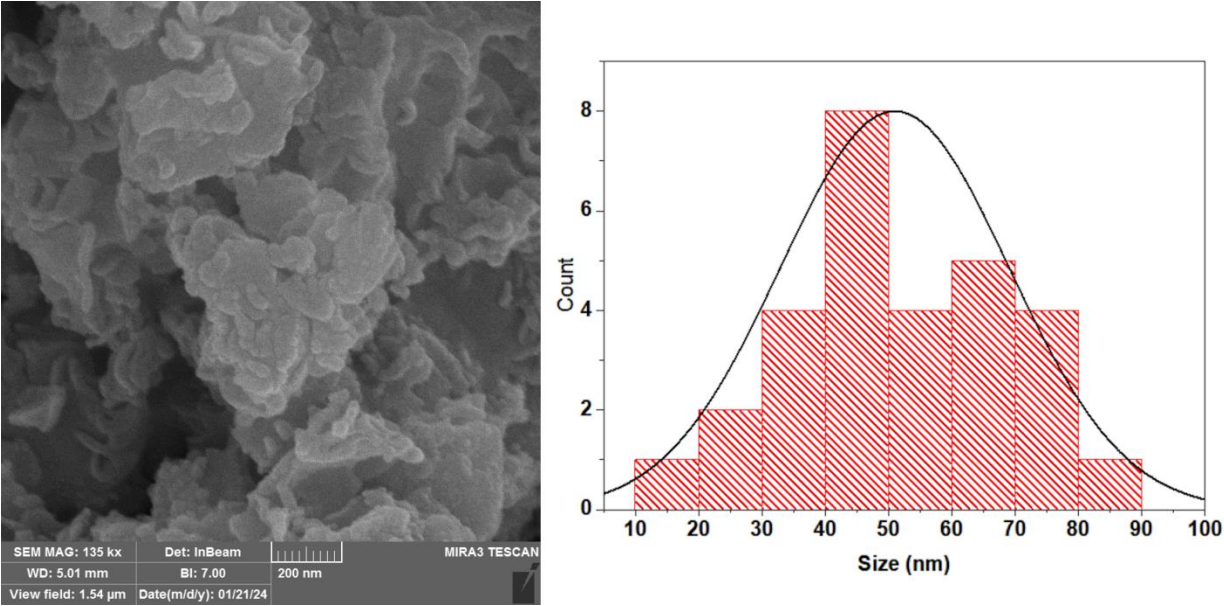


Figure 1: Morphological analysis of acetylsalicylate-coated zinc oxide nanoparticles.

Statistical Analysis

Quantitative data are presented as mean ± standard deviation; qualitative data are expressed as frequency and percentage. Data normality was assessed by the Shapiro-Wilk test. For normally distributed data, independent and paired t-tests and repeated measures ANOVA were applied. Non-parametric equivalents were used when normality assumptions were violated. Statistical significance was set at $p < 0.05$. All analyses were performed using SPSS version 22 with two-tailed tests.

Results

Assessment of Hydroxyproline Content in Wounds

The hydroxyproline levels are presented in Table 1. The group treated with ointment containing acetylsalicylate-coated zinc oxide nanoparticles showed a significantly higher hydroxyproline content compared to the other groups ($P < 0.05$).

Table 1: Hydroxyproline levels in different groups. Values are presented as mean ± standard error.

Experimental Groups	Description	Hydroxyproline (mg/g)
G I	Control	38.49 ± 3.77 ^a
G II	Wound + Standard phenytoin Ointment	52.13 ± 4.28 ^a
G III	Wound + Base Ointment	58.63 ± 4.10 ^a
G IV	Wound + Zinc Oxide Nanoparticles Coated with Acetylsalicylate	68.71 ± 3.61 ^b

Different letters in each column indicate a significant difference ($P < 0.05$)

Histological Evaluation

Histological assessments were performed across the different groups on days 7, 14, and 21, focusing on parameters such as hemorrhage and collagen deposition. Regarding epithelialization, results indicated a moderate level on day 7, which progressed to severe on day 14, and reached a very severe degree by day 21.

The density of collagen fibers is summarized in Table 2. To qualitatively assess collagen content at the wound site, ImageJ software was utilized to isolate the blue-stained collagen areas. Collagen measurements for days 7, 14, and 21 in each group are presented in

Table 2. Statistical analysis revealed a significant difference in collagen levels between the control and nanoparticle-treated groups on days 7, 14, and 21 ($P \leq 0.05$). These findings correspond to an observed trend of moderate, severe, and very severe collagen deposition on days 7, 14, and 21, respectively.

The increased collagen density in the treatment group receiving the ointment containing acetylsalicylate-coated zinc oxide nanoparticles was significantly higher compared to the other groups, confirming the positive and impactful effect of this treatment on wound healing (Figure 2).

Table 2: Histopathological Assessments

Group	Collagen Deposition			Re-epithelialization		
	Day 7	Day 14	Day 21	Day 7	Day 14	Day 21
G I (Control)	-	++	+	-	+	+
G II (Wound + Standard Phenytwain Ointment)	+	+	+	+	++	+
G III (Wound + Base Ointment)	+	+	+	-	++	+
G IV (Wound + Zinc Oxide Nanoparticles Coated with Acetylsalicylate)	++*	+++*	++++*	++*	+++*	++++*

*shows a significant difference with control group at $P < 0.05$.

Classification of Histological Parameters Based on Severity

The histological parameters were classified according to the severity of occurrence as follows: absence (-), weak (+), moderate (++), severe (+++), and very severe (++++). These evaluations were performed on days 7, 14, and 21 across the studied groups. Statistical significance was considered at $P < 0.05$.

Planimetric analysis (measured in square millimeters) demonstrated significant differences in wound area changes over the study period between the control group and various treatment groups ($P < 0.05$). The wound closure rate in the group treated with ointment containing acetylsalicylate-coated zinc oxide nanoparticles was significantly faster compared to other treatment groups (Figure 3).

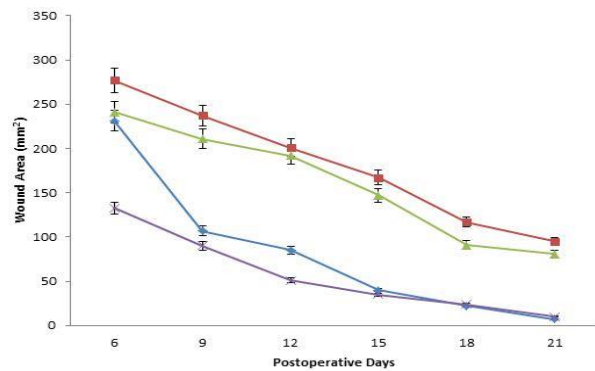


Figure 3: Wound Surface Area

However, from day 5 onward, as shown in Figure 3 and corresponding measurements, a significant reduction in wound size and progression of healing was evident in the treatment groups. Over the 14-day treatment period, wounds treated with the nanoparticle ointment exhibited a marked decrease in wound area compared to the control group. This notable improvement in wound closure and healing is clearly demonstrated in the macroscopic images of the wounds (Figure 4).

Macroscopic

No significant differences were observed among the groups on the first day post-wounding ($P \geq 0.05$).

Findings

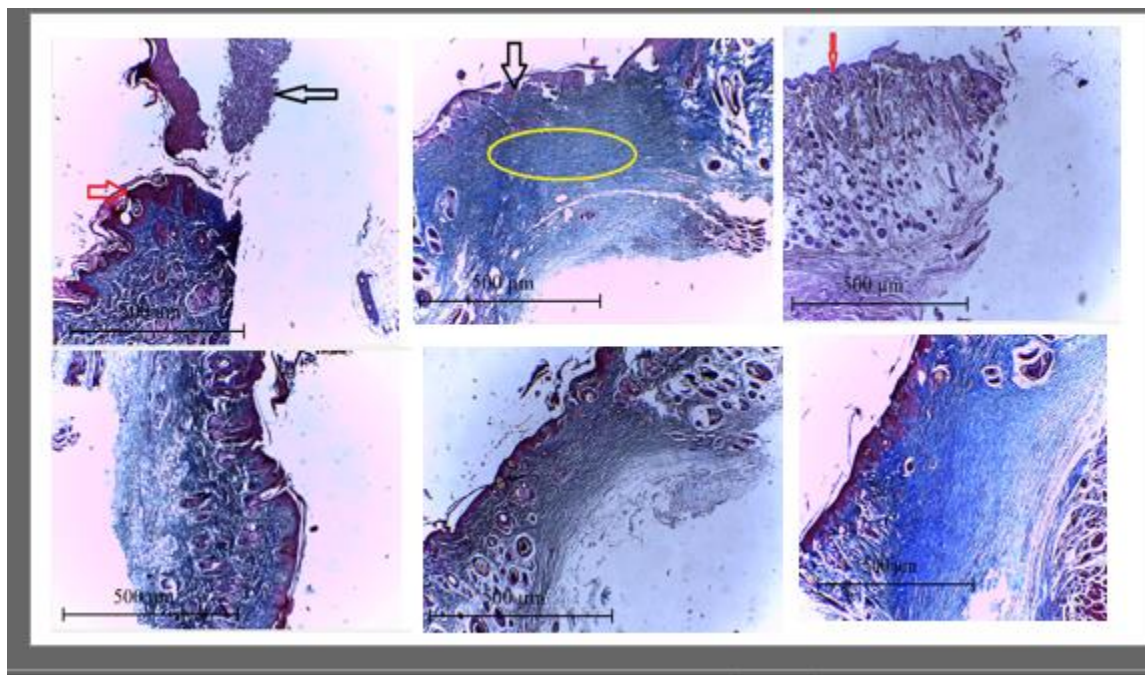


Figure 2: Comparison of the Microscopic Wound Healing Progression Among Different Treatment Groups, Highlighting the Efficacy of Zinc Oxide Nanoparticles Coated with Acetylsalicylate (Masson's trichrome staining at 100x magnification).

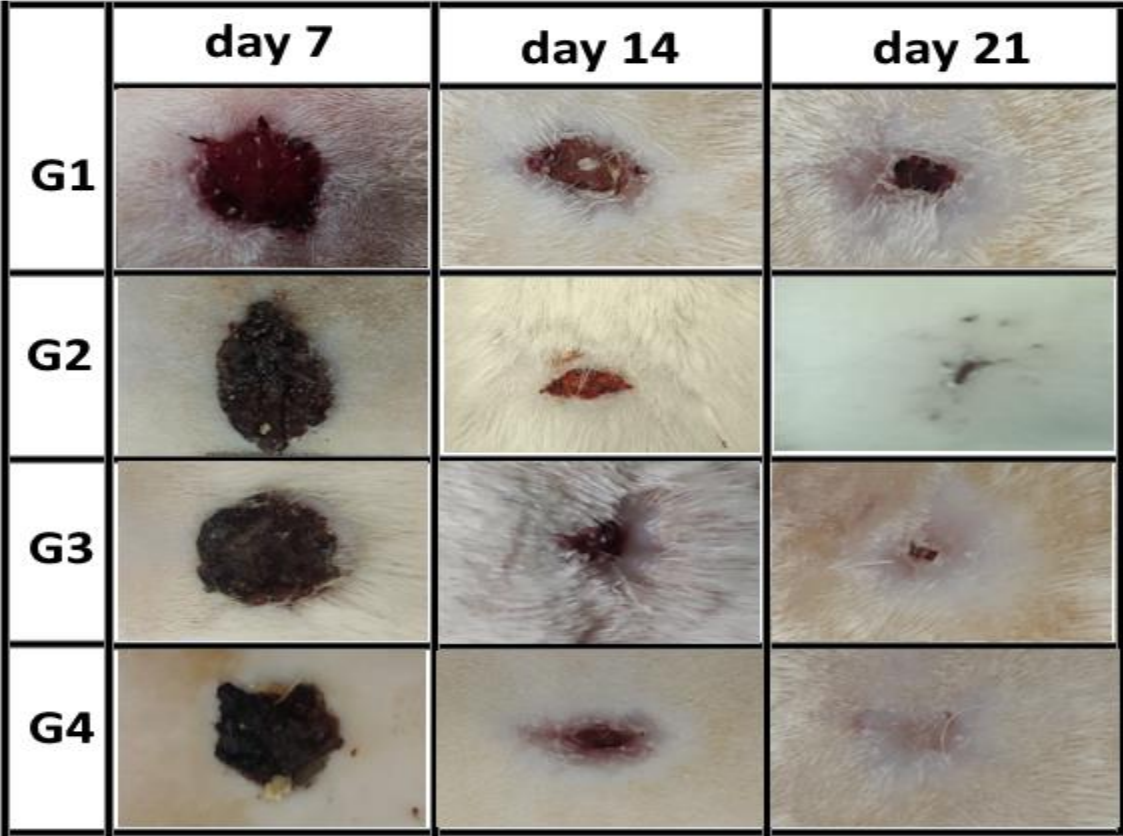


Figure 4: Effect of Time on Wound Area Reduction and Planimetric Assessment Across Different Treatment Groups

Effect of Time on Wound Healing Across Different Groups

Analysis of the effect of time on wound healing demonstrated that changes in wound area were not

uniform across all groups at different time points ($P \leq 0.05$). For example, the differences observed in planimetric measurements are illustrated below; similar patterns were noted for the other time points as well (Figure4).

Discussion

The present study aimed to investigate the effects of zinc oxide nanoparticles coated with acetylsalicylate on the wound healing process in rats. In recent years, metallic and metal oxide nanoparticles have attracted considerable attention due to their unique properties such as lower toxicity, higher bioavailability, enhanced safety, and superior penetration and distribution in various biological tissues compared to their bulk counterparts [32]. Zinc oxide nanoparticles exhibit notable antibacterial properties and have been employed in drug formulations [33]. Moreover, these nanoparticles possess anti-inflammatory effects [34],

and zinc itself promotes epidermal regeneration and reduces burn-related scarring [35].

Salicylic acid is known as an effective anti-inflammatory agent. Among its derivatives, methyl salicylate is one of the most commonly used pharmaceutical forms, often applied topically as an ointment to alleviate pain and inflammation [36]. Beyond its pharmaceutical applications, methyl salicylate in plants functions as a phytohormone involved in regulating growth, enhancing defense mechanisms, responding to environmental stresses, and facilitating fruit ripening [37].

According to established wound healing evaluation criteria, our findings demonstrated that topical

application of an ointment containing the synthesized nanoparticles can significantly accelerate tissue repair. One of the principal indicators in this assessment was the macroscopic observation of wound size reduction over time. Consistent with Rajakumari et al., gradual wound contraction during healing results from two key processes: wound contraction and connective tissue deposition. Wound contraction is primarily mediated by myofibroblast cells, which, through their contractile properties, approximate the wound edges and reduce its dimensions [38–41]. Additionally, Agren and colleagues reported that zinc oxide nanoparticles effectively promote epidermal regeneration and reduce the size of cutaneous scars, with nanoparticle-treated groups exhibiting smaller scars than controls [42]. Our results align with these findings, as a significant reduction in wound size was observed in the nanoparticle-treated group, potentially due to enhanced fibroblast migration and activity, increased collagen synthesis, and consequently improved tissue tensile strength. The active involvement of myofibroblasts likely played a critical role in wound contraction and reduction of damaged tissue area, corroborating previous studies.

Collagen, a major extracellular matrix component, plays a vital structural and supportive role in tissue remodeling. It primarily comprises the amino acid hydroxyproline, which serves as a reliable biochemical marker for quantifying collagen content in tissues [42]. In the current study, animals treated with the zinc oxide nanoparticles coated with acetylsalicylate ointment showed a significant reduction in wound area, indicative of increased collagen deposition and accelerated tissue repair [43]. Hydroxyproline stabilizes the triple helical structure of collagen by forming hydrogen bonds between polypeptide chains, thus maintaining collagen's strength and structural integrity. Consequently, hydroxyproline content is considered an accurate indicator of collagen synthesis [43]. Our results revealed that hydroxyproline levels (expressed as mg per gram of skin) were significantly higher in the treated group than in others, highlighting the positive effect of zinc oxide nanoparticles coated with acetylsalicylate on stimulating collagen synthesis, improving fibril arrangement, and ultimately enhancing the tensile strength of the wound site.

Planimetric evaluation further confirmed that the ointment containing zinc oxide nanoparticles coated with acetylsalicylate significantly accelerated wound contraction and reduced the damaged area compared to other treatment groups. This drug formulation played a pivotal role in hastening wound closure. Histopathological findings clearly demonstrated that the treated group scored higher in wound healing parameters than the other experimental groups. Noteworthy tissue changes included a shortened inflammatory phase, increased granulation tissue formation, and accelerated wound contraction. These changes indicate faster epithelial regeneration and increased proliferation and activity of fibroblasts. Previous evidence supports that controlling inflammatory processes and using antioxidant compounds can markedly expedite wound healing [44]. Conversely, the presence of detrimental factors such as infection, free radicals, and oxidants exacerbates tissue damage and delays skin wound recovery [45].

Phenolic and flavonoid compounds, as key plant secondary metabolites, exhibit diverse biological activities, including antioxidant, anti-inflammatory, and antibacterial effects. These properties are essential in promoting wound healing [46]. Studies have demonstrated that phenolic compounds effectively treat skin lesions, slow skin aging, aid in burn healing, and significantly reduce wound healing time [47]. Furthermore, flavonoids facilitate wound contraction, stimulate epithelial cell regeneration, and promote collagen synthesis [48].

Given the well-documented anti-inflammatory and antioxidant properties of zinc oxide nanoparticles and salicylate derivatives—particularly acetylsalicylate—it is plausible that the ointment containing zinc oxide nanoparticles coated with acetylsalicylate exerts its positive influence on wound healing through these mechanisms [49].

The antibacterial activity of zinc oxide nanoparticles primarily arises from their unique physicochemical features and high surface area to volume ratio. Direct contact between these nanoparticles and bacterial cell membranes disrupts cell wall integrity, triggers the release of Zn^{2+} ions, and generates reactive oxygen species (ROS), culminating in bacterial death [50].

Additionally, the angiogenic potential of zinc oxide nanoparticles has been explored in various studies. For instance, nanoparticles coated with peptides [51] or graphene oxides [52] have demonstrated the ability to promote angiogenesis in animal and in vitro models. Microwave-synthesized zinc oxide nanoparticles have also been shown to stimulate endothelial cell proliferation and migration, both crucial steps in new blood vessel formation within wound beds [50]. Augustine et al. designed and synthesized nanoscaffolds containing zinc oxide nanoparticles with proven angiogenesis-inducing properties, yielding positive effects on skin wound healing [53].

Zinc oxide nanoparticles exhibit a broad range of bioactivities due to their distinct physical and chemical properties. Synthesized in various morphological forms, they display significant antibacterial effects at both nano and micro scales. Evidence suggests that smaller particle sizes correlate with enhanced antibacterial activity, as nanoparticles interact with bacterial membranes or penetrate microbial cells, disrupting vital structures and causing cell death [54, 55].

Beyond antibacterial effects, zinc oxide nanoparticles also possess anti-inflammatory properties. Studies on the chorioallantoic membrane demonstrated that zinc oxide nanoparticles significantly reduced blood vessel number and size and decreased fetal weight and size. In a mouse paw edema model, their application markedly reduced inflammation. Furthermore, gene expression analysis in MCF-7 cancer cells showed that these nanoparticles downregulated VEGF and its receptor expression while upregulating IL-10 and downregulating IL-1 β , implicating roles in anti-inflammatory and antitumor pathways [56].

Collectively, these findings suggest that zinc oxide nanoparticles can effectively accelerate the healing of both infected and non-infected wounds through antibacterial activity, inflammation modulation, and scavenging of free radicals and oxidants. These mechanisms, combined with growth factor stimulation and inhibition of tissue-damaging agents, contribute to more efficient tissue regeneration.

Attenuation of inflammation, or modulation of the inflammatory phase, is a crucial factor in accelerating wound healing [57]. Our study found a significant

reduction in inflammation severity and accelerated healing in the group treated with the zinc oxide nanoparticles coated with acetylsalicylate ointment compared to controls. This suggests an earlier onset of the tissue remodeling phase in this group [58].

Hence, the mechanism underlying the effect of zinc oxide nanoparticles combined with acetylsalicylate may involve stimulation of anti-inflammatory pathways, enhanced cell proliferation, and activation of myofibroblasts for collagen synthesis. Considering the vital roles of these factors in extracellular matrix formation and skin structure restoration, this ointment appears to play a significant role in promoting wound healing. Nonetheless, detailed investigations into the molecular pathways involved are warranted through more comprehensive cellular and molecular studies.

Limitations

This study was limited by the use of an animal model, which restricts direct extrapolation to humans. Moreover, molecular mechanisms underlying nanoparticle effects were not fully explored, and the follow-up period was relatively short (21 days). Systemic safety of nanoparticles and comparisons with other coatings were not assessed. Therefore, further extensive studies focusing on mechanisms, toxicity, and clinical trials are necessary to confirm these results.

Conclusion

The findings of this study demonstrate that topical application of an ointment containing zinc oxide nanoparticles coated with acetylsalicylate significantly enhances wound healing in male rats. Notably, epidermal regeneration by day seven and dermal repair by day fourteen were significantly improved compared to control groups. These results indicate that this nanotechnology-based formulation, leveraging anti-inflammatory, antioxidant, and collagen-stimulating properties, facilitates multiple phases of wound healing and accelerates tissue regeneration. Given the marked efficacy observed, further research and development of this ointment for treating acute and chronic skin wounds is recommended. However, confirmatory studies in other animal models and eventually human clinical trials are essential to verify its safety and therapeutic potential.

Statements and Declarations

Funding support

The authors did not receive support from any organization for the submitted work.

Competing interests

The authors have no competing interests to declare that are relevant to the content of this article.

Ethics approval

This study was performed in line with the principles of the Declaration of Helsinki.

Consent to participate

Informed consent was obtained from all individual participants included in the study.

Acknowledgments

The authors would like to express their gratitude to Lorestan University of Medical Sciences, for financial support.

References

1. Wysocki AB. Skin anatomy, physiology, and pathophysiology. *Nurs Clin North Am*. 1999;34(4):777-97.
2. Hansbrough JF. Current status of skin replacements for coverage of extensive burn wounds. *J Trauma Acute Care Surg*. 1990;30:155-9.
3. Ben-Bassat H, Chaouat M, Segal N, Zumai E, Wexler M, Eldad A. How long can cryopreserved skin be stored to maintain adequate graft performance? *Burns*. 2001;27(5):425-31.
4. Gajiwala K, Gajiwala AL. Evaluation of lyophilised, gamma-irradiated amnion as a biological dressing. *Cell Tissue Bank*. 2004;5:73-80.
5. Hawn MT, Graham LA, Richman JS, Itani KM, Henderson WG, Maddox TM. Risk of major adverse cardiac events following noncardiac surgery in patients with coronary stents. *JAMA*. 2013;310(14):1462-72.
6. Baker P, Charlton A, Johnston C, Leahy JJ, Lindegaard K, Pisano I, et al. A review of Willow (*Salix* spp.) as an integrated biorefinery feedstock. *Ind Crops Prod*. 2022;189:115823.
7. Mathews KA, Binning A. Wound management using honey. *Compend Contin Educ Nurs*. 2002;24(1):53-9.
8. Oryan A, Alemzadeh E, Tashkhourian J, Ana SFN. Topical delivery of chitosan-capped silver nanoparticles speeds up healing in burn wounds: A preclinical study. *Carbohydr Polym*. 2018;200:82-92.
9. Colombo M, Carregal-Romero S, Casula MF, Gutiérrez L, Morales MP, Böhm IB, et al. Biological applications of magnetic nanoparticles. *Chem Soc Rev*. 2012;41(11):4306-34.
10. Kim JH, Hong YC, Uhm HS. Synthesis of oxide nanoparticles via microwave plasma decomposition of initial materials. *Surf Coat Technol*. 2007;201(9-11):5114-20.
11. Cheraghipour K, Azarhazine M, Zivdari M, Beiranvand M, Shakib P, Rashidipour M, et al. Evaluation of scolicidal potential of salicylate coated zinc nanoparticles against *Echinococcus granulosus* protoscoleces. *Exp Parasitol*. 2023;246:108456.
12. Rasmussen K, Rauscher H, Mech A, Sintes JR, Gilliland D, González M, et al. Physico-chemical properties of manufactured nanomaterials—Characterisation and relevant methods. An outlook based on the OECD Testing Programme. *Regul Toxicol Pharmacol*. 2018;92:8-28.
13. Haase H, Overbeck S, Rink L. Zinc supplementation for the treatment or prevention of disease: current status and future perspectives. *Exp Gerontol*. 2008;43(5):394-408.
14. Sharma H, Kumar K, Choudhary C, Mishra PK, Vaidya B. Development and characterization of metal oxide nanoparticles for the delivery of anticancer drug. *Artif Cells Nanomed Biotechnol*. 2016;44(2):672-9.
15. Baker P, Charlton A, Johnston C, Leahy JJ, Lindegaard K, Pisano I, et al. A review of Willow (*Salix* spp.) as an integrated biorefinery feedstock. *Ind Crops Prod*. 2022;189:115823.
16. Shara M, Stohs SJ. Efficacy and safety of white willow bark (*Salix alba*) extracts. *Phytother Res*. 2015;29(8):1112-6.
17. Li J, Yin Y, Wang L, Liang P, Li M, Liu X, et al. Synthesis, characterization, and anti-inflammatory activities of methyl salicylate derivatives bearing piperazine moiety. *Molecules*. 2016;21(11):1544.
18. Valverde JM, Giménez MJ, Guillen F, Valero D, Martinez-Romero D, Serrano M. Methyl salicylate treatments of sweet cherry trees increase antioxidant systems in fruit at harvest

- and during storage. *Postharvest Biol Technol*. 2015;109:106-13.
19. Boucher HW, Corey GR. Epidemiology of methicillin-resistant *Staphylococcus aureus*. *Clin Infect Dis*. 2008;46(Suppl 5):S344-9.
 20. Cheraghipour K, Azarhazine M, Zivdari M, Beiranvand M, Shakib P, Rashidipour M, et al. Evaluation of scolicidal potential of salicylate coated zinc nanoparticles against *Echinococcus granulosus* protoscoleces. *Exp Parasitol*. 2023;246:108456.
 21. Short WD, Olutoye OO, Padon BW, Parikh UM, Colchado D, Vangapandu H, et al. Advances in non-invasive biosensing measures to monitor wound healing progression. *Front Bioeng Biotechnol*. 2022;10:952198.
 22. Bodo M, Settle T, Royal J, Lombardini E, Sawyer E, Rothwell SW. Multimodal noninvasive monitoring of soft tissue wound healing. *J Clin Monit Comput*. 2013;27(6):677-88.
 23. Islam NU, Jalil K, Shahid M, Rauf A, Muhammad N, Khan A, et al. Green synthesis and biological activities of gold nanoparticles functionalized with *Salix alba*. *Arab J Chem*. 2019;12(8):2914-25.
 24. Golbui Daghdari S, Ahmadi M, Dastmalchi Saei H, Tehrani AAJNJ. The effect of ZnO nanoparticles on bacterial load of experimental infectious wounds contaminated with *Staphylococcus aureus* in mice. 2017;4(4):232-6.
 25. Siddiqi KS, ur Rahman A, Husen A. Properties of zinc oxide nanoparticles and their activity against microbes. *Nanoscale Res Lett*. 2018;13(1):141.
 26. Ebrahimi R, Roudbari H, Parivor K, Badiei. Evaluation of the effects of zinc oxide nanoparticles on burn wounds in female Syrian mice. *Q J Med Sci*. 2015;25(4):257-62.
 27. Abbaszadeh A, Tehmasebi-Foolad A, Rajabzadeh A, Beigi-Brojeni N, Zarei L. Effects of chitosan/nano selenium biofilm on infected wound healing in rats; an experimental study. *Bull Emerg Trauma*. 2019;7(3):284.
 28. Qiu Z, Kwon AH, Kamiyama Y. Effects of plasma fibronectin on the healing of full-thickness skin wounds in streptozotocin-induced diabetic rats. *J Surg Res*. 2007;138(1):64-70.
 29. Yasin H, Mahmud S, Rizwani GH, Perveen R, Abrar H, Fatima K. Effects of aqueous leaves extract of *Holoptelea integrifolia* (Roxb) Planch on liver and kidney histopathology of albino rats. *Pak J Pharm Sci*. 2019;32(2).
 30. Cheraghipour K, Azarhazine M, Zivdari M, Beiranvand M, Shakib P, Rashidipour M, et al. Evaluation of scolicidal potential of salicylate coated zinc nanoparticles against *Echinococcus granulosus* protoscoleces. *Exp Parasitol*. 2023;246:108456.
 31. Jain PK, Huang X, El-Sayed IH, El-Sayed MA. Noble metals on the nanoscale: optical and photothermal properties and some applications in imaging, sensing, biology, and medicine. *Acc Chem Res*. 2008;41(12):1578-86.
 32. Gamer A, Leibold E, Van Ravenzwaay B. The in vitro absorption of microfine zinc oxide and titanium dioxide through porcine skin. *Toxicol In Vitro*. 2006;20(3):301-7.
 33. Rezaie A, Mohajeri D, Zarkhah A, Nazeri M. Comparative assessment of *Matricaria chamomilla* and zinc oxide on healing of experimental skin wounds on rats. 2012.
 34. Arslan K, Karahan O, Okus A, Unlu Y, Eryilmaz MA, Ay S, et al. Comparison of topical zinc oxide and silver sulfadiazine in burn wounds: an experimental study. *Ulus Travma Acil Cerrahi Derg*. 2012;18(5):376-83.
 35. Li J, Yin Y, Wang L, Liang P, Li M, Liu X, et al. Synthesis, characterization, and anti-inflammatory activities of methyl salicylate derivatives bearing piperazine moiety. *Molecules*. 2016;21(11):1544.
 36. Valverde JM, Giménez MJ, Guillen F, Valero D, Martinez-Romero D, Serrano M. Methyl salicylate treatments of sweet cherry trees increase antioxidant systems in fruit at harvest and during storage. *Postharvest Biol Technol*. 2015;109:106-13.
 37. Eming SA, Krieg T, Davidson JM. Inflammation in wound repair: molecular and cellular mechanisms. *J Invest Dermatol*. 2007;127(3):514-25.
 38. Dorsett-Martin WA. Rat models of skin wound healing: a review. *Wound Repair Regen*. 2004;12(6):591-9.
 39. Sorg H, Tilkorn DJ, Hager S, Hauser J, Mirastschijski U. Skin wound healing: an update on the current knowledge and concepts. *Eur Surg Res*. 2017;58(1-2):81-94.
 40. Rajakumari K. Skin wound healing: an update on the current knowledge and concepts. *Res J Pharm Technol*. 2019;12(3):1448-52.
 41. Ågren MS, Ostfeld U, Kallehave F, Gong Y, Raffn K, Crawford ME, et al. A randomized, double-blind, placebo-controlled multicenter trial evaluating topical zinc oxide for acute open wounds following pilonidal disease excision. *Wound Repair Regen*. 2006;14(5):526-35.
 42. Bodnar RJ. Epidermal growth factor and epidermal growth factor receptor: the Yin and

- Yang in the treatment of cutaneous wounds and cancer. *Adv Wound Care* (New Rochelle). 2013;2(1):24-9.
43. Martin JM, Zenilman JM, Lazarus GS. Molecular microbiology: new dimensions for cutaneous biology and wound healing. *J Invest Dermatol*. 2010;130(1):38-48.
 44. Brigelius-Flohe R, Aumann KD, Blöcker H, Gross G, Kiess M, Klöppel K, et al. Phospholipid-hydroperoxide glutathione peroxidase. Genomic DNA, cDNA, and deduced amino acid sequence. *J Biol Chem*. 1994;269(10):7342-8.
 45. Bucknall T. The effect of local infection upon wound healing: an experimental study. *Br J Surg*. 1980;67(12):851-5.
 46. Agar OT, Dikmen M, Ozturk N, Yilmaz MA, Temel H, Turkmenoglu FP. Comparative studies on phenolic composition, antioxidant, wound healing and cytotoxic activities of selected *Achillea L.* species growing in Turkey. *Molecules*. 2015;20(10):17976-8000.
 47. Phan TT, Wang L, See P, Grayer RJ, Chan SY, Lee ST. Phenolic compounds of *Chromolaena odorata* protect cultured skin cells from oxidative damage: implication for cutaneous wound healing. *Biol Pharm Bull*. 2001;24(12):1373-9.
 48. Lodhi S, Singhai AK. Wound healing effect of flavonoid rich fraction and luteolin isolated from *Martynia annua* Linn. on streptozotocin induced diabetic rats. *Asian Pac J Trop Med*. 2013;6(4):253-9.
 49. Li J, Yin Y, Wang L, Liang P, Li M, Liu X, et al. Synthesis, characterization, and anti-inflammatory activities of methyl salicylate derivatives bearing piperazine moiety. *Molecules*. 2016;21(11):1544.
 50. Barui AK, Veeriah V, Mukherjee S, Manna J, Patel AK, Patra S, et al. Zinc oxide nanoflowers make new blood vessels. *Nanoscale*. 2012;4(24):7861-9.
 51. Bartczak D, Muskens OL, Sanchez-Elsner T, Kanaras AG, Millar TM. Manipulation of in vitro angiogenesis using peptide-coated gold nanoparticles. *ACS Nano*. 2013;7(6):5628-36.
 52. Mukherjee S, Sriram P, Barui AK, Nethi SK, Veeriah V, Chatterjee S, et al. Graphene oxides show angiogenic properties. *Adv Healthc Mater*. 2015;4(11):1722-32.
 53. Augustine R, Dominic EA, Reju I, Kaimal B, Kalarikkal N, Thomas S. Electrospun polycaprolactone membranes incorporated with ZnO nanoparticles as skin substitutes with enhanced fibroblast proliferation and wound healing. *RSC Adv*. 2014;4(47):24777-85.
 54. Raghupathi KR, Koodali RT, Manna AC. Size-dependent bacterial growth inhibition and mechanism of antibacterial activity of zinc oxide nanoparticles. *Langmuir*. 2011;27(7):4020-8.
 55. Seil JT, Webster TJ. Antimicrobial applications of nanotechnology: methods and literature. *Int J Nanomedicine*. 2012;2767-81.
 56. Rahimi Kalateh Shah Mohammad G, Homayouni Tabrizi M, Ardalani T, Yadmani S, Safavi E. Green synthesis of zinc oxide nanoparticles and evaluation of anti-angiogenesis, anti-inflammatory and cytotoxicity properties. *J Biosci*. 2019;44:1-9.
 57. Rea S, Giles NL, Webb S, Adcroft KF, Evill LM, Strickland DH, et al. Bone marrow-derived cells in the healing burn wound—more than just inflammation. *Burns*. 2009;35(3):356-64.
 58. Chan B, Leong K. Scaffolding in tissue engineering: general approaches and tissue-specific considerations. *Eur Spine J*. 2008;17(4):467-79.