









The Effect of Nano Silver Particles of the Aqueous Extract of *Artemisia aucheri* on the Healing Process of Skin Wounds in Rats

Mohammad Mehdi Zangeneh¹, Akram Zangeneh², Navid Etemadi³✉, Seyyed Jamaledin Tabatabaei Aghda⁴, Mahtab Pourkamalzadeh³, Samira Zand³, Mohammad Abbaszadeh⁴, Reza Asadzadeh⁵

¹Biotechnology and Medicinal Plants Research Center, Ilam University of Medical Sciences, Ilam, Iran. E-mail: m.mehdizangeneh@yahoo.com

²DVM Graduate, Faculty of Veterinary Medicine, Urmia University, Urmia, Iran. E-mail: akramzangeneh@yahoo.com

³Department of Microbiology, Faculty of veterinary Medicine, Urmia University, Urmia, Iran. E-mail: etemadi.n@ymail.com

⁴Department of Food Hygiene and Quality Control, Faculty of Veterinary Medicine, Urmia University, Urmia, Iran. E-mail: aghda@ymail.com

⁵Assistant Professor of Nephrology, School of Medicine, Ilam University of Medical Sciences, Ilam, Iran.

Corresponding Author, DVM Graduate, Faculty of Veterinary Medicine, Urmia University, Urmia, Iran.

Article Info

Article type:

Original Article

Article History:

Received: 27 Jan 2023

Received in revised form:
20 March 2023

Accepted: 19 April 2023

Published online: 31 May
2023

Keywords:

AgNPs, Ointment, Skin
wound, Rat

Abstract

Objectives: One of the application areas of nanobiotechnology is the use of silver nanoparticles (Nanosilver particles) for a new solution in medical treatments. In the present study, the researchers investigate the effect of nano silver particles of the aqueous extract of *Artemisia aucheri* on skin wound healing among male rats.

Material and Methods: After creating wounds in 48 rats, they were randomly divided into 6 groups. Treated with 0.2% AgNPs ointment, 0.2% AgSO₄ ointment, 0.2% *A. aucheri* ointment, 3% tetracycline ointment, Eucerin basal ointment, and untreated control group. The tested groups were treated for ten days.

Results: Treatment with AgNPs ointment significantly increased the amount of vascular contraction, hexose amine and hydroxyproline, and fibrocyte and fibrocyte to fibroblast ratio. Also, in the mentioned group, the wound area and the total number of cells, neutrophils and lymphocytes decreased significantly compared to other groups.

Conclusion: The nano silver particles of the aqueous extract of *A. aucheri* accelerate the healing process of skin wounds and reduce the time required for complete wound healing.



Introduction

A wound refers to the disintegration of a continuous body structure as a result of damage caused by physical-chemical and biological factors [1]. Wound healing is a restoration process that occurs after Skin and soft tissues are damaged. After an injury occurs, an inflammatory response occurs and the cells under the dermis begin to increase collagen production, and then the epithelial tissue is gradually repaired [2]. Despite major advances in the treatment of surgical wounds, infection is one of the significant causes. It remains in mortality after surgery. Since the past, Egyptian, Greek, Indian, and European doctors have developed effective methods to treat wounds in the shortest time and with the least complications [3]. It is used again, each of which has many limitations and defects [4]. Currently, in Iran, antiseptic solutions such as betadine, acetic acid, washing with physiological serum, antibiotic ointments and hydrocortisone are used to treat wounds. While recent research shows that many disinfectant solutions such as betadine, acetic acid, iodophor, hydrogen peroxide are toxic to fibroblasts, lymphocytes and cells needed for wound healing. In traditional medicine, various efforts have been made to find a medicine to speed up wound healing, among which we can mention the use of gosangbin, ascorbic acid, chamomile, yellow patience, "Ba Daneh" and mummy to speed up the wound healing process [5-10] but due to the lack of introduction of a definitive drug to increase the speed of the wound healing process, studies on herbal medicines and their effect on the wound healing process are still ongoing. *Artemisia* (*Artemisia*) is an herbaceous plant that grows in different regions in Iran. Most of its species have a specific smell and taste that is caused by the monoterpene and sesquiterpene compounds in them. *Artemisia* is used medicinally in ancient medicine as a tonic, appetite stimulant, antiseptic, vasodilator and rheumatic pain treatment [11]. This medicinal plant has a substance called santonin, which has been considered the most famous anthelmintic drug for the digestive system for a long time [12] for various types of treatment, in addition to its anthelmintic activity. It has been proven to have many biological properties, such as microbicide, antifungal, virucidal, anti-parasitic, as well as analgesic properties, as well as antioxidant and vasodilation properties. *Ara* is a plant with a height of 25 to 25 cm and according to the studies it has flavonoid, santonin, coumarin compounds, bitter substances and volatile essential oil. Among the most widely used nanoparticles, after carbon nanotubes, are silver nanoparticles (Nanosilver particles), which have many uses in the field

of medicine [13]. Numerous studies have been conducted to know the antimicrobial effects of silver nanoparticles [14, 15] in nano-silver technology. Nanosilver technology is a material consisting of colloidal silver ions in a solution in the form of a suspension. Silver nanoparticles have special physical and chemical properties that help to increase their antimicrobial and wound healing properties. Therefore, in the present study, the effect of AgNPs on skin wound healing in male Wistar rats has been investigated.

Materials and Methods

Preparation of *Artemisia Aucheri*

To extract the fresh leaves of *Artemisia aucheri* in the spring season after the approval of the botanist, it was rinsed in the shade after washing with water and powdered by the electric mill. The extract was used using a brew that is consistent with its consumption. In this respect, 50 grams from the plant's Power to 500 ml of cross -water water and gently boil (heated) without boiling. After one hour heating and after cooling the mixture, using subtle fabric, the extract solution was separated. Then the solid was separated using the centrifugal of its solids. The extract was evaporated at the laboratory and the extract powder was kept in the refrigerator until used.

Preparation of AgNPs

Silver nanoparticles with average diameter of 5.4 nm were reproduced by Nasab Nasib Pars Tehran. Nanoparticle Size Analyzer Nanoparticle Size Analyzer, with regard to related information, including TEM and measuring.

Cutaneous Wound Healing Design

In this study, 48 Wistar male desert rats weighing 200 to 280 grams were used. The animals were kept at a temperature of 20 to 22 degrees Celsius under conditions of 12 hours of darkness and 12 hours of light. The animals had access to sufficient water and food except during wound creation and measurement. The tested rats were anesthetized by intramuscular injection of 40 mg/kg of ketamine. After the induction of anesthesia, the hair between the two shoulder blades was shaved and 3×3 of the area was disinfected with 70% alcohol and using a scalpel It caused a size (2×2 cm) wound that included the removal of all skin layers (Fig. 1). After creating wounds in the skin area, the rats were randomly divided into six groups including treatment with 0.2% AgNPs

ointment, treatment with 0.2% AgSO₄ ointment, treatment with 0.2% *Artemisia aucheri* ointment, treatment with 3% tetracycline ointment, treatment with Eucerin basal ointment, and untreated control. This ointment was placed on the wound bed every day for 10 days. Finally, after complete anesthesia with chloroform, the tested rats were sampled from the wound area. The histological sections were equally divided into two halves, one half of which was put in ten percent formalin. After staining with hematoxylin and eosin, the samples were examined with a light microscope, in which the total number of cells and blood vessels, fibrocytes, neutrophils, macrophages, lymphocytes, and fibroblasts were examined. In the other half of the samples, in order to biochemically check the amount of hydroxyproline and hexose amine.

Statistical Analysis

The mean of the values and standard deviations were used to describe the quantitative data. One-way ANOVA test was used to compare the variables in groups with each other, and in case of significant results, Duncan test was used. Data analysis was done using SPSS statistical software (ver.22), and data were considered significant at p-values $\leq .01$ about in vitro experiments and p-values $\leq .05$ about in vivo experiments

Results

In the recent experiment, the findings of wound area and contractures, total cell, and blood vessel revealed that AgNPs ointment significantly ($p \leq .01$) amended the above parameters at day 10 compared to the other groups (Tables 1 and 2). Angiogenesis is defined as formation of new capillaries from previous vessels. Angiogenesis is a controlled process that is rarely seen in adults except in instances of wound healing and menstrual cycle in women [16]. It is also a phenomenon that mostly occurs in the impaired areas, which is aimed at secreting cytokines in the vessels to repair tissues. Angiogenesis is higher in the early days, reaching its maximum level from days 15 to 20. This level is then reduced with complete withdrawal of cytokines and other tissue repair factors [17, 18]. In our study, AgNPs ointment increased significantly ($p \leq .01$) the number of fibrocyte, the concentration of hydroxyproline, hexuronic acid, and hexosamine and fibrocyte/fibroblast ratio at day 10 compared to the other groups (Tables 2 and 3). Fibroblasts are removed through the blood vessels formed at the wound site and are developed into fibrocytes after some time. The amount of fibroblast is

usually high until day ten. The main role of fibroblasts is making collagen. In fact, fibroblasts synthesize collagen, repair the external matrix, and facilitate the wound contraction process [19]. One of the methods of wound healing facilitation is use of fibroblast growth stimulant. It has been found that increasing the number of fibroblasts in the artificial skin leads to wound healing in in-vitro conditions. Fibroblasts synthesize some components of primary extracellular matrix of the wound bed such as fibronectin, hexosamine, and hexuronic acid, which provides a favorable ground for cell migration and proliferation. Fibroblasts then synthesize collagen, which provides tensile strength in the wound bed [20]. Fibrocytes are developed fibroblasts that have a higher ability in making collagen than fibroblasts. The more is the number of fibroblasts, the better is the wound healing [21]. Collagens are protein strains that are made of glycine, proline, and hydroxy proline amino acids. The amount of collagen is very low in the early (Fig. 2)

Table 1. The level of macroscopic parameters in experimental groups.

Parameters	Control	Basal ointment	Tetracycline ointment	AgSO ₄ ointment	A. Aucheri ointment	AgNPs ointment
Wound area (cm ²)	2.6 ± 0 ^c	2.5 ± 0 ^c	1 ± 0 ^a	1.8 ± 0 ^b	1.5 ± 0 ^b	0.8 ± 0.5 ^a
Wound contractures (%)	35 ± 0 ^c	37.5 ± 2 ^c	75 ± 0 ^a	55 ± 0 ^b	62.5 ± 0 ^b	80 ± 0.4 ^a

Non-identical letters reveal a notable shift between the experimental groups ($p \leq .05$)

The effect of nano silver particles of the aqueous extract of *Artemisia aucheri*

Table 2. The level of microscopic parameters in experimental groups.

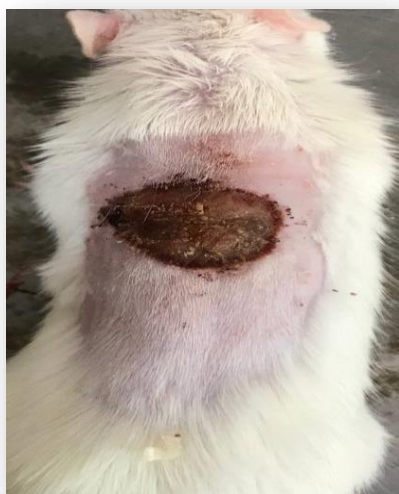Parameters	Control	Basal ointment	Tetracycline ointment	AgSO4 ointment	<i>A. Aucheri</i> ointment	AgNPs ointment
Total cell (n)	1470.8±21 ^d	1496.3±12 ^d	1115.3±16 ^a	1410.3±16 ^c	1198.9±18 ^b	1100.2±14 ^a
Vessel (n)	2.9±0.5 ^c	3.5±0.4 ^c	9.1±0.1 ^a	6.3±0.5 ^b	10.2±0.2 ^a	12.7±0.7 ^a
Fibrocyte (n)	4.4±0.2 ^c	4.1±0.1 ^c	10.6±0 ^a	7.4±0.3 ^b	10.8±0.1 ^a	12.1±0.2 ^a
Fibroblast (n)	21.6±0.4 ^b	20.7±0.2 ^b	27.5±1 ^a	20.6±0.8 ^b	28.9±0.4 ^a	31.6±0.1 ^a
Lymphocyte (n)	27.7±2 ^c	28.6±1 ^c	6.5±0 ^a	15.2±2 ^b	13.1±0 ^b	7.8±0.9 ^a
Macrophage (n)	5.8±0 ^a	5.4±0.03 ^a	5.6±0.1 ^a	5.7±0.2 ^a	5.3±0 ^a	4.8±0.1 ^a

Non-identical letters reveal a notable shift between the experimental groups ($p \leq .05$)

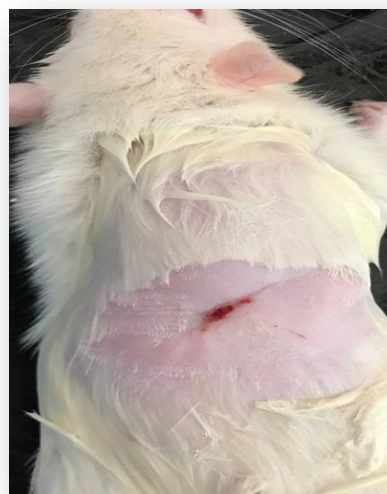Table 3. The level of biochemical parameters in experimental groups.

Parameters	Control	Basal ointment	Tetracycline ointment	AgSO4 ointment	<i>A. Aucheri</i> ointment	AgNPs ointment
Hydroxyproline (mg/g of tissue)	16.2±0.9 ^d	15.8±1 ^d	40.2±0 ^a	24.7±2 ^c	32.8±0.8 ^b	43.7±3 ^a
Hexosamine (mg/100 mg of tissue)	0.17±0.02 ^c	0.21±0.03 ^c	0.37±0.01 ^a	0.28±0 ^b	0.30±0.02 ^b	0.39±0.04 ^a

Non-identical letters reveal a notable shift between the experimental groups ($p \leq .05$)



(Fig. 1) One day after skin ulceration



(Fig. 2) ten day after skin ulceration and treated by nanoparticles

Various therapeutic effects of different species of the *A. aucheri* have been reported. The consumption of *A. aucheri* in the diet of hypercholesterolemic rabbits has reduced total cholesterol, LDL-cholesterol and

Discussion

triglycerides and increased HDL-cholesterol [22]. Also, it has anti-hepatitis B effects [23], anti-malarial parasite [24], anti-pain [25] and The treatment of asthma has been reported in different types of medicine. Since the efforts made so far to accelerate wound healing have definitely not led to the introduction of an effective drug and research is still ongoing in this field, in this study the effect of the *A. aucheri* medicinal on the healing process Skin wound in male mice The Wistar breed was examined. According to the investigations carried out so far, the effect of this plant on the wound healing process has not been reported. Our findings showed that the aqueous and alcoholic extract of the leaves of the healing plant reduced the surface of the wound on the fifth to the thirteenth day and the percentage of recovery During the fifth to the seventeenth day, the wound was more than the control group. Also, the low and high dose of the above *A. aucheri* reduced the time required for the complete healing of the wound by 19 and 28.6%, respectively, so that the time required for the complete healing of the wound in the group of the low dose of *A. aucheri* was 6.4 days on average and in the group The high dose of the plant was 9.6 days less than the control group. Although the time required for complete healing of the wound in the high dose of *A. aucheri* was less than the low dose, but this difference was not significant. Several studies on the effect of *A. aucheri* medicinal plant extracts or substances have reported on the process of skin wound healing, which is consistent with our research findings. It has been reported that Gsangbin topical ointment, yellow patience plant gel and mummy (26) when used topically on the skin wounds of laboratory animals have increased the speed of its repair. Also, the local consumption of the hydroalcoholic extract of the *A. aucheri* chamomile has been the cause of accelerating the healing of the burn wound in the laboratory desert mouse [7]. It has been reported that the topical ointment containing mucilage "to the grain" speeds up the healing of the wound [9]. There are several possible reasons for how the healing of skin wounds can be accelerated by fennel. Preventing wound infection and treating the wound with antibiotics accelerates the wound healing process [10] and it is reported that the fennel *A. aucheri* has It has antimicrobial effects [13, 14]. The analysis of the essential oil of the mountain herb has shown that this plant contains various compounds such as cement, sabinene, cineole, linalool, eugenol, borneol, farnesol, ester and other compounds. *A. aucheri* essential oil has microbiological property *Staphylococcus aureus*, *Streptococcus* and *Escherichia coli* are the most important factors of wound infection. Therefore, it is

possible to prevent this plant from causing infection and the growth of microorganisms due to the acceleration of the healing process be wounded Anti-inflammatory and antioxidant activity in many Varieties of heather, including mountain heather, have been reported [11] and modulating inflammation and using antioxidants accelerates wound healing [6, 8]. He deduced that the hydroalcoholic extract of *A. aucheri* leaves is a medicine Probably by reducing inflammation, gathering Free radicals and oxidant substances in the wound healing process has improved According to the findings of this research, aqueous-alcoholic extract *A. aucheri* accelerates the healing process of skin wounds And it reduces the time required for the complete healing of the wound. that silver nanoparticles by binding to different proteins can stimulate phagocytosis [27]. Kim and his colleagues also found that after inhalation toxicity of silver nanoparticles with a size of 18 nm for 90 days, these particles do not induce genetic toxicity in the bone marrow of rats [28]. Therefore, based on the studies, it can be said that the introduction of silver nanoparticles and silver ions into the body can increase the number of white blood cells for xenophagy [29]. In the present study, due to the complete healing of the wound on the fourteenth day, a significant increase White blood cells can be due to the presence of silver nanoparticles and silver ions released as a foreign substance inside the body that has stimulated the immune system. More studies to investigate the mechanism of effect and type The effective ingredient of the AgNPs is essential in the healing of skin wounds.

Conflicts of Interest

The authors hereby declare no conflicts of interest.

Authors` Contribution

All authors contributed in the experiments, analysis and preparation of this manuscript.

Funding/Support

Not Applicable.

References

1. Allahtavakoli M, Khaksari Haddad M, Assar Sh. Comparison of topical application of Mummify and Phenytoin cream on skin wound healing in rat. *J Babol Univ Med Sci* 2003; 5(18): 7-13. [20.1001.1.15614107.1382.5.2.1.6](https://doi.org/10.1001.1.15614107.1382.5.2.1.6)
2. Darvishi M, Omrani nava A, Karimi E, Nouri M, Meigooni SS, Hejripor SZ. Human and animal bites. *Caspian Journal of Environmental Sciences*, 2023; 21(2): 445-456. [doi: 10.22124/cjes.2023.6539](https://doi.org/10.22124/cjes.2023.6539)

3. B.S. Nayak, G. Isitor, E.M. Davis, G.K. Pillai, The evidence based wound healing activity of *Lawsonia inermis* Linn, *Phytother. Res.* 2007; 21: 827–831. doi: [10.1002/ptr.2181](https://doi.org/10.1002/ptr.2181).
4. D. Dwivedi M, Dwivedi S, Malviya V, Singh V. Evaluation of wound healing, antimicrobial and antioxidant potential of *Pongamia pinnata* in wistar rats, *J. Tradit. Complement. Med.* 2017; 7: 79–85. doi: [10.1016/j.jtcme.2015.12.002](https://doi.org/10.1016/j.jtcme.2015.12.002).
5. Jafari M, Kohandel A, Baghbani S, Tavili A, Zare Chahouki M, Malekian A. Comparison of chemical characteristics of shoot, root and litter in three range species of *Salsola rigida*, *Artemisia sieberi* and *Stipa barbata*. *Caspian Journal of Environmental Sciences*, 2011; 9(1): 37-46.
6. Freunscht P, Van Duyne RP, Schneider S. Surface-enhanced Raman spectroscopy of trans-stilbene adsorbed on platinum- or self-assembled monolayer-modified silver film over nanosphere surfaces. *Chemical Physics Letters.* 1997; 281(4): 372-8.
7. Shahmoradi MK, Amini Nogorani M, Mansouri F, Zarei L. Combination of zinc nanoparticles with chitosan scaffolds increased cytokine genes on wound healing of infected rats with methicillin-resistant *Staphylococcus aureus* (MRSA). *Advancements in Life Sciences.* 2023 May 23.
8. Dastyar N, Lysiuk R. Identification of the most important medicinal plants used for wound healing: An ethnobotanical study of Sistan and Baluchestan province, Southeastern Iran. *Journal of Biochemicals and Phytomedicine.* 2023; 2(1): 16–19. doi: [10.34172/jbp.2023.4](https://doi.org/10.34172/jbp.2023.4).
9. Lazarus GS, Cooper DM, Knighton DR, Margolis DJ, Pecoraro RE, Rodeheaver G, Robson MC. Definitions and guidelines for assessment of wounds and evaluation of healing, *Arch. Dermatol.* 1994; 130: 489–493.
10. H. Azhdari-Zarmehri, S. Nazemi, E. Ghasemi, Z. Musavi, Z. Tahmasebi, F. Farsad, A. Farzam, Assessment of effect of hydro-alcoholic extract of *scrophularia striata* on burn healing in rat, *JBUMS* 2014; 16: 42–48.
11. Indices of wound healing in chronic diabetic rat. *J Babol Univ Med Sci* 2005; 8(29): 12-21.
12. Jarrahi M, Emami Abarghuee M. Effect of Hydro-Alcoholic extract of *Matricaria chamomilla* L on burned wound healing in rat. *J Gorgan Uni Med Sci* 2008; 10(26): 22-26.
13. Jarrahi M, Zahedi M, Ajorlu M. Effect of *Aloe barbadensis* Miller on skin wound healing in rat. *J Gorgan Uni Med Sci* 2009; 11(29): 13-17. <http://goums.ac.ir/journal/article-1-456-en.html>
14. Johnston DE. Wound healing in skin, plastic and reconstructive surgery. *Vet Clinic North Am.* 1990; 20:1-45.
15. Park EJ, Yi J, Kim Y, Choi K, Park K. Silver nanoparticles induce cytotoxicity by a Trojan-horse type mechanism. *Toxicol In Vitro* 2010; 24: 872–8.
16. Quince mucilage on wound healing. *Iranian J Dermatology* 2006; 9(37): 260-263.
17. Rezvani ME, Roohbakhsh A, Allahtavakoli M, Shamsizadeh A. Anticonvulsant effect of aqueous extract of *Valeriana officinalis* in amygdala-kindled rats: possible involvement of adenosine. *J Ethnopharmacol* 2010; 127(2): 313-318. doi: [10.1016/j.jep.2009.11.002](https://doi.org/10.1016/j.jep.2009.11.002).
18. Sadeghi Fard H, Zareian P. Survey on analgesic effect of Hydro-alcoholic extract of *Artemisia aucheri* in two models of acute and chronic pain. *J Kordestan Univ Med Sci* 2008; 13(4): 30-36. <http://sjku.muk.ac.ir/article-1-98-en.html>
19. Said Fernández S, Ramos Guerra MC, Mata Cárdenas BD, Vargas Villarreal J, Villarreal Treviño L. In vitro antiprotozoal activity of the leaves of *Artemisia ludoviciana*. *Fitoterapia* 2005; 76(5): 466-468. doi: [10.1016/j.fitote.2005.04.009](https://doi.org/10.1016/j.fitote.2005.04.009).
20. Sarkar S, Jana AD, Samanta SK, Mostafa G. Facile synthesis of silver nano particles with highly efficient anti-microbial property. *Polyhedron.* 2007; 26: 4419-26. doi: [10.1016/j.poly.2007.05.056](https://doi.org/10.1016/j.poly.2007.05.056)
21. Sewall GK, Robertson KM, Connor NP, Heisey DM, Hartig GK. Effect of topical mitomycin on skin wound contraction. *Arch Facial Plast Surg.* 2003; 5:59-62. doi: [10.1001/archfaci.5.1.59](https://doi.org/10.1001/archfaci.5.1.59).
22. Souba WW, Wilmore D. Diet and nutrition in case of the patient with surgery. 9th ed, Baltimore: Williams and
23. Takenaka S, Karg E, Roth C, Schulz H, Ziesenis A, Heinzmann U, et al. Pulmonary and systemic distribution of inhaled ultrafine silver particles in rats. *Environ Health Perspect.* 2001 Aug; 109(4):547-51. doi: [10.1289/ehp.01109s4547](https://doi.org/10.1289/ehp.01109s4547)
24. Townsend CM. Sabiston textbook of surgery. 16th ed, New York: Oxford University Press; 2001:85-91.
25. Tsuda K, Nakatani T, Sugama J, Okuwa M, Sanada H. Influence of the timing of switching a protein-free to a protein-containing diet on the wound healing process in a rat all-layer skin defect. *Int*

- Wound J 2010; 7(3): 135-146.
[doi: 10.1111/j.1742-481X.2010.00674.x](https://doi.org/10.1111/j.1742-481X.2010.00674.x)
26. Wilkins Press; 1999:1589-1618.
27. Yoshimaru T, Suzuki Y, Inoue T, Niide O, Ra C. Silver activates mast cells through reactive oxygen species production and a thiol-sensitive store-independent Ca²⁺ influx. *Free Radic Biol Med* 2006; 40: 1949–59. [doi: 10.1016/j.freeradbiomed.2006.01.023](https://doi.org/10.1016/j.freeradbiomed.2006.01.023).
28. Zareian P, Zahiri Sh, Ketabchi F, Ruzmeh Sh. Effect of local *Tamarix monnifera* on skin wound healing process in rabbit. *J Mazand Univ Med Sci* 2007; 17(57): 48-57.
29. Zargari A. *Herbal plants*. 6th ed, Tehran: Tehran University Publisher; 1999. P 63