

Comparative evaluation of *Salvia rosmarinus* extract versus 10% neutral buffered formalin for spleen tissue fixation: morphological, microbiological, and biochemical assessment

Hossein Ghaderi¹ , Marzihe Havasi² , Marziyeh Darvish^{3,6} , Zahra Bakhtiary⁴ , Salman Soltani⁴ , Aref Nooraei⁴ , Faezhe Cheraghi⁵ , Muhammad Kurd⁵ 

¹ Department of Microbiology, Faculty of Veterinary Sciences, Ilam University, Ilam, Iran

² Department of Biochemistry, Faculty of Veterinary Medicine, Shahid Chamran University, Ahvaz, Iran

³ Department of Anatomy, School of medicine, Ilam University of Medical Sciences, Ilam, Iran

⁴ Department of Histology, Faculty of Veterinary Sciences, Ilam University, Ilam, Iran

⁵ Faculty of Veterinary Sciences, Ilam University, Ilam, Iran

⁶ Tuberculosis and Lung Diseases Research Center, Ilam University of Medical Sciences, Ilam, Iran

Article Info	ABSTRACT
<p>Article type: Original Article</p> <p>Article History: Received: 2025/11/27 Revised: 2025/12/24 Accepted: 2025/12/29 Published Online:</p> <p>✉ Correspondence to: Zahra Bakhtiary Aref Nooraei</p> <p>Email: z.bakhtiary@ilam.ac.ir a.nooraei@ilam.ac.ir</p>	<p>Objective: Tissue fixation is critical in histopathology for maintaining structural integrity. Despite its prevalence, the toxicity of 10% formalin has prompted the search for natural, non-toxic alternatives. Rosemary (<i>Salvia rosmarinus</i>), rich in phenolic and antioxidant compounds, presents a potential candidate for tissue preservation. This study evaluated the efficacy of methanolic rosemary extract as a fixative for sheep spleen tissue compared to standard formalin.</p> <p>Methods: Twenty-eight sheep spleen specimens were divided into four groups (n=7) and fixed in either methanolic rosemary extract or 10% formalin for 24 or 48 hours. Following fixation, tissues underwent routine processing and Hematoxylin and Eosin (H&E) staining. Histomorphometric analysis was performed to assess morphological preservation and cellular detail.</p> <p>Results: Histopathological evaluation revealed that rosemary extract provided acceptable structural preservation at both 24-hour and 48-hour intervals. The extract maintained the integrity of the capsule, white pulp, and red pulp, yielding results comparable to 10% formalin. Statistical analysis of cell counts showed no significant differences between the rosemary and formalin groups ($P > 0.05$). Notably, no evidence of autolysis or significant cellular degradation was observed in the rosemary-fixed samples.</p> <p>Conclusion: Methanolic rosemary extract serves as a viable, eco-friendly alternative for histological fixation, demonstrating comparable efficacy to formalin in preserving splenic architecture. While these results are promising for routine morphology, further research is required to evaluate its performance in immunohistochemistry and molecular applications, such as DNA/RNA preservation and PCR compatibility.</p> <p>Keywords: <i>Salvia rosmarinus</i>, Tissue, Fixation, Formalin</p>
<p>➤ How to cite this paper Ghaderi H, Havasi M, Darvish M, Bakhtiary Z, Soltani S, Nooraei A, Cheraghi F, Kurd M. Comparative evaluation of <i>Salvia rosmarinus</i> extract versus 10% neutral buffered formalin for spleen tissue fixation: morphological, microbiological, and biochemical assessment. <i>Plant Biotechnology Persa</i>. 2026; 8(2): Proof.</p>	

Introduction

The most crucial stage in tissue processing for the preparation of histopathological slides is tissue fixation, as this step is essential for preventing autolysis and the degradation of cellular and tissue structures [1]. Currently, formalin is the most widely utilized fixative in pathology laboratories [2]. The history of formalin as a fixative date back to the late 19th century. In 1868, August Wilhelm von Hofmann proposed a simple method for the production of formaldehyde from methanol and determined its molecular structure [3]. Simultaneously with the discovery of formaldehyde's properties by scientists, industrial engineers rapidly developed its commercial applications. This led to a high demand for the compound, and by 1891, the first patent for a large-scale production process was obtained in Germany [4]. As scientists gained broader access to formaldehyde, its medical applications were progressively uncovered. Between 1880 and 1890, its antiseptic properties were recognized [4], leading to promising experiments for clinical uses. In 1892, the French researcher Jean Auguste Trillat observed that formaldehyde hardened soft tissues and caused coagulation [5]. The following year, Ferdinand Blum, who was working intensively on the use of formaldehyde solutions in disinfection protocols, reported that the skin on his fingertips became notably thickened and impregnated after prolonged exposure. The preservative applications of these formaldehyde properties were quickly acknowledged, and by the mid-1890s, several scientists were experimenting with various solutions for anatomical and histological preparations [6-8]. Blum, one of the earlier pioneers, compared the effectiveness of formaldehyde with traditional preserving agents like alcohol [6]. By 1896, Blum demonstrated that formaldehyde was more effective in preserving the color and shape of tissues without affecting the microscopic structure of the preparation. Formalin possesses unique properties in stabilizing various body tissues. It is extensively used to preserve the morphology, antigenicity, and molecular characteristics of most tissues and has been accepted by the majority of pathologists following the standardization of its protocols [9]. Despite its unparalleled fixation qualities, numerous studies have confirmed the detrimental effects of formalin on human health. Li, Y. et al. showed that long-term

exposure to formalin causes damage to skin layers, eye damage, irritation and destruction of the respiratory mucosa, and genotoxic, neurotoxic, and reproductive toxicity [9]. Another study demonstrated that exposure to formalin, even at low doses, can impair learning and memory, and cause pathological changes in liver and lung tissue [10]. Crucially, formaldehyde has been classified as a Group 1 carcinogen by the International Agency for Research on Cancer (IARC) due to its association with nasopharyngeal carcinoma and leukemia [11]. Given the harmful effects of this substance on human health, and the fact that students, faculty, and staff in pathology, histology, and anatomy departments are subjected to long-term formalin exposure, it is imperative to seek an alternative fixative that can preserve tissue structures without negatively impacting human health. Over the past 20 years, several laboratories have attempted to replace formalin with other less toxic fixatives, but the results have often been unsatisfactory due to observed changes in cellular morphology and antigenicity [12]. Several studies have been conducted in the last decade to identify and evaluate safer and biocompatible alternatives to 10% buffered formalin (NBF) as the gold standard fixative in histopathology. In a comparative study, Bugshan et al. showed that the fixation properties of propolis at a concentration of 6.6% were statistically significantly better than fixation with 10% formalin. This finding confirms the potential of bioactive compounds in propolis as a tissue fixation agent. [13] in their evaluation entitled "Natural Sweeteners as Fixatives in Histopathology" showed that jaggery syrup offers acceptable fixation properties in preserving tissue morphology compared to formalin. In another comprehensive study that compared the fixation powers of jaggery, sucrose, honey and 20% Aloe vera extract vera), it was found that Aloe vera extract showed qualitatively better results than formalin in preserving tissue structure. Glyoxal, as a dialdehyde with lower toxicity and strong antimicrobial properties, has been introduced as one of the prominent chemical alternatives to formalin. Studies have shown that glyoxal formulations, especially the acid-free (GAF) type, show similar performance to formalin in preserving cellular structures for routine and advanced staining, while maintaining its antiseptic and fixing properties. Considering that the growth of microorganisms begins immediately after autopsy or biopsy, the ideal fixative

must also possess antifungal and antibacterial properties. One of the most important natural substances known for its antifungal and antibacterial activity is *Salvia rosmarinus* (formerly *Rosmarinus officinalis* L.), commonly known as rosemary [14]. *Salvia rosmarinus* belongs to the Lamiaceae (mint) family [15]. It exhibits a wide range of activities, including antifungal, antiviral, antibacterial, anti-inflammatory, antitumor, antithrombotic, analgesic, antidepressant, anti-ulcer, and antioxidant properties [16]. Due to its diverse characteristics, rosemary has also been widely utilized in the food and cosmetic industries. Specifically, studies have proven the preservative and anti-putrefaction properties of rosemary extract in meat, showing that it can delay tissue spoilage [17]. To date, the majority of research on natural fixatives has focused on sugar-based materials (such as honey or herbal syrups). While *Salvia rosmarinus* is widely known for its high concentration of polyphenols and antioxidants (such as carnosic acid and rosmarinic acid), there is little systematic evidence on the direct fixative capabilities of its methanolic extract on soft and complex tissues (such as spleen) under standard histopathological conditions. This study directly investigates for the first time the methanolic extract of *Salvia rosmarinus* as a tissue fixative. The extract offers a biocompatible and low-risk solution that can reduce the health risks associated with formalin.

Materials and Methods.

Tissue Preparation and Fixation

To compare the effects of formalin and rosemary extract on spleen tissue, 28 sheep spleens were obtained from a local slaughterhouse and immediately transferred to the pathology laboratory of the Faculty of Veterinary Sciences, Ilam University. After washing the samples, primary microbial cultures were performed to assess initial contamination. Then, 1 cm tissue samples were fixed in a ratio of 1:10 in 10% formalin or rosemary extract for two specific time periods: 24 hours and 48 hours. After the fixation stage, the samples underwent standard tissue processing, embedding, and sectioning. The resulting tissue sections were then stained with hematoxylin and eosin (H&E) for subsequent histopathological evaluation.

Preparation of Rosemary Extract

The powdered aerial parts of rosemary (100 g) were extracted using a Soxhlet apparatus with 1 L of 80% aqueous methanol (v/v) as solvent (plant-to-solvent ratio 1:10 w/v) at 70 °C for 8 h. The extraction was repeated twice with fresh solvent portions, and the combined extracts were filtered through Whatman No. 1 filter paper. The methanolic extract was concentrated under reduced pressure at 40 °C using a rotary evaporator until most of the solvent was removed. Residual solvent was further eliminated by drying the concentrate in a vacuum oven at 35 °C for 24 h until constant weight was achieved. The crude methanolic extract was obtained as a viscous semi-solid with a yield of $28.5 \pm 2.1\%$ (w/w) on dry weight basis [18-20].

Residual methanol content was verified by gas chromatography-mass spectrometry (GC-MS) following ICH Q3C guidelines, confirming levels below 50 ppm (permitted limit: 3000 ppm) (International Council for Harmonisation [21]).

The extract was reconstituted in dimethyl sulfoxide (DMSO) or phosphate-buffered saline (PBS) to prepare a stock solution of 100 mg extract/mL, followed by serial dilutions for subsequent assays. The final DMSO concentration in biological tests did not exceed 0.5% (v/v). [19]

Chlorophyll Removal from Extract

To improve the clarity and color of the extract for potential subsequent staining procedures, chlorophyll removal was performed:

- 1: Treatment: To 100 mL of the filtered rosemary extract, 0.5 grams of activated charcoal was added.
- 2: Mixing: The resulting mixture was stirred using a magnetic stirrer for 45 minutes at a temperature maintained between 30C- 35C
- 3: Filtration: The solution was then filtered through Whatman No. 1 filter paper to separate the activated charcoal. A visible color change in the extract from dark green to pale yellow was observed upon successful chlorophyll removal [22]. (Figure 1).



Figure 1: Removal of chlorophyll from the rosemary extract via activated charcoal treatment, demonstrating the visual color change from dark green to pale yellow/amber

Evaluation of Chlorophyll Removal

The light absorbance of the extract was measured both before and after chlorophyll removal using activated charcoal at wavelengths of 430 nm and 663 nm via a spectrophotometer. A significant decrease in absorbance at these specific wavelengths indicated the effective removal of chlorophyll [23]. (Graph 1).

Microbial Culture Method

Spleen samples from 28 clinically healthy sheep were aseptically collected after slaughter. Tissues were immediately transported to the Microbiology Laboratory at the Faculty of Veterinary Sciences, Ilam University, maintaining the cold chain.

Surface Sterilization

In the laboratory, the outer surface of the spleen was sterilized by searing with a hot spatula or flame to eliminate surface contamination. This is a standard technique in veterinary diagnostic protocols to minimize external contaminants while preserving internal tissue viability [24,25].

Aseptic Sampling

The seared area was incised using a sterile scalpel blade, and approximately 0.1-0.5 grams of inner tissue was aseptically excised.

Initial Inoculation

The excised tissues were immediately inoculated onto Blood Agar (supplemented with 5% defibrinated sheep blood), MacConkey Agar, and Brain Heart Infusion (BHI) broth [26,27].

Incubation

Inoculated media were incubated at 35–37°C for 24–48 hours under aerobic conditions, consistent with standard veterinary microbiology practices [26,27].

Fixation Setup

Blocks of approximately 1–2 cm³ from each spleen sample were transferred to separate tubes containing either 10% formalin and rosemary extract for tissue fixation.

Comparative Culture

Following fixation for 24, 48, and 72 hours, microbial reculture was performed from each fixed sample using the aforementioned media (Blood Agar, MacConkey Agar, and BHI broth). This step was designed to compare the relative efficacy of formalin versus rosemary extract in suppressing microbial growth during spleen tissue fixation. Evaluation was qualitative, based on the presence or absence of colony growth.

Tissue Fixation Method

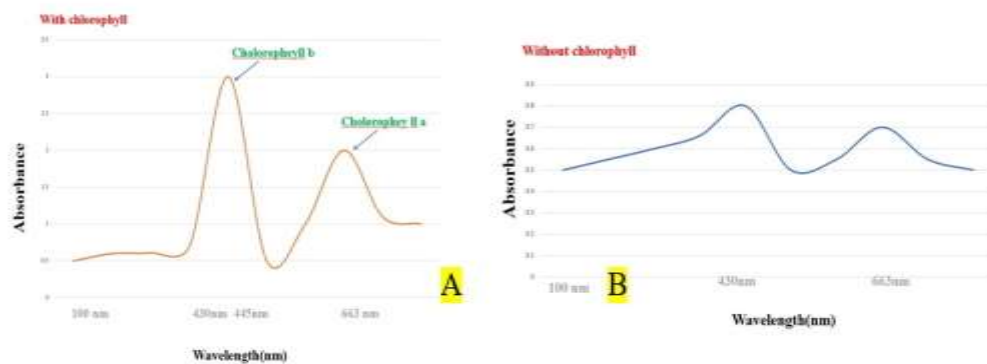
The studied samples were fixed for 24 hours and 48 hours in 10% formalin and rosemary extract. Subsequently, the fixed tissues were subjected to standard tissue processing using a tissue processor (P920 model, Poundab Company) and were molded to prepare paraffin blocks. Then, 5-7 μm thick sections were prepared using a microtome (DS9209 model), stained with H&E (hematoxylin and eosin), and subjected to histomorphometric examination under an

Olympus-CX light microscope (Truechome Metrics software).

Statistical analysis

Results

Results of Chlorophyll Removal from the Extract.



Graph 1: Spectrophotometric analysis of rosemary extract before and after chlorophyll removal. A: Before chlorophyll removal, the extract exhibited high optical density (OD) at wavelengths of 430 nm and 663 nm, characteristic of chlorophyll absorption. B: After chlorophyll removal using activated charcoal, the OD at both 430 nm and 663 nm significantly decreased, falling below 1, indicating effective chlorophyll elimination.

Microbiological Results

In the group fixed with formalin, no microbial contamination was observed across three consecutive days of microbial culture (Figure 2, A). Similarly, the microbial cultures performed at 24 hours and 48 hours following tissue sampling and fixation in rosemary extract indicated that the tissue samples could be successfully preserved in the extract (Figure 2, B and C). However, at the third day (72 hours) after fixation in the rosemary extract, the microbial culture confirmed the growth of bacteria in the fixed sample (Figure 2, D). Due to this finding, tissue processing (passage) was not performed on the third day for the rosemary extract group.




Figure 2: Microbial culture results comparing the preservative efficacy of formalin and rosemary extract over time. A. Microbial culture medium from the formalin-fixed group, showing no microbial growth (negative result). B. Microbial culture medium from the rosemary extract-fixed group after 24 hours, showing no microbial growth.

(negative result).C. Microbial culture medium from the rosemary extract-fixed group after 48 hours, showing no microbial growth (negative result).D. Microbial culture medium from the rosemary extract-fixed group after 72 hours, indicating microbial growth (positive result) characterized by the opacification of the culture medium

Histopathological Results

Histopathology evaluation was performed on hematoxylin and eosin (H&E) stained sections to assess the quality of tissue preservation in the rosemary extract groups compared to the standard formalin group (Figure 3).

Rosemary Group (R-24h)

The overall quality of the tissue was good. The pulp structure was well preserved, the nuclei were clear, and staining was successful. Importantly, no fixation

artifacts were observed and the morphological integrity of the tissue was preserved. (Figure, 3A)

Rosemary Group (R-48h)

The tissue quality remained good. The gross structure of the spleen was preserved, and the nuclei were completely distinct with no noticeable artifacts. A slight difference in the intensity of the hematoxylin or eosin staining was noted, resulting in a marginal fading of the nuclei and the overall spleen tissue. However, this minor change did not present any significant difference in terms of morphological diagnosis. (Figure3 B)

Formalin Group (F-24h and F-48h)

The structure of the splenic white and red pulp was excellently preserved. Nuclei were distinct, and the distinction between the red and white pulp was clear. The H&E staining was uniform. There were no significant signs of autolysis or empty spaces within the pulp observed. (Figure3 C. D)

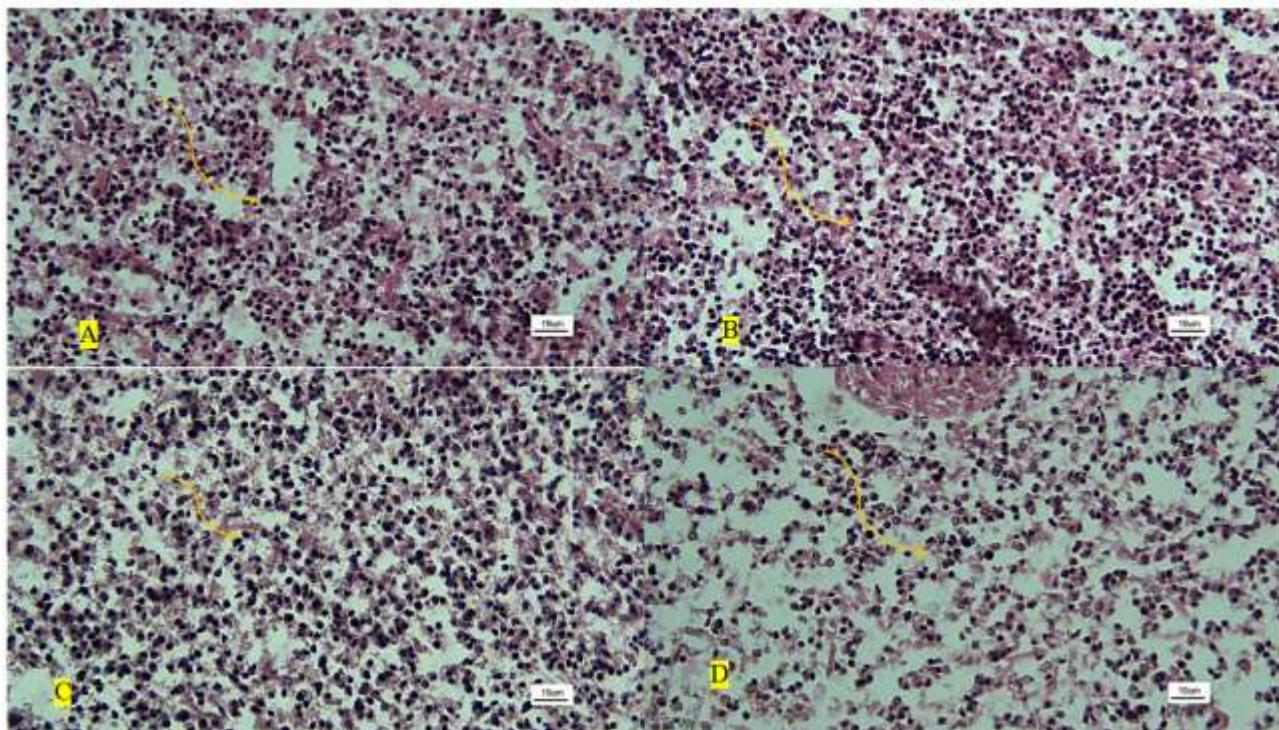


Figure 3: Lymphocytes in the splenic cords (yellow arrows) that were fixed, respectively, in rosemary solution for 24 h (A), rosemary solution for 48 h (B), formalin 10% for 24 h (C), and formalin 10% for 48 h (D). **H&E staining**

Quantitative histological results

In different groups, a 449 μm area was randomly selected in each group using ImageJ software and cell counting was performed. The results showed that there

was no statistically significant relationship between the different groups, indicating that both fixatives had no destructive effects on inflammatory cells (Figure 4). The results of cell counting are shown in Graph 2.

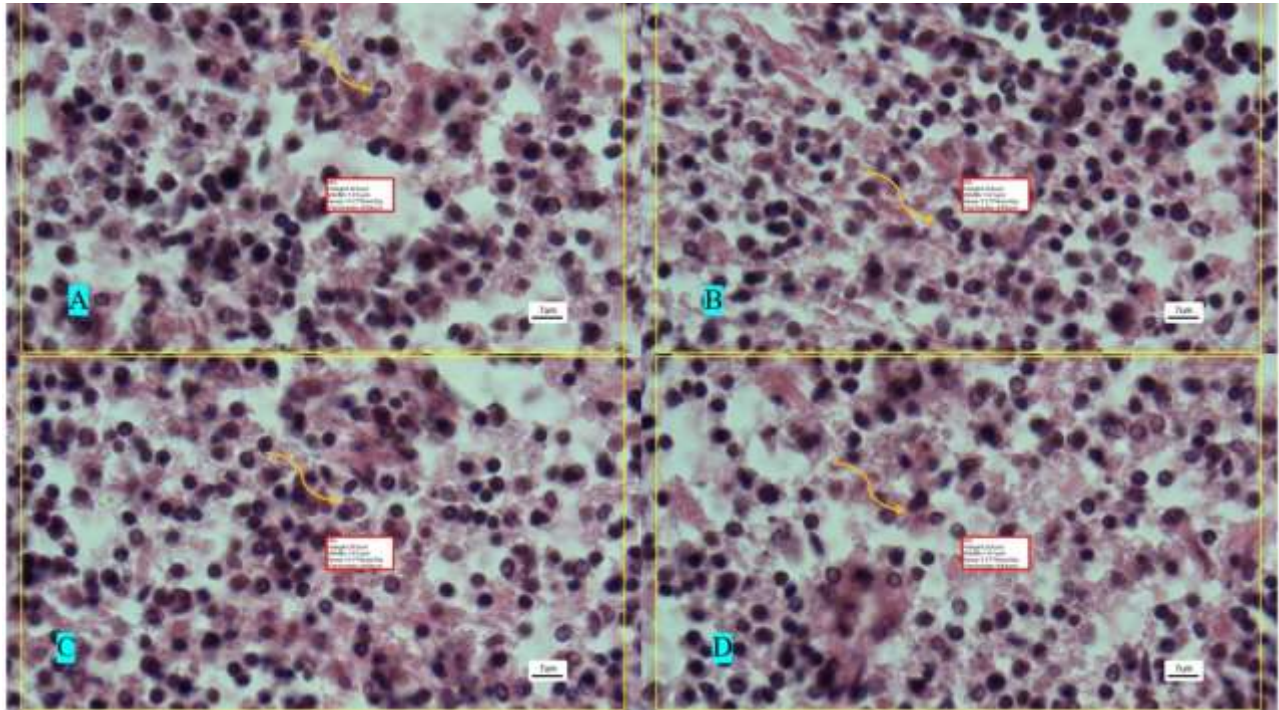



Figure 4: Cells in the splenic cords (yellow arrows) that were fixed, respectively, in rosemary solution for 24 h (A), rosemary solution for 48 h (B), formalin 10% for 24 h (C), and formalin 10% for 48 h (D). H&E staining.



Graph 2: The results of cell counting showed that there was no statistically significant difference between the different groups (ns).

Discussion

Formalin fixation is a complex procedure. While the initial penetration of formalin is extremely rapid, which effectively halts autolysis, the subsequent cross-linking process is slow, often requiring 24 to 48 hours for complete binding [28]. Furthermore, despite its widespread use, formalin is a known carcinogen. Over 90% of the world's formalin production is achieved through the modification of natural gas via the methanol synthesis route [29]. However, alternative production pathways have gained significance in recent years due to increasing pressure on the chemical industry to minimize its environmental footprint. Consequently, there is a growing trend toward using modified formalin or natural substances to replace it. The findings of this study indicate that using *rosemary* extract for tissue fixation may represent a viable alternative to formalin. Although the nuclei in the rosemary-fixed group appeared somewhat paler, the overall tissue morphology when compared with the formalin-fixed control did not show any statistically significant difference. Therefore, under the conditions of our study, rosemary extract performed satisfactorily; however, this should not yet be taken as

definitive evidence for completely replacing formalin. Over the past decades, there has been growing interest in non-formalin fixatives for histopathology, including natural compounds. A recent systematic review of natural fixatives such as honey, sugar, cane juice or jaggery found that many of these agents, in small tissue samples, can yield tissue morphology and staining quality that is comparable — and in some cases nearly equivalent — to formalin [30]. In the current study, a more open space was observed in the red pulp of the tissue samples. This observation aligns with our previous research, which demonstrated that splenic tissue fixed with different non-formalin fixatives resulted in wider, more patent spaces in the red pulp compared to those fixed with formalin [31]. Rosemary has been extensively studied for its antimicrobial activity against both Gram-negative and Gram-positive bacteria. The antimicrobial properties of rosemary extract have been proven against *Candida albicans*, *Staphylococcus aureus*, *E. faecalis*, *S. mutans*, and *P. aeruginosa* [32]. This activity is attributed to various compounds, including terpenes such as pinene, camphene, limonene, and eucalyptol [33]. Additionally, rosemary extract exhibits

antifungal properties [34]. This inherent antimicrobial and antifungal activity is crucial as it inhibits the growth of microorganisms, thereby contributing to effective tissue preservation. Numerous studies have substantiated the fixative effects of natural materials. Gotur, S. P. et al. demonstrated that sugarcane vinegar can successfully fix tissue samples [35]. Sugarcane vinegar is known to possess antimicrobial properties and antioxidant activity, both of which are also characteristic of rosemary extract. Bhattacharyya, A. et al., in a study investigating natural formalin substitutes, showed that fixation with jaggery (unrefined sugar) yielded tissue sections with good overall morphology, including well-preserved nuclear and cytoplasmic details, and excellent staining quality. Fixation using honey and ordinary sugar also demonstrated suitable morphology [36]. Scientific literature confirms that honey has possessed antibacterial, acidic, and dehydrating properties for centuries [37], making it a suitable potential fixative. Similarly, studies suggest that jaggery has cytoprotective and antioxidant activity [38]. The development of non-formalin fixatives is an urgent concern in histopathology due to formalin's health hazards and detrimental effects. Beyond natural substances, researchers are investigating chemical fixatives with lower toxicity. It was recently shown that the use of microwave energy with uniform internal heating can accelerate tissue fixation, offering a viable alternative to formalin [39]. In one study, N-vinyl-2-pyrrolidone (NVP) was found to effectively fix anatomical and tissue samples, and notably, it ameliorated the tissue hardening typically resulting from formalin fixation [40]. NVP is a monomer known for its biocompatibility, low cytotoxicity, and high hydrophilicity. One of its most important characteristics is its antimicrobial activity [41], which prevents bacterial growth and promotes better tissue stabilization. Vucevic, D. et al. created a fixative named Amber using a combination of low-potassium glucose-dextran, 10% honey, and 1% coconut oil. They showed that Amber preserves high-quality morphology without compromising the ability to perform Immunohistochemistry (IHC) or nucleic acid extraction [42]. The results of the present study, along with previous research, confirm that both natural and chemical substances can serve as effective alternatives to formalin in tissue fixation.

Conclusion

Replacing formalin (formaldehyde) in tissue fixation protocols with natural or less toxic materials is an important and desirable goal for improving laboratory safety and reducing environmental burden. Our preliminary findings indicate that rosemary extract may preserve overall tissue morphology sufficiently for routine histological evaluation under standard staining and light microscopy. Nevertheless, due to the limited sample size, absence of molecular (PCR) and immunohistochemical (IHC) data, and lack of long-term stability or penetration assessments, it is premature to assert that rosemary extract is a fully suitable alternative to formalin. Instead, we recommend a cautious, conditional conclusion: rosemary extract shows initial promise as a potential fixative, but further comprehensive studies — including molecular preservation assays, IHC, nucleic acid stability, long-term storage tests, and penetration/depth analyses are required before it can be recommended as a formalin substitute for diagnostic or research use.

Limitations

The tissue types examined in our study were limited to a specific category, and the sample set may not be representative of the full spectrum of tissue types or diverse pathological conditions. Therefore, caution should be exercised when generalizing these results to other tissues or clinical scenarios.

We did not perform PCR or immunohistochemistry (IHC) assays, therefore the capacity of rosemary-based fixation to preserve nucleic acids or antigenicity for further molecular analyses remains unknown.

The use of a methanolic or non-formalin extraction route might influence the chemical composition of the rosemary extract; such variation could affect fixation performance.

If chlorophyll was removed during extract preparation, this might alter fixative properties. The impact of chlorophyll removal (or presence) on extract composition and fixation efficiency has not been evaluated.

We did not compare our results with a broad panel of other established natural or synthetic non-formalin fixatives; thus, we cannot conclude that rosemary extract is superior or equivalent to the best available alternatives.

Author Contributions:

Conceptualization, Z.B., A.N.; methodology, H.GH., A.N. and M.H.; validation, A.N., S.S. and Z.B.; formal analysis, A.N., F.CH. and M.K.; resources, Z.B., H.GH. and A.N.; writing—original draft preparation, A.N. and S.S.; writing—review and editing, Z.B.; visualization, A.N. and Z.B.; project administration, A.N.

Funding

This research received no external funding.

Institutional Review Board Statement

No applicable.

Informed Consent Statement

No applicable.

Data Availability Statement

The original contributions presented in this study are included in the article. Further inquiries can be directed to the corresponding author.

Conflicts of Interest

The authors declare no conflicts of interest.

References

- Comanescu M, Annaratone L, D'Armento G, Cardos G, Sapino A, Bussolati G. Critical steps in tissue processing in histopathology. *Recent Pat DNA Gene Seq.* 2012;6:22–32. doi: 10.2174/187221512799303207
- Munari E, Scarpa A, Cima L, Pozzi M, Pagni F, Vasuri F, et al. Cutting-edge technology and automation in the pathology laboratory. *Virchows Arch.* 2024;484:555–566. doi: 10.1007/s00428-023-03713-1
- Hofmann AW. Zur Kenntniss des Methylaldehyds. *Ber Dtsch Chem Ges.* 1896;2:152–159. doi: 10.1002/cber.18690020172
- Musiał A, Gryglewski RW, Kielczewski S, Loukas M, Wajda J. Formalin use in anatomical and histological science in the 19th and 20th centuries. *Folia Med Cracov.* 2016;56(3):31–40. **PMID: 28275234**
- Trillat A. Sur les propriétés antiseptiques de la formaldehyde. *C R Acad Sci.* 1892;114:1278–1281.
- Blum F. Notiz über die Anwendung des Formaldehyds (Formol) als Härtungs- und Konservierungsmittel. *Anat Anz.* 1894;9:229–231.)
- Fish PA. The use of formalin in neurology. *Trans Am Microsc Soc.* 1896;17:319–330. doi: 10.2307/3221343
- Cullen TS. A rapid method of making permanent specimens from frozen sections by the use of formalin. *Johns Hopkins Hosp Bull.* 1895;6:67.
- Li Y, Ou J, Huang C, Liu F, Ou S, Zheng J. Chemistry of formation and elimination of formaldehyde in foods. *Trends Food Sci Technol.* 2023;139:104134. doi: 10.1016/j.tifs.2023.104134
- Cheng J, Zhang L, Tang Y, & Li Z. The toxicity of continuous long-term low-dose formaldehyde inhalation in mice. *Immunopharmacology and immunotoxicology.* 2016;38(6):495–501. doi: 10.1080/08923973.2016.1235183
- European Food Safety Authority. Endogenous formaldehyde turnover in humans compared with exogenous contribution from food sources. *EFSA J.* 2014;12:3550. doi: 10.2903/j.efsa.2014.3550
- Paavilainen L, Edvinsson Å, Asplund A, Hober S, Kampf C, Pontén F, et al. The impact of tissue fixatives on morphology and antibody-based protein profiling in tissues and cells. *J Histochem Cytochem.* 2010;58:237–246. doi: 10.1369/jhc.2009.954339
- Patil S, Rao RS, Ganavi BS, & Majumdar B. Natural sweeteners as fixatives in histopathology: A longitudinal study. *Journal of natural science, biology, and medicine.* 2015;6(1):67. doi: 10.4103/0976-9668.149086
- de Macedo LM, Santos ÉMD, Militão L, Tundisi LL, Ataíde JA, Souto EB, et al. Rosemary (*Rosmarinus officinalis* L., syn *Salvia rosmarinus*) and its topical applications: a review. *Plants.* 2020;9:651. doi: 10.3390/plants9050651
- Al-Sereiti MR, Abu-Amer KM, Sen P. Pharmacology of rosemary (*Rosmarinus officinalis* Linn.) and its therapeutic potentials. *Indian J Exp Biol.* 1999;37:124–130. **PMID: 10641152**
- Begum A, Sandhya S, Vinod KR, Reddy S, Banji D. An in-depth review on the medicinal flora *Rosmarinus officinalis* (Lamiaceae). *Acta Sci Pol Technol Aliment.* 2013;12:61–74. **PMID: 24584323**
- Lorenzo JM, Munekata PE, Pateiro M, Domínguez R, Alaghabari M, Tomasevic I.

- Preservation of meat products with natural antioxidants from rosemary. *IOP Conf Ser Earth Environ Sci.* 2021;854:012053. doi: 10.1088/1755-1315/854/1/012053
18. Andrade JM, Faustino C, Garcia C, Lemos D, & Comunian TA. Rosemary as functional ingredient in food: Extraction techniques and potential applications. *Food Science and Technology International.* 2018;24(5):417–428. doi: 10.1177/1082013218771440
 19. Mena P, Cirlini M, Tassotti M, Herrlinger KA, Dall'Asta C, Del Rio D. Phytochemical profiling of flavonoids, phenolic acids, terpenoids, and volatile fraction of a rosemary (*Rosmarinus officinalis* L.) extract. *Molecules.* 2016;21:1576. doi: 10.3390/molecules21111576
 20. del Pilar Sánchez-Camargo A, Herrero M. Rosemary (*Rosmarinus officinalis*) as a functional ingredient: recent scientific evidence. *Curr Opin Food Sci.* 2017;14:13–19. doi: 10.1016/j.cofs.2017.02.007
 21. International Council for Harmonisation. Impurities: guideline for residual solvents Q3C (R5). *ICH Guideline.* 2005;4:1–25.
 22. Lu Y, Foo LY. Antioxidant activities of polyphenols from sage (*Salvia officinalis*). *Food Chem.* 2001;75:197–202. doi: 10.1016/S0308-8146(01)00198-4
 23. Viuda-Martos M, El Gendy AENG, Sendra E, Fernández-López J, Abd El Razik KA, Omer EA, et al. Chemical composition and antioxidant and anti-*Listeria* activities of essential oils obtained from some Egyptian plants. *J Agric Food Chem.* 2010;58:9063–9070. doi: 10.1021/jf1014416
 24. Riedel S. The value of postmortem microbiology cultures. *J Clin Microbiol.* 2014;52(4):1028–1033. doi: 10.1128/JCM.03102-13
 25. Witherell K, White L, Shaw L, et al. Utility of postmortem bacterial culture of abdominal organs at autopsy of young calves. *J Vet Diagn Invest.* 2023;35(2):182–186. doi: 10.1177/10406387221147558
 26. Clinical and Laboratory Standards Institute. Performance standards for antimicrobial disk and dilution susceptibility tests for bacteria isolated from animals. 7th ed. CLSI supplement VET01S. 2024.
 27. Aiello SE, Moses MA, editors. *The Merck Veterinary Manual.* 11th ed. 2016.
 28. Buesa RJ. Histology without formalin? *Ann Diagn Pathol.* 2008;12:387–396. doi: 10.1016/j.anndiagnpath.2008.07.004
 29. Bertau M, et al. Methanol utilisation technologies. In: *Methanol: The Basic Chemical and Energy Feedstock.* Springer; 2014. doi: 10.1007/978-3-642-39709-7_5
 30. Yee AWM, Oo PS, Aye SN, Lim WJ, Chee VCX, Krishnappa P. Natural fixatives alternative to formalin in histopathology: a systematic review. *Med J Malaysia.* 2023;78:98–108. PMID: 36710488
 31. Mirzaei M, Eshaghi-Gorji R, Fani F, Karimpour Malekshah A, Talebpour Amiri F. Comparative evaluation of the effect of three types of fixatives (formalin, Bouin and Carnoy) on histomorphological features of various viscera. *Anat Histol Embryol.* 2023;52:882–889. doi: 10.1111/ahc.12948
 32. Albalawi A, Alhasani RHA, Biswas L, Reilly J, Shu X. Protective effect of carnosic acid against acrylamide-induced toxicity in RPE cells. *Food Chem Toxicol.* 2017;108:543–553. doi: 10.1016/j.fct.2017.08.026
 33. Aziz E, Batool R, Akhtar W, et al. Rosemary species: a review of phytochemicals, bioactivities and industrial applications. *South African Journal of Botany.* 2022;151:3-18. doi: 10.1016/j.sajb.2022.05.059
 34. Meccatti VM, Oliveira JRD, Figueira LW, et al. *Rosmarinus officinalis* L. (rosemary) extract has antibiofilm effect similar to the antifungal nystatin on *Candida* samples. *An Acad Bras Cienc.* 2021;93:e20190366. doi: 10.1590/0001-3765202120190366
 35. Gotur SP, Kamarthi N, Wadhwan V. Sirka: an alternative to the formalin fixative. *Indian J Pathol Microbiol.* 2024;67:238–241. doi: 10.4103/ijpm.ijpm_280_22
 36. Bhattacharyya A, Gupta B, Singh A, Sah K, Gupta V. Probing natural substitute for formalin: comparing honey, sugar, and jaggery syrup as fixatives. *Natl J Maxillofac Surg.* 2018;9:14. doi: 10.4103/njms.NJMS_52_17
 37. Al-Maaini R, Bryant P. The effectiveness of honey as a substitute for formalin in the histological fixation of tissue. *J Histotechnol.* 2006;29:173–176. doi: 10.1179/his.2006.29.3.173
 38. Nayaka MH, Sathisha UV, Manohar MP, Chandrashekar KB, Dharmesh SM. Cytoprotective and antioxidant activity studies of jaggery sugar. *Food Chem.* 2009;115:113–118. doi: 10.1016/j.foodchem.2008.12.015
 39. Shashidara R, Sridhara SU. Kitchen microwave-assisted accelerated method for fixation and processing of oral mucosal biopsies: a pilot study. *World J Dent.* 2012;2:17. doi: 10.5005/jp-journals-10015-1123
 40. Haizuka Y, Nagase M, Takashino S, Kobayashi Y, Fujikura Y, Matsumura G. A new substitute for formalin: application to embalming cadavers. *Clin Anat.* 2018;31:90–98. doi: 10.1002/ca.23005

41. Gupta S, Puttaiahgowda YM. N-vinylpyrrolidone antimicrobial polymers: current trends and emerging perspectives. *Eur Polym J.* 2022;180:111590. doi: 10.1016/j.eurpolymj.2022.111590
42. Vucevic DD, Seidman MA, Mesaki K, et al. A novel tissue preservation and transport solution as a substitute for formalin. *Lab Invest.* 2023;103:100198. doi: 10.1016/j.labinv.2023.100198