



Assessment of the Wound Healing Property of Aqueous Extract of *Stevia Rebaudiana*: an Ethnomedicinal Plant

Naser Abbasi¹, Hori Ghaneialvar^{1,2}, Sania Saneei³, Mohammad Mahdi Zangeneh^{1*}, Akram Zangeneh^{1*}

¹Biotechnology and Medicinal Plants Research Center, Ilam University of Medical Sciences, Ilam, Iran

²Department of Clinical Biochemistry, Faculty of Medicine, Ilam University of Medical Sciences, Ilam, Iran

³Department of Dermatology, School of Medicine, Kermanshah University of Medical Sciences, Kermanshah, Iran

Article Info

*Correspondence to:

Mohammad Mahdi Zangeneh,
Akram Zangeneh
m.mehdizangeneh@yahoo.com,
akramzangeneh@yahoo.com

Article History:

Received: 01 March 2021

Accepted: 24 Sep 2021

ePublished: : 09 Oct 2021

Keywords: *Stevia rebaudiana*,
Extract, Wound healing
property, Rat

Abstract

Ethnomedicinal plants are considered as the recent resources for producing components to heal wounds. Stevia rebaudiana is a native plant in Iran, which has been used as an anti-inflammatory, antioxidant, antibacterial, antifungal, antiparasitic, antiviral, and antidiabetic agent. In this study, the authors describe the property of aqueous extract of S. rebaudiana on wound healing markers in Sprague-Dawley male rats. Full-thickness excisional wounds (2 × 2 cm) was induced on the back of 32 rats. In this study, rats were randomly divided into four main groups (n=8), untreated (control) and treated with 1ml basal cream, 1ml tetracycline (3%), and 1ml S. rebaudiana aqueous extract 10% for 10 days. Animals of each group were euthanized at 10 days post-injury (DPI) and wounds were assessed through gross and histopathological analyses. Treated animals with S. rebaudiana demonstrated a considerable decrease in the wound area during the experiment compared to control, basal cream, and tetracycline groups. Parameters such as healing tissue alignment and epithelialization indicated substantial changes when compared to other groups. Moreover, treatment with S. rebaudiana decreased the number of wound surface area, lymphocytes, and macrophages, it increased the number of blood vessels and

fibrocytes compared to other groups at 10 days. Thus, the present research shows the wound healing effect of the S. rebaudiana, suggesting to be used as a therapeutic supplement. Additional in vivo researches and clinical trials would be needed to justify the findings.

How to cite this paper

Abbasi N, Ghaneialvar H, Saneei S, Zangeneh MM, Zangeneh A. Assessment of the wound healing property of aqueous extract of *Stevia rebaudiana*: An ethnomedicinal plant. *Plant Biotechnology Persa* 2021; 3(1): 9-17.

Introduction

Wound healing is a hemostatic mechanism to return physiological balance, including restoration of the damaged structures by complex interactions between reconstruction and inflammatory cells [1]. There are three main phases for healing wounds in the injured area; (I) inflammatory phase, (II) proliferative phase and (III) remodeling phase. The aims of wound caring include reducing of the risk agents that prevent wound healing, enhancing the healing mechanism and extenuating the incidence of infections of wound [1, 2]. Several factors can lead to impaired wound healing. In general terms, the factors that affect repair can be categorized into local and systemic. Local factors are those (Oxygenation, infection, foreign body, venous, sufficiency) that directly affect the characteristics of the wound itself, while systemic factors (Age, gender, sex hormones, stress, ischemia, diseases, obesity, medications, smoking, immunocompromised conditions, nutrition) are the overall health or disease state of the individual that influence his or her ability to heal [2]. The study on wound healing factors is one of the advanced fields in new biomedical sciences. The enormous costs of modern medicines demonstrate that alternative strategies are needed for better management of wounds and their related problems [2-5].

Plants are popular remedies applied by a majority of the world's population. Ethnomedicinal plants as a rich source of medicinal compounds have continued to play a distinguished role in the maintenance of human health against several disorders. The impression of medicinal plants in prohibit and remedy of diseases is irrecusably [6, 7]. Furthermore, the doubtful performance and side effects of chemical supplements such as sulfa antibiotics, silver sulfadiazine and

santyl are worrying for the medical community world and people. Therefore, the utilization of natural medicinal plant has been widely welcomed [8-10].

Phytochemical studies have attracted the consideration of plants researchers due to the development of new methods. Types of extraction methods had a high effect on the medicinal properties of obtained extracts [11]. One of extraction methods of compounds of medicinal plant is using of water, which the produced extract is called aqueous extract. Aqueous extracts could be extracted from different parts like roots, stems, leaves, and flowers. Aqueous extracts are source of antioxidant and anti-inflammatory compounds [10, 12]. In recent years, interest in aqueous extracts of plants has been increased for pharmacological studies which claim that the plant extracts have useful properties for preventing and treatment of several human diseases [12]. Because of the vast amount of triterpenes, saponins, flavonoids, alkaloids and tannins in the aqueous extract of medicinal plants, they have been applied in cure of cutaneous wounds to enhance the rate of healing [13-16].

Animal studies of various plant species have generated promising results. For example, *Leea macrophylla* has healing effects. It increases the synthesis of collagen, stimulates the production of antioxidants, reduces the levels of proinflammatory factors, and improves cell proliferation [16]. *Wrightia tinctoria* presented healing activity, with an increase in the contraction rate of induced lesions [16]. *Pereskia aculeata* accelerated the cicatricial process by increasing blood flow and collagen deposition [16c]. An ointment from *Struthanthus vulgaris* stimulated the closure of lesions, stimulated the formation of granulated tissue, and

stimulated the proliferation and organization of collagen fibers [16]. *Cynodon dactylon* presented antioxidative activity and stimulated collagen formation and healing [16]. *Caesalpinia mimosoides* stimulated reepithelialization of the epidermal layer and the contraction of lesions [16].

There are several medicinal plants in Iran that increase rate of cutaneous wound healing. A list of Iranian medicinal plants that consumed for their healing activities on cutaneous wounds including *Achillea millefolium*, *Aloe vera*, *Arnebia euchroma*, *Avocado*, *Camellia Sinensis*, *Equisetum arvense*, *Eucalyptus*, *Falcaria vulgaris*, *Hamamelis virginiana*, *Lawsonia inermis*, *Lotus corniculatus*, *Matricaria chamomilla*, *Prosopis farcta*, *Silybum marianum*, *Teucrium polium*, *Verbascum Thapsus*, *Urtica dioica* [17, 18].

One of the most important herbal medicines widely consumed in Kermanshah in the west of Iran, is *Stevia rebaudiana* from order Asterales, Asteraceae family, Eupatorieae tribe, *Stevia* genus. *S. rebaudiana* is usually Cultivate for its sweet leaves, which are the sources of steviol glycosides (mainly rebaudioside and stevioside) [19]. *S. rebaudiana* 250–300 times the sweetness of sugar, so it is used in industry as a sweetener additive [20]. *S. rebaudiana* has been used since ancient times in traditional medicines to treat diabetic, gastric ulcers, cancer and microbial disease, however there is a deficient evidence that it is advantageous to treat skin wounds [21, 22].

Based on the knowledge of the authors, in comparison to many other pharmaceutical-industrial plants, there is very little data about the wound healing activity of *S. rebaudiana* aqueous extract collected from Kermanshah province, west of Iran. Hence, the aim of the recent study was the evaluation of property of the aqueous extract of *S. rebaudiana* on wounds healing in male rats.

Materials and Method

Plant sample collection and Preparation of aqueous extract

In this study, medicinal plant collected from Kermanshah city in October 2017. To obtain the aqueous extract of the plant, 250 gr of the dried branches of the *S. rebaudiana* leaves were poured in a container containing 2000 mL boiled water, and the container lid was tightly closed for 4 h. Then, the container's content was filtered, and the remaining liquid was

placed on a bain-marie to evaporate. Finally, a tar-like material was obtained, which was powdered by a freeze dryer.

Wound creation and Study design

All animal procedures were approved by standards of the Payame Noor University of Kermanshah (No. 01/Z/G 1395/12/01) on Humane Care and Use of Laboratory Animals, by the Research Ethics Committee of the Ministry of Health and Medical Education in Iran (adopted on April 17, 2006), based on the Helsinki Protocol (Helsinki, Finland, 1975).

Thirty two male Sprague-Dawley rats weighing 200–220 g were applied. The animals were housed at 25 ± 3 °C temperature and 12:12 h light-dark and fed with standard pellet diet and water ad libitum conditions (standard environmental and nutritional) during the study [8]. The animals were anesthetized by intraperitoneal injection of 1mg/kg xylazine HCl (Xylazine 2%; Alfasan) as premedication, and 60 mg/kg ketamine HCl (Ketamine 5%; TRITTAU, Germany) for anesthesia ratio of 1 to 3 respectively [8]. Under sterile conditions, a square shape full-thickness incision of 2×2 cm was made in the cervical region skin of the back of rats and the incised piece was removed. The wound was left undressed and no local or systemic antiviral, antiparasitic, antifungal and antibacterial factors were applied [8].

After wounding, the animals were randomly divided into four equal groups (n=8), representing 10 days after injury. The groups were enumerated as follows:

(1) Control: In the control group, no material was used in the skin injured area, which was left uncovered.

(2) Basal cream: In the basal cream group, the skin injured area was covered with 1ml basal cream (eucerin) daily, for 10 days post-injury (DPI)

(3) Tetracycline: In the tetracycline group, the skin injured area was covered with 1ml basal cream and tetracycline (3%) daily, for 10 DPI

(4) *S. rebaudiana* aqueous extract 10%: In *S. rebaudiana* group the skin injured area was covered with 1ml *S. rebaudiana* aqueous extract 10% (10 g *S. rebaudiana* were suspended in 90 g eucerin) for 10 DPI.

Sample collection and histological evaluation

At the end of 10 DPI, the animals were euthanized by intraperitoneal injection of 1mg/kg xylazine HCl and

60mg/kg ketamine HCl ratio of 1 to 3 respectively, and sampling was done [8]. Full thickness skin samples from the wound site including dermis, epidermis and subcutaneous were carefully dissected. After 72h fixation, the samples were embedded in paraffin and sections (5 µm thicknesses) were prepared. Then, they were stained by hematoxyline and eosin stain and studied with a routine light microscope.

The twenty pictures were taken from every tissue sample in all groups by a digital camera (Dino capture; version 1.2.7) and transferred to the computer software (Photoshop CS-4; Adobe) for digital analysis. The criteria that were investigated in histopathological sections consisted of epithelialization, cornification of the epithelium, fibrin deposition,

hemorrhage, mononuclear cell and polymorphonuclear cell infiltration, revascularizations, necrosis, presence of fibroblasts, fibrocytes, maturation and organization of collagen. The number of fibrocytes, fibroblasts, neutrophils, lymphocytes, and macrophages (magnification×800) and total cells and blood vessels (magnification ×200) of the injured area were counted and their mean and standard deviations were computed [23].

The empirical results were expressed as means ± SD. Statistical comparison among the groups was made using one- way ANOVA followed by Tukey's post-hoc test. P value less than 0.05 was considered significant.

Results

A total of 32 rats were used in the study, with each group containing 8 rats. On day ten post-injury, the wounds exhibited the formation of a scar covering thick granulation tissue in all rats. However, treatment with *S. rebaudiana* produced more scar tissue than other groups when examined macroscopically. No re-epithelialization was evident in the control, basal cream and tetracycline groups, while rats in the *S. rebaudiana* group indicated minimal re epithelialization.

Simultaneously, less cellularity, perivascular edema and fibrin deposition and more collagen fibers were observed in *S. rebaudiana* wounds compared with the other groups.

The wounds rendered the formation of a scar covering a thick granulation tissue in all rats; but, treatment with *S. rebaudiana* yield more scar tissue than other groups. Also, in table 1 indicated that *S. rebaudiana* reduced wound surface area (cm²) in comparison to other groups (P<0.05). In all groups, the epidermis was thick and disorganized. (Table 1; Figure 1, 2).

Table 1: Mean ± SD of wound surface area (cm²) in groups on the 10th day.

Day	Control	Basal Cream	Tetracycline	<i>S. rebaudiana</i>
10	1.45±0.04 ^a	1.3±0.04 ^b	1.05±0.05 ^c	0.77±0.05 ^d

Values bearing different superscripts in a row differ significantly (P<0.05).

Table 2: Mean ± SD of histomorphometrical criteria in groups on the 10th day.

10th day	Control	Basal Cream	Tetracycline	<i>S. rebaudiana</i>
Total cell	1395.90±201.98 ^b	1549.80±292.82 ^a	1170.90±169.67 ^c	1365.5±226.34 ^b
Vascular no.	18.60±8.93 ^a	18.90±6.38 ^a	12.10±5.66 ^b	20.20±5.67 ^a
Fibrocytes	1.9±1.59 ^b	1.2±1.61 ^c	2.7±1.56 ^a	3.2±2.14 ^a
Fibroblasts	27.7±6.12 ^b	49.7±9.32 ^a	21.1±3.66 ^b	45.9±10.38 ^a
Ratio Fibrocytes to Fibroblasts	0.06±0.05 ^c	0.2±0.03 ^a	0.12±0.07 ^b	0.07±0.05 ^c
Neutrophils	7.7±3.65 ^c	12.7±8.3 ^b	21.6±8.32 ^a	8.38±8.27 ^c
Lymphocytes	3.5±2.17 ^b	1±1.15 ^c	7.3±3.3 ^a	0.7±0.82 ^c
Macrophages	2.2±1.81 ^a	0.3±0.67 ^b	1.6±1.26 ^a	0.0±0.0 ^b

Values bearing different superscripts in a row differ significantly (P<0.05).

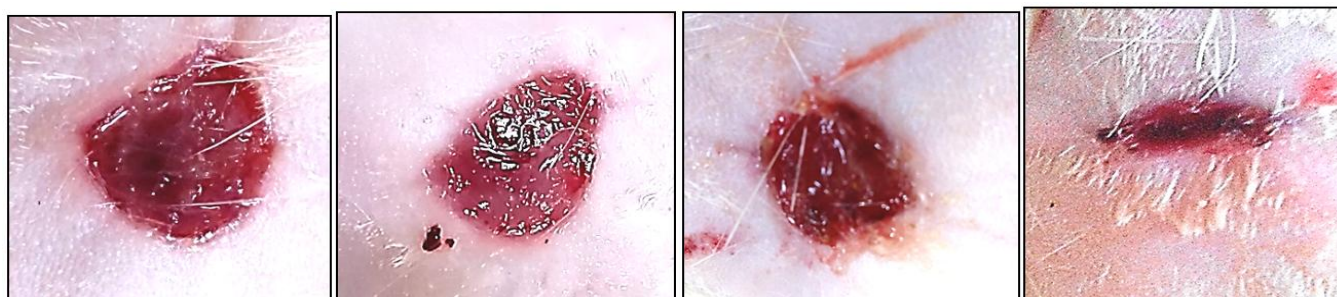


Figure 1: Macroscopic wound images of the control, basal cream, tetracycline and SR (From left to right, respectively), on day 10.

The data from the histopathologic analysis are demonstrated in Table 2 and figure 3-4. Treatment with *S. rebaudiana* significantly reduced wound surface area, inflammatory cells (lymphocytes and Macrophages)

compared with the other groups ($P < 0.05$; Table 2; Figure 4). The treated lesions with *S. rebaudiana* had a higher number of fibrocytes compared to the other groups. ($P < 0.05$; Table 2; Figure 4).

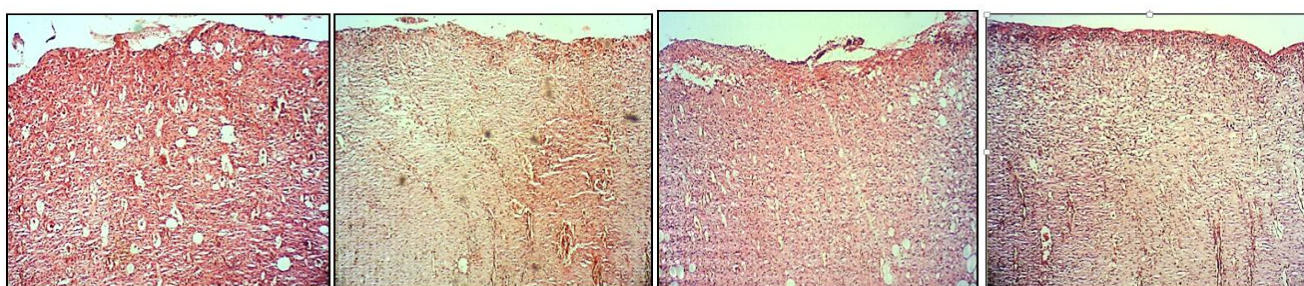


Figure 2: Longitudinal sections of the control, basal cream, tetracycline and SR (From left to right, respectively), on day 10 post-injury with Hematoxylin-Eosin staining.

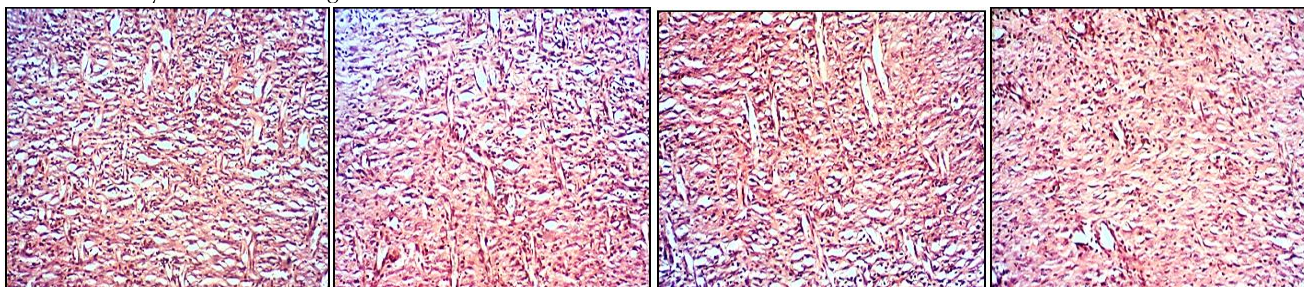


Figure 3: Longitudinal sections of the control, basal cream, tetracycline and SR (From left to right, respectively), on day 10 post-injury with Hematoxylin-Eosin staining.

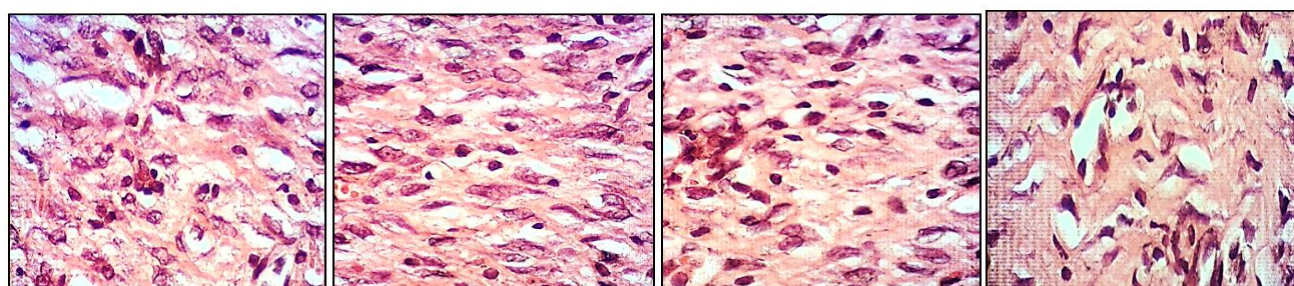


Figure 4: Longitudinal sections of the control, basal cream, tetracycline and SR (From left to right, respectively), on day 10 post-injury with Hematoxylin-Eosin staining.

Discussion

Iran has a rich flora widely distributed throughout the country, particularly in the west of Iran especially in Kermanshah [24-26]. In Iranian traditional medicine, herbal medicines are used for the prevention and curing of different diseases such as cutaneous wounds [27-30]. *S. rebaudiana* as a plant in Iranian traditional medicine has good antioxidant properties against free radicals. Also, it revealed that *S. rebaudiana* have a strong protective potential against the toxicity of most of the body organs [3]. *S. rebaudiana* has many anti-inflammatory compounds [3], so it can use for the management and treatment of several injuries such as cutaneous wounds. In this experimental study the wound healing potential of *S. rebaudiana* aqueous extract was determined in the rat model.

The results of the present study indicated that topical application of *S. rebaudiana* was able to significantly increment the wound contraction and epithelization rate in rats at the short term. Epithelialization is an indispensable and inseparable part of cutaneous wound healing used as defining criteria of prosperous wound closure. A cutaneous wound cannot healed completely without epithelialization. The epithelialization procedure is defective in all types of wounds [31]. One of the major results in this study was the significant difference in wound contraction rate and epithelization rate between *S. rebaudiana* group and the other groups. The increased rate of wound contraction and decrease healing time in treated lesions with *S. rebaudiana* might be due to the anti-inflammatory properties of this plant together with its effect on maturation and organization of the granulation tissue.

Based on histopathological findings, the granulation tissue formation was precipitated by applying *S. rebaudiana*. This ability was especially obvious when these observations were compared with those of other groups. Also, the increment in dry granulation tissue weight in the treated animals offered higher protein content.

In granulation tissue formation, fibroblasts and fibrocytes are very active. Fibroblast and fibrocytes are specialized cells that produced the collagen, extracellular matrix, and the structural framework for animal and human tissues, and play a very important and necessary role in cutaneous wound healing. They with making collagen, decreased cellularity in

wound area [32]. Collagen is the most plentiful structural protein in the animal and human body and is the component that retains the whole body together. It is found in the skin, tendons, muscles, bones etc. It makes a treillage to create structure and strength daily activities body. In skin, collagen accelerates wound healing in the injured region. Also, collagen plays an important role in hemostasis [33, 34], in fact when collagen is made accessible to the wound bed, closure can happen.

In this experiment, *S. rebaudiana* enhanced the number of blood vessels in comparison to other groups. With an increasing number of blood vessels, the number of fibroblast and fibrocytes increased in the surface wound area and promoted the rate of wound healing.

The lower levels of inflammation in *S. rebaudiana* group can be due to the presence of some phytoconstituents in this plant species which prevented the effects of inflammatory cells and production of chemical mediators and consequently reduced inflammation and subsequently promotes the organization. In this study, *S. rebaudiana* decreased the number of lymphocytes and macrophages compared to other groups and decreased neutrophils in comparison to basal cream and tetracycline at 10 days. Presences of lymphocytes and macrophages, reduced quality and rate of cutaneous wound healing in wound surface area.

Conclusion

Our results endorse the use of the ethnomedicinal plant in traditional medicine and offer that *S. rebaudiana* aqueous extract possess compounds with good wound healing effect. In details, *S. rebaudiana* reduce inflammation, wound size significantly and ameliorated epithelialization rate, fibroblastic response, and collagen content and yield more scar tissue in the early stages of wound healing.

Conflict of interest

None of the authors have any conflict of interest to declare.

Consent for publications

All authors approved the final manuscript for publication.

Availability of data and material

Data are available on request from the authors.

Funding/Support

This work was supported by University of Zabol in grant: IR-UOZ-GR-2735.

References

- Chitra S, Patil MB and Ravi K. Wound healing activity of *Hyptis suaveolens* (L) poit (Lamiaceae). *Int J Pharm Technol Res* 2009; 1(3): 737-44.
- Falanga V. Wound healing and its impairment in the diabetic foot. *Lancet* 2005; 12: 1736-43.
- Hagh-Nazari L, Goodarzi N, Zangeneh MM, Zangeneh A, Tahvilin R and Moradi R. Stereological study of kidney in streptozotocin-induced diabetic mice treated with ethanolic extract of *Stevia rebaudiana* (bitter fraction). *Comp Clin Pathol* 2017; 26 (2): 455-63.
- Buganza-Tepole A and Kuhl E. Systems-based approaches toward wound healing. *Pediatr Res* 2013; 73(4): 553-63.
- Singh MP and Sharma CS. Wound healing activity of *Terminalia Chebula* in experimentally induced diabetic rats. *Int J Pharm Technol Res* 2009; 4(1): 1267-70.
- Faramarzi E, Zangeneh MM, Zangeneh A and Moradi R. Effect of *Cinnamomum zelanicum* oil on hyponeophagia anxiety test in Balb C male mice. *Onl J Vet Res* 2017; 21(2): 77-80.
- Foroughi A, Pournaghi P, Najafi F, Zangeneh A, Zangeneh MM and Moradi R. Antibacterial effect and phytochemical screening of essential oil of *Pimpinella anisum* against *Escherichia coli* O157:H7 and *Staphylococcus aureus*. *Int J Curr Med Pharm Res* 2016; 7(6): 367-71.
- Ghashghaii A, Hashemnia M, Nikousefat Z, Zangeneh MM, Zangeneh A. Wound healing potential of methanolic extract of *Scrophularia striata* in rats. *Pharm Sci* 2017; 23 (4): 256-63.
- Zangeneh MM, Goodarzi N, Zangeneh A, Tahvilian R, Najafi F. Amelioration of renal structural changes in STZ-induced diabetic mice with ethanolic extract of *Allium saralicum* R.M. Fritsch. *Comp Clin Pathol* 2018; 27: 861-867.
- Zangeneh MM, Zangeneh AA, Tahvilian R, Moradi R. Evaluation of the nephroprotective effect of *Glycyrrhiza glabra* L aqueous extract on CCl₄-induced nephrotoxicity in mice. *Comp Clin Pathol* 2018; 27:1119-1126.
- Foroughi A, Pournaghi P, Najafi F, Zangeneh A, Zangeneh MM and Moradi R. Medicinal Plants: Antibacterial Effects and Chemical Composition of Essential Oil of *Foeniculum vulgare*. *Int J Curr Pharm Res* 2017; 8(1): 13-7.
- Mohammadi G, Zangeneh MM, Zangeneh A, Siavash-Haghighi ZM. Chemical characterization and anti-breast cancer effects of silver nanoparticles using *Phoenix dactylifera* seed ethanolic extract on 7,12-Dimethylbenz[a] anthracene-induced mammary gland carcinogenesis in Sprague Dawley male rats. *Appl. Organomet. Chem* 2020; 34(1): 5136.
- Baie SH and Sheikh KA. The wound healing properties of Channastriatus-cetrimide cream wound contraction and glycosaminogly can measurement. *J Ethnopharmacol* 2000; 73(1): 15-30.
- Nayak BS, Isitor G, Davis EM and Pillai GK. The Evidence based wound healing activity of

- lawsoniainermis Linn. Phytother Res 2007; 21(9): 827-31.
15. Ohshima H, Yoshie Y, Auriol S and Gilibert I. Antioxidant and pro-oxidant actions of flavonoids: effects on DNA damage induced by nitric oxide, peroxynitrite and nitroxyl anion. Free Radic Biol Med 1998; 25(9): 1057-65.
 16. Joshi A, Joshi VK, Pandey D, Hemalatha S. Systematic investigation of ethanolic extract from *Leea macrophylla*: implications in wound healing. J Ethnopharmacol 2016; 191: 95-106, 2016.
 17. Afshar M, Sattari fard H, Shadi M and Ghaderi R. Repairing effects of Iran flora on wound healing. J Birjand Univ Med Sci 2015; 22 (1):1-18.
 18. Bakhtiyari Z and Radan MR. Pharmacological effects of medicinal plants on skin. Dermatology and Cosmetic 2013; 4 (2): 98-106.
 19. Zangeneh MM, Najafi F, Moradi R, Tahvilian R, Haghazari L and Zangeneh A. Evaluation of the in vitro antibacterial activities of alcoholic extract of *Stevia rebaudiana* against *Escherichia coli* O157: H7 (ATCC No. 25922). Asian J Pharm Anal Med Chem 2016; 4(3): 131-136.
 20. Sherkatolabbasieh H, Hagh-Nazari L, Shafieezadeh S, Goodarzi N, Zangeneh MM, Zangeneh A. Ameliorative effects of the ethanolic extract of *Allium saralicum* R.M. Fritsch on CCl₄-induced nephrotoxicity in mice: A stereological examination. Arch Biol Sci 2017; 69(3):535-43.
 21. Hemmati S, Rashtiani A, Zangeneh MM, Mohammadi P, Zangeneh A, Veisi H. Green synthesis and characterization of silver nanoparticles using *Fritillaria* flower extract and their antibacterial activity against some human pathogens. Polyhedron 2019; 158: 8-14.
 22. Zangeneh MM. Hematoprotective and nephroprotective properties of ethanolic extract of *Anthemis odontostephana* Boiss in streptozotocin-induced diabetic mice. J Med Plants 2018; 17(65): 47-60.
 23. Oryan A, Mohammadalipour A, Moshiri A, Mohammad R and Tabandeh. Avocado/soybean unsaponifiables: a novel regulator of cutaneous wound healing, modelling and remodeling. Int Wound J 2015; 12(6): 674-85.
 24. Zangeneh MM, Zangeneh A, Salmani S, Jamshidpour R, Koosari F. Protection of phenylhydrazine-induced hematotoxicity by aqueous extract of *Ocimum basilicum* in Wistar male rats. Comp Clin Path 2019; 28: 331-338.
 25. Goorani S, Shariatifar N, Seydi N, Zangeneh A, Moradi R, Tari B, Nazari F, Zangeneh MM. The aqueous extract of *Allium saralicum* R.M. Fritsch effectively treat induced anemia: experimental study on Wistar rats. Orient Pharm Exp Med 2019; 19: 403-413.
 26. Tahvilian R, Moradi R, Zhaleh H, Zangeneh MM, Zangeneh A, Yazdani H, Hajialiani M. Evaluation of Antibacterial properties of essential oil of *Pistacia khinjuk*. Int J Res Pharm Sci 2017; 7(1): 1-6.
 27. Foroughi A, Zangeneh MM, Kazemi N and Zangeneh A An in vitro study on antimicrobial properties of *Allium*

- noeanumreut ex regel: An ethnomedicinal plant. Iranian J Publ Health 2016; 45(2): 32.
28. Zangeneh A, Zangeneh MM, Goodarzi N, Najafi F, Hagh-Nazari L. Protective effects of aqueous extract of internal septum of walnut fruit on diabetic hepatopathy in streptozotocin-induced diabetic mice. Sci J Kurdistan Univ Med Sci 2018; 23(1): 26-37.
 29. Zangeneh MM, Zangeneh A, Amiri H, Amiri N, Tahvilian R, Moradi R, Zhaleh H, Razeghi Tehrani P. Nephroprotective activity of Alyssum menicoides Boiss aqueous extract on streptozotocin-induced diabetic nephrotoxicity in male mice. Comp Clin Pathol 2018; 27(5): 1147-1154.
 30. Sayyedrostami T, Pournaghi P, Ebrahimi Vosta-Kalaei S, Zangeneh MM. Evaluation of the wound healing activity of *Chenopodium botrys* leaves essential oil in rats (A short-term study). J Essent Oil Bear Pl 2018; 21(1): 164-74.
 31. Langton AK, Herrick SE and Headon DJ. An extended epidermal response heals cutaneous wounds in the absence of a hair follicle stem cell contribution. J Invest Dermatol 2008; 128(5): 1311.
 32. Nayak BS and Pinto Pereira LM. *Catharanthus roseus* flower extract has wound-healing activity in Sprague Dawley rats. Complement Altern Med 2006; 21(6): 41-7.
 33. Oryan A, Tabatabaieinaeni A, Moshiri A, Mohammadalipoor A and Tabandeh MR. Modulation of cutaneous wound healing by Silymarin in rats. J Wound Care 2012; 21(9): 457-64.
 34. Courtois MC, Sapoval M, Del Giudice C, Ducloux R, Mirault T and Messas E. Distal revascularization in diabetic patients with chronic limb ischemia. J Mal Vasc 2015; 40(1): 24-36.