







Effects of *Asystasia gangetica* Extract on Biochemical Parameters and Liver Histomorphology of Monosodium Glutamate Induced Rats

Robert Ikechukwu Uroko^{1*} , Agbafor Amarachi¹ , Paul Chukwuemaka Nweje-Anyalowu² , Ogwo Elisha Uko³  and Precious Tobechei Abuachi¹

¹Department of Biochemistry, College of Natural Sciences, Michael Okpara University of Agriculture, Umudike, Abia State, Nigeria

²Department of Biochemistry, Faculty of Science, Clifford University, Owerri, Abia State, Nigeria

³Department of Physiology, Abia State University, Uturu, Abia State, Nigeria

Article Info

*Correspondence to:

Robert Ikechukwu Uroko
ir.uroko@mouau.edu.ng

Article History:

Received: 01 June 2020

Accepted: 29 June 2020

ePublished: 12 March 2020

Keywords:

Asystasia gangetica, hepatoprotection, liver functions, Monosodium glutamate, Liver marker enzymes, Acute toxicity

Abstract

The study assessed the hepatoprotective and therapeutic effects of methanol extract of *Asystasia gangetica* leaves (MEAGL) on rats induced liver injury with monosodium glutamate (MSG). In this study, fifty-four rats were selected into nine groups, with each of the groups having six rats. Group 1 was the negative control; group 2 was a positive control treated only with MSG, and group 3 was group treated with MSG + 100 mg/kg/day of silymarin. Groups 4 and 5 were extract groups administered with 200 and 500 mg/kg MEAGL/day, whereas groups 6 and 7 were hepatoprotectant groups pre-treated with 200 and 500 mg/kg MEAGL/day before MSG administration. Groups 8 and 9 were the therapeutic groups first treated with MSG and then orally administered with 200 and 500 mg/kg MEAGL/day, respectively. The positive group treated with MSG only had significantly ($P < 0.05$) elevated alanine transaminase (ALT), aspartate transaminase (AST) and alkaline phosphatase (ALP) activities relative to the negative control. MSG induction further caused a significant ($P < 0.05$) reduction in total protein and albumin concentrations and elevated total and direct bilirubin concentrations of the positive control relative to the negative control. In the groups of MEAGL pre-treated rats as well as the rats treated with MEAGL after being treated with MSG, significantly ($P < 0.05$) reduced ALT, AST and ALP activities and elevated total protein and albumin concentrations and improved liver architecture compared with the positive group treated only with MSG, were observed. The findings revealed that the MEAGL possess both hepatoprotective and therapeutic activities that could ameliorate MSG-induced hepatic disorders.

How to cite this paper

Uroko RI, Amarachi A, Nweje-Anyalowu PC, Uko OE, Abuachi PT. Effects of *Asystasia gangetica* Extract on Biochemical Parameters and Liver Histomorphology of Monosodium Glutamate Induced Rats. *Plant Biotechnology Persa* 2021; 3(2): 1-10.

Introduction

Monosodium glutamate is a widely used flavour enhancer in food industries and has been shown to have deleterious effects on human health, including animals from experimental studies, with many pieces of evidence illustrating that it is a hepatotoxicant [1,2]. It has also been reported to cause Chinese restaurant syndrome, hyperlipidaemia, hyperglycaemia, depletion of antioxidant enzymes, and increased oxidative stress has been implicated as its hepatotoxic mechanisms [3,4]. Some persons experience weakness of the body, increased sweating, headache and dizziness after consumption of food flavoured with monosodium glutamate [5]. Moreover, monosodium glutamate compromises liver function leading to significant reductions in the capacity of the liver cells to make sufficient serum total protein, albumin and bilirubin levels for normal biochemical functions in the body. The liver is a key organ for biotransformation and detoxification of drugs and xenobiotics, and liver injury could adversely affect these functions and other metabolic activities that would impair the health and survival of an individual. Despite emerging pieces of evidence of monosodium glutamate toxicity such as induction of mitochondrial oxidative status, hepatic injury, metabolic syndrome, obesity and neuronal damage, much of its consumers still consume it regularly due to its ability to increase appetite and special taste it gives to food [6]. Thus, deliberate efforts should be made to protect primarily liver cells from hepatotoxicants such as MSG and preserve their integrity and functions. Plant extracts and other therapeutic agents with high antioxidant activities are effective in attenuating oxidative stress and hepatotoxicity induced by monosodium glutamate in animal models [7].

Asystasia gangetica (L.) T. Anderson is commonly known as the "hunter's spinach or Chinese violet", belongs to the Acanthaceae family found across tropical Asia and Africa [8]. *A. gangetica* as a medicinal plant has been found useful in the treatment of gonorrhoea, diabetes mellitus, cancer, epilepsy, urethral discharge, snake bite rheumatism, stomachache, inflammation, dry coughs, and asthma [9-11]. The plant extract has been reported to be rich in saponins, terpenoids, flavonoids, steroids, alkaloids, tannins, glycosides, and anthraquinones, including minerals like copper, zinc, phosphorous, iron and magnesium believed to be responsible

for its observed pharmacological activities [12,13]. It is the herbal plant that has been extensively used in Enugu-Ezike, Enugu State, Nigeria, by traditional medicine practitioners to treat hepatitis and other liver diseases without any scientific evaluation of its hepatoprotective and therapeutic effects. Thus, the study assessed the hepatoprotective and therapeutic activities of methanol extract of *A. gangetica* leaves (MEAGL) against monosodium glutamate-induced liver injury in rats. This will give insight into the evidence-based hepatoprotective ability of MEAGL proposed by the local medical practitioners and possibly provide credence of the traditional claim and promote research interest to enable isolation, characterization and commercialization of hepatoprotective bioactive constituents of *A. gangetica* leaves.

Materials and Methods

Collection of *A. gangetica* leaves and extraction

A. gangetica leaves were collected from a Forestry located at Ndume, Umuahia North, Abia State, Nigeria. *A. gangetica* leaves collected identified as *A. gangetica* leaves with voucher number 2694-5 (press1899). The fresh leaves were properly hand-picked from their stems and washed in clean running water. The leaves were dried under shade until a constant weight was obtained and ground for the extraction. A 500 g of the pulverized sample was soaked with absolute methanol (1.5 litres) for 72 hours in the sterile container before it was filtered. The methanol in the filtrate was removed by placing the container containing the filtrate in a water bath at 50 °C; the filtrate left after the methanol had been removed was reweighed, and the yield was calculated in percentage.

Animals for the study

The experiment of acute toxicity of MEAGL was performed with 18 albino mice, while 54 male Wistar rats were used to analyze hepatoprotective and therapeutic activities of MEAGL against MSG-induced hepatotoxicity. The rats were purchased from the University of Nigeria, Nsukka and allowed to adapt to the new laboratory condition by housing them for two weeks in our Animal House, with adequate unhindered access to clean drinking water and standard animal feed.

Chemicals and reagents

The silymarin tablets were purchased from Micro Labs Limited (India); Randox commercial kits from Randox Laboratories Ltd., Crumlin, County Antrim, United Kingdom; MSG was purchased from Arshine Pharmaceutical Company Limited, Changsha, China, and methanol was sourced from Sigma-Aldrich, St. Louis, Missouri, United States.

Experimental design

The mice were randomly selected into two groups containing nine mice each for the phase I and II study of the acute toxicity effects of MEAGL. The 54 rats were selected into nine groups ($n = 6$), with group 1 as the negative control that received 2 ml/kg/day of normal saline only, while group 2 was the positive group that received only MSG (8 mg/kg) on the day 1 and 8. Group 3 was the positive group given 100 mg/kg/day of silymarin but was administered with 8 mg/kg of MSG 30 min after the treatment with silymarin on days 7 and 14, respectively. Groups 4 and 5 were experimental groups that received only 200 and 500 mg/kg/day of the

Results

Acute toxicity of methanol extract of *A. gangetica* leaves

The extraction of 500 g of the pulverized *A. gangetica* leaves revealed a yield of 7.75% of MEAGL, which is equivalent to 38.75 g of the MEAGL obtained. The result of the acute toxicity indicates that MEAGL is relatively safe for consumption as none of the treated animals exhibited any signs and symptoms of toxicity or died after 24 h of the administration of low and high doses of the extract, respectively. Acute toxicity studies in humans are emerging due to the significant difference in methanol metabolism in rats vs humans. It is generally well known that in rats, the same metabolites are produced by the enzymes alcohol and aldehyde dehydrogenases, but rodents can effectively convert formic acid to carbon dioxide without causing metabolic

MEAGL. Groups 6 and 7 were the hepatoprotectant groups pre-treated with 200 and 500 mg/kg/day of MEAGL, respectively, and after 30 min of administration of MEAGL on days 7 and 14, treated with 8 mg/kg of MSG. Also, groups 8 and 9 served as the therapeutic groups treated with 200 and 500 mg/kg/day of MEAGL, respectively but were administered MSG (8 mg/kg) on the day 1 and 8, 30 min before the treatment with MEAGL. All the treatments were given orally using a gavage. After 14 days, the rats fasted overnight, and on the 15th day, we withdrew blood from the rats and harvested their livers for biochemical evaluations and histological examinations, respectively.

Ethical approval

The animals were humanely treated according to the guidelines of the Michael Okpara University of Agriculture, Umudike, for the use of animals for laboratory study. The Ethical Committee of the Department of Physiology, Biochemistry and Pharmacology approved the student a reference number: MOUAU/VPP/EC/18/004.

acidosis and vision system toxicity usually occurring in methanol poisoning of humans.

Effects of methanol extract of *A. gangetica* leaves on biochemical parameters

The AST activities in rats of the positive group treated with MSG only are significantly increased ($P < 0.05$), comparable with the negative control (Table 1). Besides, the experimental group that received 200 mg/kg/day of MEAGL only had no significant increase ($P > 0.05$) in AST activities relative to the negative control, unlike the experimental group, which received 500 mg/kg/day of the MEAGL only that demonstrated a significant decrease ($P < 0.05$) in AST activities in comparison with negative control. The hepatoprotectant and therapeutic groups showed no significant increases ($P > 0.05$) in the AST activities compared with the negative control, respectively.

Table 1: Liver marker enzyme activities of rats with liver injury induced by monosodium glutamate and treated with methanol extract of *Asystasia gangetica* leaves

Treatment groups	Enzymes activities		
	AST (IU/L)	ALT (IU/L)	ALP (IU/L)
Negative control	107.33 ± 2.82 ^{ab}	47.73 ± 0.80 ^a	26.18 ± 0.95 ^a
Positive group (MSG only)	153.67 ± 3.51 ^c	68.45 ± 1.11 ^f	40.69 ± 0.88 ^f
Positive group (MSG+silymarin)	121.67 ± 2.53 ^{bc}	56.63 ± 0.94 ^d	34.83 ± 1.58 ^d
200 mg/kg/day MEAGL	117.00 ± 3.90 ^{bc}	50.37 ± 1.10 ^b	33.09 ± 1.51 ^c
500 mg/kg/day MEAGL	114.00 ± 3.70 ^a	53.56 ± 0.71 ^c	34.58 ± 1.04 ^d
200 mg/kg/day MEAGL + MSG	133.33 ± 4.16 ^{bc}	53.98 ± 1.51 ^c	36.39 ± 1.06 ^e
500 mg/kg/day MEAGL + MSG	133.68 ± 4.04 ^{bc}	58.42 ± 0.63 ^e	35.48 ± 1.46 ^{de}
MSG + 200 mg/kg/day MEAGL	127.00 ± 3.8 ^{bc}	51.43 ± 0.82 ^b	29.31 ± 0.92 ^b
MSG + 500 mg/kg/day MEAGL	122.66 ± 3.55 ^{bc}	53.84 ± 0.91 ^c	27.91 ± 1.10 ^b

Results are displayed as mean ± standard deviation (n = 6), and the results with unlike superscripts are considered significantly different ($P < 0.05$) compared to any paired result in the same column.

The ALT activities (Table 1) displayed a significant increase ($P < 0.05$) in the positive group treated only with MSG, the positive group treated with MSG + silymarin, experimental groups treated with graded doses of MEAGL only, hepatoprotectant and therapeutic groups relative to the negative control. Asides, there was a significant decrease ($P < 0.05$) in the ALT activities of the positive group treated with MSG + silymarin, experimental groups that received MEAGL only, hepatoprotectant and therapeutic groups compared with the positive group treated with MSG only. Furthermore, the hepatoprotectant group treated with MSG + 200 mg/kg/day of MEAGL and all the therapeutic groups demonstrated a significant decrease ($P < 0.05$) in ALT activities comparable with the positive group treated with MSG + silymarin.

The ALP activities (Table 1) displayed significant increases ($P < 0.05$) in the rats of the positive group treated only with MSG, the positive group treated with MSG and silymarin, experimental groups treated with MEAGL only, hepatoprotectant and therapeutic groups in comparison with the negative control. The hepatoprotectant group treated with MSG + 200 mg/kg of MEAGL/day and therapeutic

groups treated with 200 and 500 mg/kg of MEAGL/day after MSG induction displayed significant reduction ($P < 0.05$) in the ALP activities relative to the positive group treated with MSG + silymarin.

The results in Table 2 demonstrated a significant decrease ($P < 0.05$) in the serum total protein concentrations of the experimental groups treated with graded doses of MEAGL relative to the negative control. Treatments with the graded doses of MEAGL caused significant increases ($P < 0.05$) in the serum total protein concentrations of the hepatoprotectant and therapeutic groups, respectively comparable with the positive group treated only with MSG. Similarly, the hepatoprotectant groups and experimental groups treated with MEAGL only demonstrated a significant increase ($P < 0.05$) in the serum total protein concentrations relative to the positive group treated only with MSG, with that of the experimental groups treated with only graded doses of MEAGL been significantly raised ($P < 0.05$) relative to the hepatoprotectant groups. Contrarily, there was no significant difference ($P > 0.05$) observed in the serum total protein concentrations of the hepatoprotectant groups relative to the positive group treated with MSG + silymarin while the therapeutic groups had significantly reduced ($P < 0.05$) serum total protein concentrations comparable with the positive group treated with MSG + silymarin.

Table 2: Liver function indices of rats with liver injury induced by monosodium glutamate and treated with methanol extract of *Asystasia gangetica* leaves

Treatment groups	TP (g/dL)	ALB. (g/dL)	T. (mg/dL)	Bil (mg/dL)	D. (mg/dL)	Bil
Negative control	7.03±0.16 ^g	4.34±0.25 ^f	0.56±0.03 ^a	0.35±0.03 ^a		
Positive group (MSG only)	3.34±0.15 ^a	2.09±0.11 ^a	1.33±0.06 ^b	1.04±0.06 ^e		
Positive group (MSG+silymarin)	5.60±0.20 ^{cd}	3.82±0.15 ^{de}	0.92±0.05 ^{ab}	0.68±0.03 ^{bc}		
200 mg/kg/day MEAGL	6.00±0.20 ^e	4.21±0.09 ^f	0.76±0.04 ^a	0.43±0.06 ^a		
500 mg/kg/day MEAGL	6.35±0.14 ^f	4.09±0.11 ^{ef}	0.78±0.05 ^a	0.60±0.10 ^b		
200 mg/kg/day MEAGL + MSG	5.46 ±0.09 ^c	2.73±0.21 ^b	0.95±0.06 ^{ab}	0.61±0.08 ^b		
500 mg/kg/day MEAGL + MSG	5.85±0.16 ^{de}	2.74±0.22 ^b	0.96±0.06 ^{ab}	0.77±0.06 ^{cd}		
MSG + 200 mg/kg/day MEAGL	5.07±0.12 ^b	3.23±0.16 ^c	0.96±0.07 ^{ab}	0.80±0.10 ^{cd}		
MSG + 500 mg/kg/day MEAGL	5.10±0.10 ^b	3.60±0.10 ^d	1.26±0.06 ^b	0.82±0.05 ^d		

The albumin concentrations (Table 2) demonstrated significant decreases ($P < 0.05$) in the positive group treated with MSG only, the positive group treated with MSG + silymarin, hepatoprotectant and therapeutic groups, respectively, relative to the negative control. Contrarily, the positive group treated with MSG + silymarin, hepatoprotectant treated with MEAGL + MSG and therapeutic groups treated with MSG + MEAGL demonstrated a significant increase in the serum albumin concentrations relative to the positive group treated with MSG only, comparable with a negative control that received MSG without any further treatment. The experimental groups treated with only graded doses displayed significant increases ($P < 0.05$) in the serum albumin concentrations in comparison with the positive group treated with MSG + silymarin.

The serum total bilirubin concentrations (Table 2) displayed no significant increases ($P < 0.05$) in the positive group treated with MSG + silymarin and experimental groups treated with only graded doses of MEAGL in comparison with the negative control. However, the positive group treated with MSG only, hepatoprotectant and therapeutic groups, respectively, demonstrated significant increases ($P < 0.05$) in serum total bilirubin concentrations comparable with the negative control. The serum total bilirubin concentrations of the hepatoprotectant and therapeutic groups were not significantly reduced ($P > 0.05$) comparable with the positive group treated with MSG only. Whereas the negative control and experimental groups treated with graded doses of MEAGL demonstrated significant reduction ($P < 0.05$) in the serum total bilirubin concentrations relative to the positive

group treated with MSG only. The hepatoprotectant and therapeutic groups treated with MSG + MEAGL displayed no significant increases ($P > 0.05$) in the total bilirubin concentration comparable with the positive group treated with MSG + silymarin.

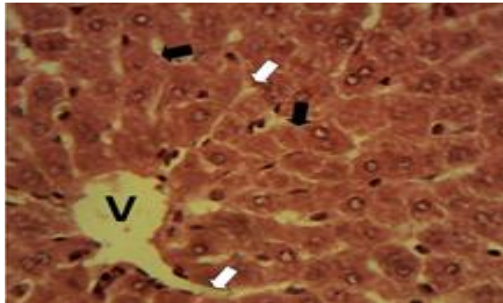
The serum direct bilirubin concentrations (Table 2) demonstrated a significant increase ($P < 0.05$) in the positive groups, the experimental group treated with 500 mg/kg/day of MEAGL only, hepatoprotectant and therapeutic groups comparable with the negative control. Whereas the positive group treated with MSG + silymarin, experimental groups treated with graded doses of MEAGL, hepatoprotectant and therapeutic groups, respectively, displayed significant reductions ($P < 0.05$) in the serum direct bilirubin concentrations in comparison with the positive group treated with MSG only. The significantly reduced ($P < 0.05$) serum direct bilirubin concentration relative to the positive group treated with MSG + silymarin was also observed in the experimental group that received 200 mg/kg/day MEAGL only. Moreover, there was no significant difference ($P > 0.05$) between the serum direct bilirubin concentrations of the positive groups treated with MSG + silymarin and hepatoprotectant group treated with 200 mg/kg/day of MEAGL, while the therapeutic groups had significantly increased ($P < 0.05$) serum direct bilirubin concentrations relative to the positive group treated with MS + silymarin.

Effects of methanol extract of *A. gangetica* leaves on liver histomorphology

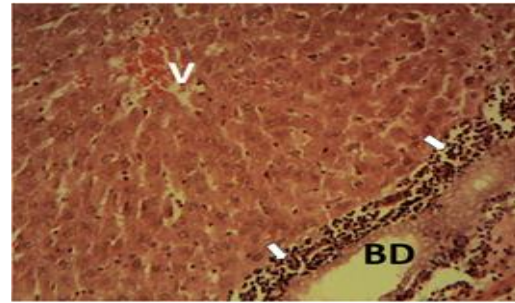
The liver photomicrographs of the negative control rats displayed normal hepatic histomorphology for laboratory rodents (Fig. 1a). The tissue has normal hepatic lobules made

up of normal hepatocytes arranged in interconnecting cords (hepatic cords) around the central veins. Contrary to the negative control, the liver photomicrograph of the positive group (treated only with MSG) demonstrated a severe degeneration and necrosis of the hepatocytes involving all the

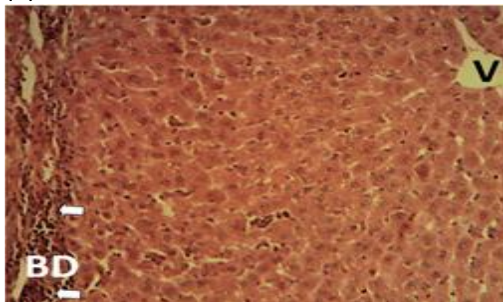
zones of the hepatic lobules (Fig. 1b). The affected hepatocytes (arrow) appeared slightly swollen and contained numerous clear vacuoles in their cytoplasm. This type of lesion is consistent with micro-vesicular steatosis.



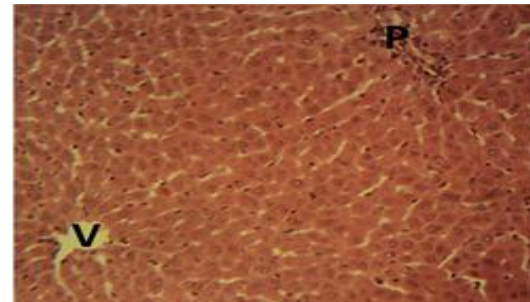
(a)



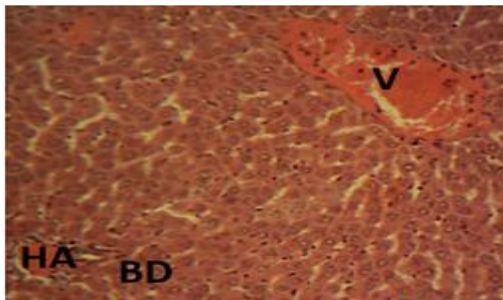
(b)



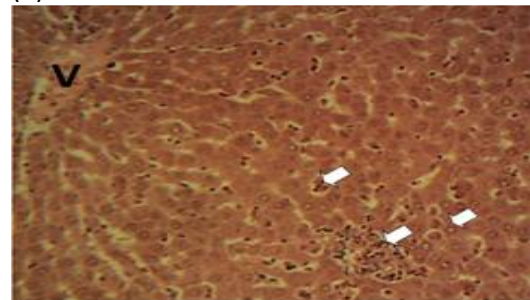
(c)



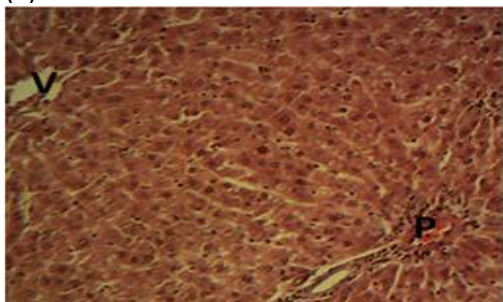
(d)



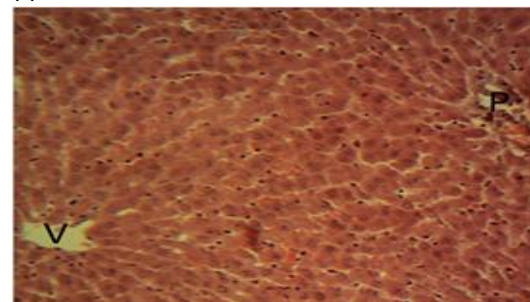
(e)



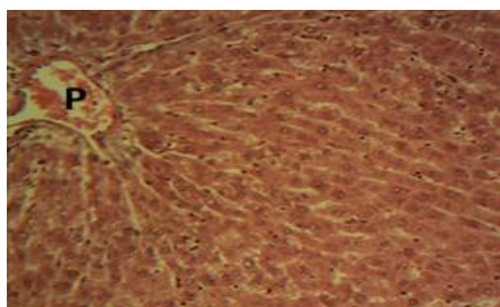
(f)



(g)



(h)



(i)

Figure 1a – i: Photomicrographs of liver slices from negative control (a), positive group treated with MSG only (b), positive control treated with MSG + silymarin (c), experimental group treated only with 200 mg/kg/day MEAGL (d), experimental group treated only with 500 mg/kg/day MEAGL (e), hepatoprotectant group treated with 200 mg/kg/day MEAGL + 8 mg/kg MSG (f), hepatoprotectant group treated with 500 mg/kg/day MEAGL + 8 mg/kg MSG (g), therapeutic group treated with 8 g/kg MSG + 200 mg/kg/day MEAGL (h), therapeutic group treated with 8 mg/kg MSG + 500 mg/kg/day MEAGL (i). Central vein (V); Portal area (P). Hepatic cords (Black arrow); Sinusoids (white arrow) Bile duct (BD); inflammatory cells (arrow).

The liver photomicrographs of rats in the positive group treated with MSG + silymarin displayed the normal hepatocytes arranged in interconnecting rods but with severe infiltrations of mononuclear inflammatory leucocytes around the portal triads were observed (periportal hepatitis) (Fig. 1c). The liver photomicrographs of the rats from the experimental groups administered 200 mg/kg MEAGL (Fig. 1d) and 500 mg/kg of methanol extract of *A. gangetica* leaves (MEAGL) (Fig. 1f), respectively, displayed the normal hepatic histomorphology for laboratory rodents.

The liver photomicrographs of the rats from the hepatoprotectant group administered 200 mg/kg of MEAGL/day + MSG demonstrated multifocal areas of necrosis (arrow) with mild infiltration on mononuclear leukocytes (Fig. 1f). Whereas, liver photomicrographs of the rats from the hepatoprotectant group administered 500 mg/kg of MEAGL/day + 8 mg/kg MSG displayed a moderate degeneration and necrosis of the hepatocytes involving all the zones of the hepatic lobules (Fig. 1g). The affected hepatocytes (arrow) appeared slightly swollen with numerous clear vacuoles in their cytoplasm. This lesion is consistent with micro-vesicular steatosis. Finally, liver photomicrographs of the rats from the therapeutic groups administered MSG + 200 mg/kg of MEAGL/day and MSG +

500 mg/kg of MEAGL/day, respectively, displayed histomorphology which was very similar to the normal one for laboratory rodents (Fig. 1h and Fig. 1i).

Discussion

Monosodium glutamate (MSG) is a common food additive used to enhance flavour and has been associated with many toxic effects such as neurotoxicity [20]. In addition, it is often mistrusted to be a very potent hepatotoxicant that acts via the induction of oxidative stress that could initiate other adverse health effects [1].

This study evaluated the hepatoprotective and therapeutic effects of methanol extract of *Asystasia gangetica* leaves (MEAGL) on monosodium glutamate-induced liver injury in rats. This attempt can be assumed as a continuation of the search for highly potent medicinal plants with hepatoprotective and therapeutic effects. Adequate plant material may be used to formulate herbal drugs that could improve the health status of patients with liver disorders and fill the gaps that many available synthetic drugs have failed to address in the field of hepatotherapeutics. Herbal drugs are the first-line of treatment of various ailments and diseases in African countries, and leaf extract of *A. gangetica* is one of the herbal agents with therapeutic effects that have been traditionally used in the management of hepatic disorders in southeastern Nigeria, but there is rare scientific literature to support its hepatoprotective and therapeutic properties.

The absence of mortality or any noticeable abnormal reactions in the mice that received varying doses of the MEAGL, even when the very high dose was administered, showed that the extract is relatively not acutely toxic to the rats; however, more *in vitro* and *in vivo* studies are required to fully understand the toxicological profile of MEAGL and its safety level in humans. In addition, the extract could be considered to be relatively safe for short-term consumption,

but toxic or adverse effects could not be ruled out on prolonged consumption as it may be chronically toxic. Thus, it should be taken with caution to avoid any harmful or lethal effects in the case of toxic effects associated with the excessive consumption of MEAGL.

The increased serum enzyme activities of aspartate transaminase (AST), alanine transaminase (ALT), and alkaline phosphatase (ALP) are indications of liver injury caused by the efflux of hepatic enzymes to the extra-hepatic tissues. The disruption of the hepatocytes architecture is associated with the loss of membrane integrity and increased membrane permeability, allowing much of the hepatic enzymes to drain out. Although the increase in the ALT activity only is considered as an indicator of liver injury, increases in the serum activities of multiple hepatic enzymes are usually more reliable to diagnose liver injury. However, kidney, cardiac tissues and other organs could contribute to the increased serum activity of any of AST, ALT and ALP when injured. The increased serum activities of hepatic enzymes in this study could be attributed to the toxic effects of monosodium glutamate on the hepatocytes and their resultant damage. This is in line with the findings of Onyema et al. [7]. MSG was applied to induce liver injury in rats manifested by the symptoms of liver damage and increased serum ALT, AST, and ALP activities. Serum activities of hepatic enzymes in rats belonging to the hepatoprotectants and therapeutic groups were significantly reduced compared to those of rats of the positive group treated only with MSG. This finding indicated that the MEAGL exhibited protective and therapeutic effects. The bioactive phytochemicals in the extract prevented the monosodium glutamate from causing severe liver injury, similar to the effects of silymarin on the positive group treated with silymarin + MSG. It was observed that aside from high hepatoprotective and therapeutic properties of MEAGL, it is important to note that in the MEAGL treated rats compared to silymarin administered rats, lower serum ALT and ALP activities have been found, as well as more intact and less permeable liver membranes, were observed favouring the use of MEAGL in the management of hepatic disorders. The MSG induction could have elicited hepatotoxicity by impairing antioxidant enzyme activities and promoting increased levels of lipid peroxidation, which made hepatocyte membranes vulnerable and injured. High levels of reactive oxygen species that could not be attenuated

by the antioxidant system can also initiate an oxidative attack of the hepatocytes [21]. The hepatoprotective and therapeutic effects of the MEAGL could be a result of an antioxidant mechanism similar to that of silymarin comprising improved membrane stability and reduced permeability of hepatic enzymes to extra-hepatic tissues. The very low serum levels of hepatic enzyme activities in the rats that received the MEAGL when coupled with the improved hepatic histo-architecture suggest the extract possesses hepatoprotective effects essential for the management of hepatic disorders.

Optimum liver function is critical to the well-being of an individual as the liver plays a vital role in the maintenance of efficient biochemical and physiological functions. The liver is involved in the biosynthesis of proteins, including albumin and biotransformation of drugs and xenobiotics for detoxification and excretion from the body. The significant reductions of total protein and albumin levels in the MSG treated rats without silymarin and/or MEAGL treatment showed that the rats suffered impaired protein synthesis due to the toxic effect of MSG that compromised liver functions in the rats. The observed reductions in the total protein and albumin concentrations are in agreement with the findings of Tawfik and Al-Badr that MSG induction impairs protein synthesis and other vital liver functions in rats [1]. Under these conditions, the albumin level will not be sufficient to transport low-density lipoprotein for metabolism in the liver and the rat could experience atherosclerosis and increased blood pressure due to the deposition of the lipid droplets on the arterial walls. Also, the MSG induction caused elevated levels of total bilirubin in the positive group treated only with MSG, MSG induced rats treated by silymarin and/or MEAGL compared to the negative control. This observation is an indication of a reduction in the ability of the liver cells of MSG only administered rats to conjugate the resulting bilirubin to direct bilirubin that physiologically increases its solubility in water and ensures ease excretion rate. The hepatic necrosis and central hepatic vein associated with lysis of red blood cells observed in this study accounted for the increased total bilirubin concentration in the untreated rats administered with MSG only, which is in agreement with the previous findings [22, 23]. The rats treated with the MEAGL only, as well as the rats of hepatoprotective and therapeutic groups treated with varying doses of MEAGL, showed increased levels of total protein and albumin and decreased total

bilirubin and direct bilirubin concentration relative to the rats of the positive group treated with MSG only. This could be attributed to the hepatoprotective and therapeutic effects of the extract against MSG-induced liver toxicity. Biochemical parameters indicated that the rat's liver is recovering from the toxic effect of MSG [1]. The administration of MEAGL improved protein synthesis in MSG-treated rats at the same time showing effective biodetoxification activities. The MEAGL compared to silymarin has shown significantly better hepatoprotection in MSG-treated rats; thus, it can be suggested as a hepatoprotective and therapeutic agent instead of the commonly used hepatoprotective drug silymarin. Moreover, the high total bilirubin and direct bilirubin concentrations in the therapeutic group treated with MSG + 500 mg/kg/day of MEAGL is an indication the extract exerts better therapeutic effects against MSG induced liver injury at lower doses than at very high doses as observed in this study. The hepatic histomorphology of the MSG-treated rats without additional treatment with silymarin or MEAGL has confirmed liver injury in the rats associated with severe degeneration and necrosis of the liver. The findings are in line with earlier reports that MSG administration causes deleterious effects on the liver cells, such as degeneration, necrosis, microvascular changes, cellular infiltrations and liver fibrosis [24, 25]. The severe infiltration of mononuclear inflammatory leucocytes around the portal triad showed that silymarin of the positive group treated with MSG + silymarin suggests that MSG adversely affected the hepatocytes of the rats, which could be attributed to the inability of silymarin to attenuate the hepatotoxic activity of MSG on the rats. Whereas, normal hepatic histomorphology of the experimental groups treated only MEAGL showed that the extract exerted no observable adverse effects on the rats liver histomorphology. At the same time, the mild necrosis in the hepatoprotectant groups and normal hepatic histomorphology observed in the therapeutic groups further indicated the therapeutic effects of MEAGL against MSG-induced toxicity on the liver cells.

Conclusion

Monosodium glutamate (MSG) was used for induction of hepatotoxicity in male Wistar rats to investigate the hepatic activity of the methanol extract of *A. gangetica* leaves

(MEAGL). The results of the study revealed that the MEAGL possesses better hepatoprotective and therapeutic effects than the well-known hepatoprotective drug silymarin, enabling significant protection against the toxic effects of MSG. These findings give evidence-based support to the traditional use of *A. gangetica* leaves for the management and treatment of various hepatic disorders. Further research is needed to isolate and characterize its bioactive constituents responsible for the hepatoprotective and therapeutic effects, as well as to design an appropriate herbal formulation for safe use in humans.

Conflicts of interest

The authors have declared no conflicts of interest.

Authors' contribution

The manuscript was carried out, written, and approved in collaboration with all authors.

Funding/Support

Department of Biochemistry, College of Natural Sciences, Michael Okpara University of Agriculture, Umudike, Abia State, Nigeria

References

1. Tawfik MS, Al-Badr N. Adverse Effects of Monosodium Glutamate on Liver and Kidney Functions in Adult Rats and Potential Protective Effect of Vitamins C and E. *Food Sci Nutr* 2012; 3: 651-659.
2. Tousson E, El-Atrash A, Karson Y. Protective role of rocket seed (*Eruca sativa*) extract against monosodium glutamate-induced hepato-renal toxicity in male rats. *Asian J Pharm Sci* 2019; 8(3-4): 1-10.
3. Kuldeep S, Ahluwalia P. Studies on the Effect of Monosodium Glutamate Administration on Some Antioxidant Enzymes in Arterial Tissue of Adult Male. *J Nutr Sci Vitaminol* 2003; 49: 145-148.
4. Diniz Y, Faine L, Galhardi C. Monosodium glutamate in standard and high-fibre diets: Metabolic syndrome and oxidative stress in rats. *Nutrition* 2005; 21: 749-755.
5. Geha RS, Beiser A, Ren C, Patterson R, Grammar LC, Ditto AM, Harris KE. Review of allergic reaction to monosodium glutamate and outcome of a multicenter double-blind placebo-controlled study. *J Nutr* 2000; 130: 1032S-1038S.

6. 6. Shivasharan BD, Nagakannan P, Thippeswamy BS, Veerapur VP. Protective effect of *Calendula officinalis* L. flowers against monosodium glutamate-induced oxidative stress and excitotoxic brain damage in rats. *Indian J Clin Biochem* 2013; 28(3): 292-298.
7. 7. Onyema OO, Farombi EO, Emerole GO. Ukoha AI, Onyeze GO. Effect of vitamin E on monosodium glutamate-induced hepatotoxicity and oxidative stress in rats. *Indian J Biochem. Biophys* 2006; 43: 20-24.
8. 8. Suvarchala NVLR, Anarthe SJ, Raghavendra NMGR. Evaluation of In-vitro antioxidant activity of methanol extract of *Asystasia gangetica* (L). T (Chinese violet). *Natural Products: An Indian Journal* 2009; 5(2):78-80.
9. 9. Akah PA, Ezike AC, Nwafor SV, Okoli CO, Enwerem, NM. Evaluation of the anti-asthmatic property of *Asystasia gangetica* leaf extracts. *J Ethnopharmacol* 2003; 89(1) : 25-36.
10. 10. Mepba H.D, Eboh, L, Banigo DEB. Effects of processing treatments on the nutritive composition and consumer acceptance of some Nigerian edible leafy vegetables. *Afr J Food Agric Nutr Dev* 2017; 7(1): 1-18.
11. 11. Kumar L, Ravi M, Shridhara B, Chaithra H, Ravi SB. Gastroprotective activity of *Asystasia gangetica* stem aqueous extract against pylorus ligated gastric ulcer in rats. *Int J Pharmacol Clin Sci* 2014; 3(3): 53-60
12. 12. Hamid AA, Aiyelaagbe OO, Ahmed RN, Usman LA, Adebayo SA. Preliminary Phytochemistry, Antibacterial and Antifungal Properties of extracts of *Asystasia gangetica* Linn T. Anderson grown in Nigeria. *Adv Appl Sci Res* 2011; 2(3): 219-226
13. 13. Somanathan SS, Ranganayakulu D, Jayaveera KN. In-vitro antioxidant activities of *Asystasia gangetica* leaf extract. *World J Pharm Pharm Sci* 2015; 4(2): 1228-1239.
14. 14. Lorke D. A new approach to practical acute toxicity testing. *Arch Toxicol* 1983; 54: 275-87.
15. 15. Reitman S, Frankel S. A colourimetric method for the determination of serum glutamic oxaloacetic and glutamic pyruvic transaminase. *Am J Clin Pathol* 1975; 28: 56-63.
16. 16. Lowry OH, Rosebrough JN, Farr AL, Randall RJ. Protein Measurement with the folin phenol reagent. *J Biol Chem* 1951; 193: 265 – 275.
17. 17. Dumas BT, Ard-Watson W, Biggs HG. Albumin standards and the measurement of serum albumin with bromocresol green. *Clin Chim Acta* 1971; 31(1): 87-96.
18. 18. Jendrassik L, Grof P. Determination of total bilirubin. *J Biochem* 1938. 279, 81-89
19. 19. Boano R, Fulcheri E, Grilletto R, Leospo E, Massa ER. Histological analysis and staining techniques modified and verified on ancient mummified tissues to study microorganism infestations. *Boll Soc Ital Biol Sper* 1999; 75(7-8): 39-45.
20. 20. Shi Z, Luscombe-Marsh ND, Wittert GA. Monosodium glutamate is not associated with obesity or a greater prevalence of weight gain over 5 years: Findings from the Jiangsu Nutrition Study of Chinese adults. *Br J Nutr* 2010; 104(3): 457-463.
21. 21. Ranawat L, Bhatt J, Patel J. Hepatoprotective activity of ethanolic extracts of bark of *Zanthoxylum armatum* DC in CCl₄ induced hepatic damage in rats. *J Ethnopharmacol* 2010; 127(3): 777-780.
22. 22. Eweka AO, Igbigbi PS, Ucheya RE. Histochemical studies of the effects of monosodium glutamate on the liver of adult Wistar rats. *Ann Med Health Sci Res* 2011; 1(1): 21-29.
23. 23. Albrahim T, Binobead MA. Roles of *Moringa oleifera* leaf extract in improving the impact of high dietary intake of monosodium glutamate-induced liver toxicity, oxidative stress, genotoxicity, DNA damage, and PCNA alterations in male rats. *Oxid Med Cell Longev* 2018: 1-11.
24. 24. Waer HF, Edress S. The effect of monosodium glutamate (MSG) on rat liver and the ameliorating effect of "guanidino ethane sulfonic acid (GES)" (histological, histochemical and electron microscopy studies). *Egypt J Hosp Med* 2006; 24: 524-538.
25. 25. Airaodion AI, Ogbuagu EO, Osemwowa EU, Ogbuagu U, Esonu CE, Agunbiade AP, Okereke D, Oloruntoba AP. Toxicological effect of monosodium glutamate in seasonings on human health. *Global J Nutr Food Sci* 2019; 1(5): 1-9.