

Evaluation of Hepatoprotective Potential of *Chromolaena odorata* (L.) R.M. King & H. Rob. against Methotrexate-Induced Hepatic Toxicity in Rats

Usunobun Usunomena¹, Imoru Natalie Ochuwa², Ikponmwosa Bridget³, Egbo Ojevwe Harrison⁴

¹Department of Biochemistry, Faculty of Basic Medical Sciences, College of Medical Sciences, Edo State University Uzairue, Edo State, Nigeria. E-mail: usunobun.usunomena@edouniversity.edu.ng

²Department of Biochemistry, Faculty of Basic Medical Sciences, College of Medical Sciences, Edo State University Uzairue, Edo State, Nigeria. E-mail: natalieimoru@gmail.com

³Department of Biochemistry, Faculty of Basic Medical Sciences, College of Medical Sciences, Edo State University Uzairue, Edo State, Nigeria. E-mail: ikponmwosa.bridget@edouniversity.edu.ng

⁴Department of Morbid Anatomy and Histopathology, Faculty of Clinical Sciences, College of Medical Sciences, Edo State University Uzairue, Edo State, Nigeria. E-mail: egbo.harrison@edouniversity.edu.ng

Corresponding Author, Department of Biochemistry, Faculty of Basic Medical Sciences, College of Medical Sciences, Edo State University Uzairue, Edo State, Nigeria. E-mail: usunobun.usunomena@edouniversity.edu.ng

Article Info

Article type:

Research Article

Article History:

Received: 01 June 2022

Received in revised form:
15 June 2022

Accepted: 9 June 2022

Published online: 23 Nov
2022

Keywords:

Antioxidant, *Chromolaena odorata* (L.) R.M. King & H. Rob., Methotrexate, Oxidative stress

Abstract

Objective: Liver, as an organ, is predominantly responsible for the metabolism of drugs, alcohol, and foreign chemicals; hence, it is vulnerable to injury that may result in different liver diseases. In this study the protective effect of *Chromolaena odorata* (L.) R.M. King & H. Rob. aqueous leaf extract against Methotrexate-induced hepatotoxicity in male wistar rats was investigated.

Material and Methods: 24 male rats were divided into four groups of 6. Group one received normal saline only and served as control while group two received 200mg/kg *Ch. odorata* aqueous extract daily for ten consecutive days. Group three received intraperitoneally, a single dose of 20mg/kg Methotrexate on the ninth day of treatment while group four received 200mg/kg *Ch. Odorata* aqueous extract for ten consecutive days and a single dose of 20mg/kg Methotrexate intraperitoneally on ninth day of the study.

Results: Results showed that Methotrexate-induced hepatotoxicity decreased liver synthetic molecules (Total Protein and Albumin); decreased endogenous antioxidants (Catalase and Superoxide dismutase); increased liver function enzymes (Alanine aminotransferase and Aspartate aminotransferase), and increased lipid peroxidation (Malondialdehyde). Corroborating biochemical assessment, Histopathological analysis of untreated Methotrexate rats showed liver sections with focal necrosis, dilation and congestion of central vein and portal vein whereas aqueous leaf extract of *Ch. odorata* reduced the degree of lesions with seen improvement and reduction of hepatocytes degeneration.

Conclusion: Thus, *Ch. odorata* (L.) offered protection to the liver from damage caused by Methotrexate attributable to its active bioactive agents including flavonoids which scavenges free radicals, enhanced the antioxidant status and protected against oxidative damage and oxidative stress.

Introduction

Liver is the most important organ predominantly responsible for the metabolism of drugs, alcohol, and foreign chemicals; hence, it is vulnerable to injury that results in different liver diseases such as hepatitis, fulminant hepatitis, cirrhosis, and hepatocellular carcinoma. Drug induced liver injury is responsible for 5% of all hospital admissions and 50% of all acute liver failures [1]. Toxicity of Methotrexate (MTX), a folic acid antagonist, commonly used as a cytotoxic agent in the treatment of leukemia and other malignancies as well as in the inflammation diseases such as psoriasis and rheumatoid arthritis [2-3] seems to relate to the generation of reactive oxygen species (ROS) [3-4].

Following reported Methotrexate toxicities, search for agents has become imperative including medicinal plants and their formulations. Different plant parts have been used for ages for several purposes ranging from food to medicine and herbal medicine practitioners and most locals use different plant parts for therapeutic purposes [5]. *Chromolaena odorata* (L.) R.M. King & H. Rob. known locally in Nigeria through many common names as Awolowo, siam weed, Elizabeth weed, obirakara, olorohuru and independence weed [6] has been popularized by its effective wound healing property. *Ch. odorata* therapy against dysentery, diabetes, skin diseases diarrhoea, malaria fever, tooth ache and colitis has been well reported [7, 8]. Usunobun and Ewere [19] established in *Ch. Odorata* leaves, the presence of bioactive agents including flavonoids, saponins, alkaloids, tannins; minerals such as calcium, sodium, potassium, magnesium, zinc, iron etc as well as its in vitro antioxidant property. We designed this study to investigate the protective effect of *Ch. Odorata* aqueous leaf extract against Methotrexate-induced hepatotoxicity in rats, pointing to the plant ability to scavenge free radicals, suppress oxidative stress and enhance antioxidant status.

Materials and Methods

Chemicals and Reagents

Methotrexate (liquid), 50 mg (Zuvius Life Sciences, India) was purchased from MEDVALIK Pharmaceuticals Limited, Lagos, Nigeria. All reagents used were of analytical grade and had the highest purity.

Collection and identification of Plant material

Fresh leaves of *Ch. odorata* were collected from within the locality of Iyamho community, Uzairue, in Etsako West Local Government Area of Edo State, Nigeria and taxonomically authenticated at the Department of Plant Biology and Biotechnology Herbarium, Edo State University Uzairue, Edo State Nigeria with voucher number EUH/00066.

Preparation and Extraction of plant materials

The fresh leaves of *Ch. odorata* were thoroughly rinsed and air-dried at room temperature for one month, then pulverized, crushed into a fine powder using an electric blender, and weighed with an electric weighing balance. An aqueous extract of the plant was prepared by soaking 1000g of the dried powdered plant materials in 5 liters of double-distilled water and then kept at room temperature for 48 hours to ensure a thorough extraction process. At the end of the 48 hours, the extracts were filtered first through a Whatman filter paper No. 42 (125mm) and then cotton wool. The resultant filtrate was concentrated using a rotary evaporator set at 40°C to one-tenth of its original volume and then reduced to solid form using a water bath. The solid residue (crude extract) was stored at 40°C. Aliquot portions of the crude plant extract residue were weighed and dissolved in normal saline on each experiment day.

Experimental Animals and Design

Twenty-four (24) male Wistar rats (180-210g) of the species- *Rattus norvegicus* were purchased from the animal house, Department of Zoology, Ambrose Alli University, Ekpoma, Nigeria. The animals were housed in a well-lit, adequately ventilated room using a wood-gauze cage in the Animal house of the Department of Biochemistry, Edo State University Uzairue, Edo State. Standard environmental conditions were used (12 hours light and 12 hours dark) in acclimatizing the animals to the new environment. Animals were fed with standard laboratory pellets and given free access to water.

After acclimatization for seven days, the rats were randomly distributed into the following groups as follows: Group I: Served as a control and only received normal saline orally once daily. Group II: Rats were given aqueous extract of *Ch. odorata* at a dose of 200 mg/kg orally once daily for ten days. Group III: Rats were given Methotrexate intraperitoneally at a single dose of 20 mg/kg on day 9 of the experiment. Group IV: Rats were given aqueous extract of *Ch. odorata* (200 mg/kg) orally once daily for ten days, and then Methotrexate intraperitoneally at a single dose of 20 mg/kg on day 9 of the experiment. Methotrexate was injected intraperitoneally at a single dose of 20 mg/kg [10]. *Ch. odorata* at a dose of 200mg/kg was based on study of [11]

At the end of the experiment after 24hrs of last administration (day 11), the rats were anaesthetized using chloroform, sacrificed and blood was collected in plain tubes, allowed to stand for 45 minutes before being centrifuged at 4000 rpm for 25 min to obtain serum for analysis. The Serum was used for determination of Aspartate Aminotransferase (AST), Alanine transaminase (ALT), Albumin (ALB), Total Bilirubin (TB) and Total protein (TP).

The liver were immediately excised, washed in ice cold saline, weighted and a portion fixed in 10% phosphate buffered formalin for histopathological examination while the remaining portion were stored at -20oC for determination of oxidative stress

and endogenous enzymes. 10 % tissue homogenate of the stored liver tissues were prepared using phosphate buffer solution at pH 7.34.

The homogenate was centrifuged at 5000 rpm for 15 minutes and a clear supernatant obtained used for determining Superoxide Dismutase (SOD), Malondialdehyde (MDA) and Catalase Activity (CAT)

Ethical Approval

This study was approved by Ethics committee of the Faculty of Basic Medical Sciences, Edo State University Uzairue and the rats were humanely treated in accordance with the guidelines for ethical conduct in the care and use of nonhuman animals in research [12].

Biochemical Parameters

Aspartate transaminase (AST) activity and alanine transaminase (ALT) were determined using the RANDOX Kit (Randox Laboratories Ltd, County Antrim, UK) according to the manufacturer's instructions as described by [13]. Total bilirubin was determined using the RANDOX Kit (Randox Laboratories Ltd, County Antrim, UK) according to the manufacturer's instructions by the method of [14]. Total protein was determined using the RANDOX Kit (Randox Laboratories Ltd, County Antrim, UK) according to the manufacturer's instructions as described by [15]. Albumin was determined using the RANDOX Kit (Randox Laboratories Ltd, County Antrim, UK) according to the manufacturer's instructions based on the Bromocresol green (BCG) method as described by [16]. Malondialdehyde (MDA) content was determined by the methods of [17]. Superoxide dismutase (SOD) and catalase (CAT) activities were assayed as described by [18] and [19] respectively.

Histopathological Evaluation

Rats were sacrificed after and liver samples were excised, washed with normal saline (0.9% NaCl).

The isolated livers were fixed in 10% buffered formalin and were further processed for

Statistical analysis

All the data in the treatment groups are presented as mean \pm Standard error of the mean (SEM) and statistical analysis was carried out using statistical package (SPSS) version 20, Windows 10. Mean values of the different treatment groups were compared using one-way analysis of variance (ANOVA), followed by Duncan multiple range post hoc tests. The $P < 0.05$ was considered statistically significant.

Results

Effects of *Ch. odorata* aqueous leaf extract on Biochemical parameters in Methotrexate-induced wistar rats

The impact of *Ch. odorata* on serum ALT and AST is presented in Table 1. Significant ($p < 0.05$) increase in the activities of ALT and AST in group 3 was observed while upon treatment with the extract of *Ch. odorata*, the enzymes' activities were observed to be significantly reduced towards normal levels as seen in group group 4 in Table 1.

The result on synthetic molecules revealed that Methotrexate significantly increased total bilirubin and significantly decreased total protein and albumin. However, at a dose of 200 mg/kg *Ch. odorata*, there was decrease in total bilirubin and increase in total protein and albumin towards the control levels as shown in Table 1.

Table 1. Effects of *Ch. odorata* aqueous leaf extract on Biochemical parameters in Methotrexate-induced wistar rats

| Treatment groups | AST (U/L) | ALT (U/L) | TP (g/dl) | ALB(g/d) | Total Bilirubin (mg/dl) |
|----------------------------------------------------------|--------------------|--------------------|-----------------|-----------------|-------------------------|
| Control | 39.01 \pm 2.30a | 33.66 \pm 3.12a | 9.14 \pm 0.4a | 7.21 \pm 1.3a | 2.06 \pm 0.17a |
| <i>Ch. odorata</i> (200 mg/kg) | 41.09 \pm 2.73a | 37.33 \pm 2.06a | 8.16 \pm 0.4a | 6.58 \pm 0.9a | 1.18 \pm 0.60a |
| Methotrexate (20 mg/kg) | 132.05 \pm 4.13b | 150.00 \pm 5.56b | 2.17 \pm 0.1b | 1.39 \pm 0.2b | 27.61 \pm 5.75b |
| <i>Ch. odorata</i> (200 mg/kg) + Methotrexate (20 mg/kg) | 62.02 \pm 3.51c | 78.33 \pm 4.01c | 5.58 \pm 0.3c | 4.42 \pm 0.3c | 5.86 \pm 1.83c |

Data are presented as Mean \pm SEM, Values with different super scripts down the column differ significantly ($p < 0.05$). AST: Aspartate aminotransaminase; ALT: Alanine aminotransferase; TP: Total Protein; ALB: Albumin.

Intraperitoneal injection of the animals with Methotrexate without treatment with *Ch. odorata* as seen in Table 2 resulted in significant ($p < 0.05$) increase in malondialdehyde (MDA) concentration as compared to the other groups. However extract of

Ch. odorata administration mitigated the increased MDA concentration towards the control group as shown in Table 2. Also from our results, there was a significant decline in the Superoxide Dismutase (SOD), and Catalase (CAT) concentrations due to Methotrexate administration as compared to the control group. However, treatment with extract of *Ch. odorata* significantly increased hepatic SOD and CAT activities as compared to the untreated Methotrexate-induced group as shown in Table 2.

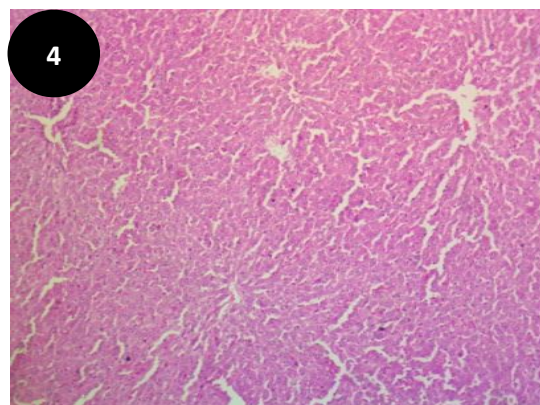
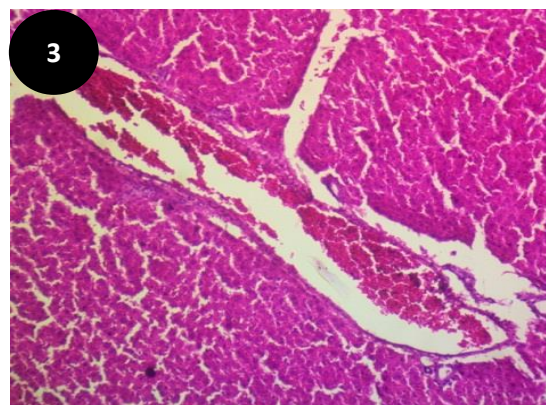
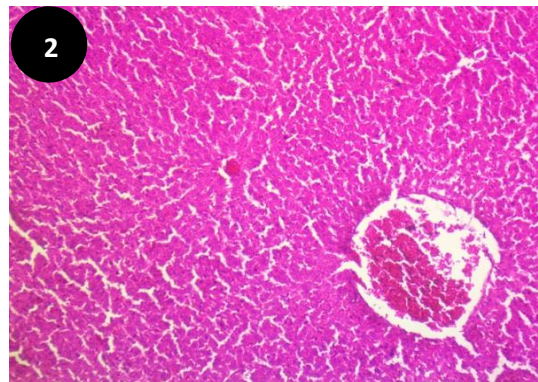
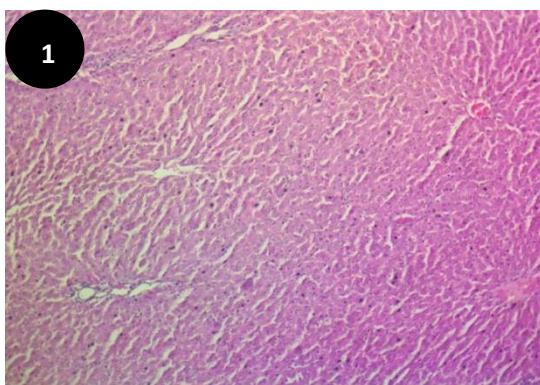
Table 2. Effects of *Ch. odorata* aqueous leaf extract on lipid peroxidation and antioxidant enzymes of Liver in Methotrexate-induced wistar rats

| Treatment groups | Liver SOD (U/mg protein) | Liver CAT (U/mg protein) | Liver MDA (μ mol/mg protein) |
|------------------|-------------------------------|------------------------------|-----------------------------------|
| Control | 85.14 \pm 5.12 ^a | 3.45 \pm 0.19 ^a | 3.18 \pm 0.65 ^a |

| | | | |
|-------------------------------------------------------------|-------------------------|------------------------|-------------------------|
| <i>Ch. odorata</i> (200 mg/kg) | 90.53±5.16 ^a | 2.95±0.22 ^a | 4.61±0.43 ^a |
| Methotrexate (20 mg/kg) | 14.19±4.46 ^b | 0.54±0.23 ^b | 20.38±2.20 ^b |
| <i>Ch. odorata</i> (200 mg/kg) + Methotrexate (20 mg/kg) | 41.46±4.81 ^c | 1.26±0.34 ^c | 11.13±2.16 ^c |

Data are presented as Mean ± SEM, Values with different super scripts down the column differ significantly ($p < 0.05$). SOD: Superoxide Dismutase; CAT: Catalase; MDA: Malondialdehyde

The result of histopathology examination shows liver of the normal group and the group that received 200 mg/kg *Ch. odorata* with normal appearance of central vein, hepatocytes with well-preserved cytoplasm and portal triad structures (Figs 1 and 4). In untreated Methotrexate group, liver sections as seen in Figs 2 and 3 showed focal necrosis, fatty changes, widened sinusoidal spaces, shrunk apoptotic cells, dilation and congestion of central vein and portal vein; and inflammatory cells infiltration. The liver section of rats that received *Ch. odorata* and Methotrexate (Fig. 5) showed a great degree of reduction in lesion with seen improvement and reduction of hepatocytes degeneration and sinusoidal dilatation as well as reduction of inflammatory cell infiltration.



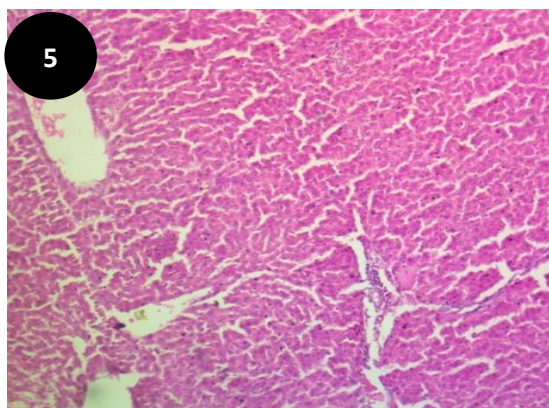


Fig. 1. Photomicrograph of liver of Control rats that received normal saline showing normal liver architecture. **Figs. 2 and 3:** Photomicrograph showing shrunk apoptotic cells, focal necrosis, fatty change in hepatocytes and sinusoidal lining cells, dilation and congestion of central vein (cv) and portal vein; and inflammatory cells infiltration. **Fig. 4:** Photomicrograph of liver of rats that received only *Ch. odorata* (200mg/kg) for ten consecutive days showing normal liver architecture. **Fig. 5:** Photomicrograph liver of rats given *Ch. odorata* for ten consecutive days and single dose of 20mg/kg Methotrexate showing reduction in the histopathological lesions.

Discussion

Studies have continued to show that bioactive compounds from medicinal plants including *Ch. odorata* are safe and an effective treatment option for hepatic ailments [20]. From several studies, antioxidants and anti-inflammatory agents of medicinal plants are helpful and beneficial in controlling the progression and development of liver injury [21, 22]. Plants such as *Chr. odorata* have been proven to have rich source of bioactive agents such as flavonoids; minerals such as calcium, magnesium, zinc etc [9]. The effect of *Ch. odorata* aqueous leaf extract on Methotrexate induced liver damage was investigated in this study.

Increase in Malondialdehyde (MDA) level is an indication of enhanced lipid peroxidation, a peculiar oxidative stress biomarker [23]. In this study, the high level of MDA seen in the untreated Methotrexate-induced group can be attributed to inadequate antioxidant defense and an

overproduction of Reactive oxygen species (ROS). The high level of MDA in untreated Methotrexate-induced group is an indication of formation of high levels of free radicals that could not be tolerated by the cellular antioxidant defense system. The high level of MDA seen in untreated Methotrexate-induced group in this study is similar to previous toxicity studies of [24, 25, 26, 27, 28]. However, administration of *Ch. odorata* to Methotrexate treated rats greatly reversed the increased MDA contents towards the control level, an indication that *Ch. odorata* help in scavenging and quenching free radicals, thus offer protection of membrane lipids from oxidative damage and oxidative stress.

It is well known that endogenous antioxidative enzymes such as superoxide dismutase (SOD) and catalase (CAT) offers protection to the liver against oxidative damage [29] because they convert reactive oxygen species (ROS) into stable molecules such as water and O₂ [30]. As seen this study, untreated Methotrexate-induced group had a significant decline in SOD and CAT compared to other groups. The decrease in the activities of SOD and CAT may be due to their inhibition and/or damage by Methotrexate or due to their consumption and/or excessive activity against free radicals and oxidative stress during the breakdown of high level H₂O₂ and other ROS, which forms inside the hepatic cells during methotrexate metabolism. On the other hand, treatment of the rats with *Ch. odorata* and Methotrexate administration significantly increased the activities of hepatic SOD and CAT activities, an indication that *Ch. odorata* has the potential to protect liver damage caused by methotrexate-induced oxidative stress through enhancing activities of antioxidant enzymes.

Serum ALT and AST levels are the preferred indicators for hepatic function evaluation. In this study, the high level of AST and ALT seen in untreated Methotrexate-induced group is an indication of hepatocellular damage and plasma membrane rupture which resulted in the release of ALT and AST, which are intracellular enzymes into

the systemic circulation. Due to the Methotrexate-induced free radical-mediated destruction and increased permeability of the cellular membrane structure, high levels of ALT and AST enzymes move into the bloodstream. However, the decrease seen in ALT and AST following *Ch. odorata* administration to rats given Methotrexate demonstrates a potential ability of *Ch. odorata* to abrogate liver damage by a mechanism involving membrane integrity restoration via its antioxidant property. The increase in AST and ALT following Methotrexate administration and the attenuation by *Ch. odorata* is in agreement with previous related studies of [24, 31, 32, 25, 26, 27, 28].

Protein synthesis changes are one of the most common responses to cellular damage, thus making measuring the amount of protein to indicate amount of cell damage [33]. Elevated serum total bilirubin levels as seen in this study may be caused by release of unconjugated or conjugated bilirubin from injured hepatocytes [34]. The liver is the exclusive site of synthesis of Albumin and serum Albumin serves as a true test of hepatic synthetic function [34], thus the great decrease seen in albumin in this study following Methotrexate injection shows loss of liver synthetic function and possible compromise in liver synthetic capacity. Given that most of the proteins are synthesized in the liver, total protein and albumin reduction as seen in this study following Methotrexate injection in blood may be related to liver impairment similar to previous works of [24, 26, 35]. The shown significant elevation of serum AST, ALT, and total bilirubin levels as well as decrease in total protein and albumin levels in untreated Methotrexate-induced group are indicators of hepatocyte dysfunction, hepatic structural damage, cellular leakage and loss of functional integrity of the liver cell membrane. However, results from this study showed that *Ch. odorata* aqueous leaf extract decreased total bilirubin, AST, ALT and significantly raised serum

total protein and albumin in Methotrexate-administered rats, indicating *Ch. odorata* restorative potential of damaged liver cells. Bioactive agents present in *Ch. odorata* leaf may have helped scavenge free radicals, trap ROS and peroxidation products and protect enzymes and liver synthetic molecules.

Histopathological investigations giving credence to increase in liver function enzymes in blood, elevated MDA and decreased antioxidant enzymes, thus enhancing oxidative stress showed livers of rats given Methotrexate exhibiting focal necrosis, shrunk apoptotic cells, inflammatory cell infiltration as well as dilation and central vein congestion similar to previous related studies of [36, 37]. However, worthy of protection, *Ch. odorata* reduced the pathological lesions caused by Methotrexate with improvement and reduction of hepatocytes degeneration and sinusoidal dilatation as well as reduction of inflammatory cell infiltration.

Conclusion

Administration of Methotrexate at a single dose of 20mg/kg led to hepatotoxicity while administration of *Ch. odorata* leaf offered protection to the liver tissue from damage possibly due to its active bioactive agents including flavonoids, which scavenges free radicals, enhance the antioxidant status and protect against oxidative damage and oxidative stress.

Conflicts of Interest

The authors hereby declare no conflicts of interest.

Authors` Contribution

All authors contributed in the experiments, analysis and preparation of this manuscript.

Funding/Support

Not Applicable

References

1. Friedman PF. GI/Liver Secrets: with student consult Access. Saint Louis: C.V. Mosby. 2006
2. Bayram M, Ozogul C, Dursun A, Ercan ZS, Isik, I, Dilekoz E. Ligth and electron microscope examination of the effects of methotrexate on the endosalpinx. European J Obstet & Gyneco Repro Bio 2005; 120: 96–103. doi: 10.1016/j.ejogrb.2004.08.014.
3. Sener G, Demiralp EE, Cetiner, M, Ercan FS, irvanc S, Gedik N, Yegen, BC. L-carnitine ameliorates methotrexate-induced oxidative organ injury and inhibits leukocyte death. Cell Biol Toxicol 2006; 22: 47–60. doi: 10.1007/s10565-006-0025-0.
4. Uraz S, Tahan V, Aygun C, Eren F, Unluguzel G, Yuksel M, Senturk O, Avsar E, Haklar G, Celikel C, Hulagu S, Tozun N. Role of ursodeoxycholic acid in prevention of methotrexate-induced liver toxicity. Dig Dis Sci 2008; 53, 1071–7. https://doi.org/10.1007/s10620-007-9949-3
5. Tanaka H, Sato M, Fujiwara S. Antibacterial Activity of Isoflavonoids Isolated from *Erythrina variegata* Against Methicillin-resistant *Staphylococcus aureus*. Letters in Appl Micro 2002; 35: 494 – 498. doi: 10.1046/j.1472-765x.2002.01222.x.
6. Ngozi N, Theresa O. Personal communication on the relevance and indigenous use of medicinal plants, 2014.
7. Odugbemi, T. Outlines and pictures of medicinal plants from Nigeria. University of Lagos Press, Lagos, Nigeria, 2006; Pp. 1-283.
8. Akinmoladun AC, Akinloye O. Effect of *Chromolaena odorata* on hypercholesterolemia related metabolic imbalances. Proc. Akure- Humboldt Kellog/3rd SAAT Annual Conference, FUTA, Nigeria, 2007; pp 287-290.
9. Usunobun U, Ewere, GE. Phytochemical analysis, Mineral Composition and in vitro antioxidant activities of *Chromolaena odorata* leaves. ARC J Pharma Sci 2016; 2: 6-10. DOI: <http://dx.doi.org/10.20431/2455-1538.0202003>
10. Aladaileh SH, Omnia EH, Mohammad, HA, Saghir SAM, Bin-Jumah M, Manal AA, Mousa OG, Almainan AA, Mahmoud AM. Formononetin Upregulates Nrf2/HO-1 Signaling and Prevents Oxidative Stress, Inflammation, and Kidney Injury in Methotrexate-Induced Rats. Antioxidants 2019; 8: 430. doi:10.3390/antiox8100430
11. Ijioma S, Okafor A, Ndukuba P, Nwankwo A, Akomas S. Hypoglycemic, hematologic and lipid profile effects of *Chromolaena odorata* ethanol leaf extract in alloxan induced diabetic rats. Annals of Biol Sci 2014; 2: 27–32.
12. APA. Guidelines for Ethical Conduct in the Care and Use of Non-Human Animals in Research. American Psychological Association (APA), Washington DC, USA. Retrieved June 13, 2015 from <https://www.apa.org/science/leadership/care/careanimal-guidelines.pdf>, 2012
13. Reitman S, Frankel S. A colorimetric method for the determination of serum glutamic oxalacetic and glutamic pyruvic transaminases. Am J Clin Pathol 1957; 28: 56–63. <https://doi.org/10.1093/ajcp/28.1.56>
14. Jendrassik L, Grof P. Total and Direct Bilirubin. Biochem 1938; 7297: 81.
15. Tietz NW, Burtis CA, Ashwood ER. Tietz textbook of clinical chemistry. Saunders, 1994.
16. Doumas BT, Watson WA, Biggs HG. Albumin standards and the measurement of serum albumin with bromcresol green. Clin Chim Acts. 1971; 31: 87–96. [https://doi.org/10.1016/0009-8981\(71\)90365-2](https://doi.org/10.1016/0009-8981(71)90365-2).
17. Ohkawa H, Ohishi N, Yogi K. Assay for lipid peroxidation in animal tissues by thiobarbituric acid reaction. Ann Biochem

- 1979; 95: 351–358. doi: [10.1016/0003-2697\(79\)90738-3](https://doi.org/10.1016/0003-2697(79)90738-3)
18. Misra HP, Fridovich I. The role of superoxide anion in the autoxidation of epinephrine and a simple assay for superoxide dismutase. *J Biol Chem* 1972; 247: 3170–3175.
 19. Cohen G, Dembiec D, Marcus J. Measurement of catalase activity in tissues extracts. *Anal Biochem* 1970; 34, 30–38. doi: [10.1016/0003-2697\(70\)90083-7](https://doi.org/10.1016/0003-2697(70)90083-7)
 20. Gregory SH, Wing, EJ. Neutrophil–Kupffer cell interaction in host defenses to systemic infections. *Immunol To* 1998; 19: 507–510. doi: [10.1016/s0167-5699\(98\)01319-x](https://doi.org/10.1016/s0167-5699(98)01319-x)
 21. Lee HJ, Seo HS, Kim GJ, Jeon CY, Park JH, Jang BH, Park SJ, Shin, YC, Ko SG. *Houttuynia cordata* thumb inhibits the production of pro-inflammatory cytokines through inhibition of the NF- κ B signaling pathway in HMC-1 human mast cells. *Mol Med Rep* 2013; 8: 731–736. doi: [10.3892/mmr.2013.1585](https://doi.org/10.3892/mmr.2013.1585)
 22. Abbate GM, Sacerdote P, Amodeo G, Mangano A, Levrini L. Experimentally induced pulpal lesion and substance P expression: effect of ketoprofen A preliminary study. *Int J Dent* 2016; 1–5. <https://doi.org/10.1155/2016/6820781>
 23. Ito F, Sono Y, Ito T. Measurement and clinical significance of lipid peroxidation as a biomarker of oxidative stress: oxidative stress in diabetes, atherosclerosis, and chronic inflammation, *Antioxidants*. 2019; 8: 72. <https://doi.org/10.3390/antiox8030072>
 24. Usunobun U, Ugbeni CO, Agu KC. Protective effect of *Celosia argentea* aqueous leaf extract on liver function in Carbon-tetrachloride (CCl₄)-induced hepatotoxicity. *Malaysian J Biochem Mol Bio* 2019; 22; 93 – 96.
 25. Hany E, Abdulmohsen IA, Manal A, Mahmoud K, Omar ME, Azza S, Ashraf MA. Naringin alleviates methotrexate-induced liver injury in male albino rats and enhances its antitumor efficacy in HepG2 cells. *Bioscience Reports* 2020; 40, BSR20193686. <https://doi.org/10.1042/BSR20193686>
 26. Moghadam, AR, Tutunchi, S, Ali Namvaran-Abbas-Abad Yazdi M, Bonyadi F, Daryoush M, Mohammad M, Marzban H, Marek JL, Ghavami S. Pre-administration of turmeric prevents methotrexate-induced liver toxicity and oxidative stress. *BMC Comp Altern Med* 2015; 15: 246. <https://doi.org/10.1186/s12906-015-0773-6>
 27. Adikwu E, Bokolo B, Odeghe OB. Ethanolic Leaf Extract of *Ocimum gratissimum* Abrogates Methotrexate-induced Liver Injury in Albino Rats. *Asian J Bio Sci* 2020; 13: 201–209. <https://doi.org/10.3923/ajbs.2020.201.209>
 28. Abo-Haded HM, Elkablawy MA, Al-johani, Z, Al-ahmadi O, El-Agamy DS. Hepatoprotective effect of *sita gliptin* against methotrexate induced liver toxicity. *PLoS ONE* 12, 2017; e0174295. <https://doi.org/10.1371/journal.pone.0174295>
 29. Kumar M, Sharma VL, Sehgal A, Jain M. Protective effects of green and white tea against benzo(a)pyrene induced oxidative stress and DNA damage in murine model. *Nutri Canc* 2012; 64: 300–306. <https://doi.org/10.1080/01635581.2012.648300>
 30. Uttara B, Singh AV, Zamboni P, Mahajan RT. “Oxidative stress and neurodegenerative diseases: a review of upstream and downstream antioxidant therapeutic options. *Current Neuropharma* 2009; 7: 65–74. doi: [10.2174/157015909787602823](https://doi.org/10.2174/157015909787602823)
 31. Usunobun U, Ekakitie C, 2020. Restoration potential of *Celosia argentea* leaf on Acetaminophen-induced liver toxicity. *An Res Int* 2020; 17: 3674–3681.
 32. Cure, E, Kirbas A, Tumkaya L, Cure MC, Kalkan Y, Yilmaz A, et al. Protective effect of infliximab on methotrexate-induced liver injury in rats: Unexpected drug interaction. *J*

- Can Res Ther 2015; 11: 164-169.
[doi: 10.4103/0973-1482.140809](https://doi.org/10.4103/0973-1482.140809)
33. Osman AGM, Kloas W. Water Quality and Heavy Metal Monitoring in Water, Sediments, and Tissues of the African Catfish *Clarias gariepinus* (Burchell, 1822) from the River Nile, Egypt. J Env Prot 2010; 1: 389-400.
[doi:10.4236/jep.2010.14045](https://doi.org/10.4236/jep.2010.14045)
34. Woreta TA, Alqahtani, SA. Evaluation of abnormal liver tests. Medical Clinics of North America, 2014; 98: 1-16.
<https://doi.org/10.1016/j.mcna.2013.09.005>
35. Usunobun U, Osaigbovo JO, Okolie NP. Hepatoprotective effect of *Rhaphiostylis beninensis* Ethanol root extract on Carbon-tetrachloride (CCl₄)-induced liver attack and damage in Rats. Amer J Biome Sci 2020; 12: 155-163. [https://doi:10.5099/aj200300155](https://doi.org/10.5099/aj200300155)
36. Mojtaba K, Heibatullah K, Mehdi G, Layasadat K, Samira B, Hadi K. Crocin ameliorates methotrexate-induced liver injury via inhibition of oxidative stress and inflammation in rats. Pharmac Reports 2019; 71: 746-752.
<http://dx.doi.org/10.1016/j.pharep.2019.04.004>
37. Hemeida RA, Mohafez OM. Curcumin attenuates methotrexate-induced hepatic oxidative damage in rats. J Egyptian Nat Can Inst. 2008; 20: 141-148. PMID: 20029470